

Available online at www.sciencedirect.com

ScienceDirect

journal homepage: <http://www.elsevier.com/locate/pjnns>

Original research article

Percutaneous balloon kyphoplasty in the treatment of painful vertebral compression fractures: Effect on local kyphosis and one-year outcomes in pain and disability

Krzysztof Zapałowicz^{1,*}, Maciej Radek²

Department of Neurosurgery and Peripheral Nerve Surgery, Medical University of Łódź, University Hospital
WAM-CSW, Łódź, Poland

ARTICLE INFO

Article history:

Received 4 January 2014

Accepted 24 November 2014

Available online 2 December 2014

Keywords:

Kyphoplasty

Pain

Vertebral compression fracture

Kyphosis

Osteoporosis

ABSTRACT

Background and purpose: The aim of the study was to determine the effectiveness of percutaneous balloon kyphoplasty for treatment of compressive vertebral fractures.

Materials and methods: A retrospective analysis was conducted on 24 patients with 58 symptomatic vertebral fractures treated by balloon kyphoplasty. Visual Analogue Pain Scale (VAS) and Oswestry Disability Index (ODI) were used to assess fracture-related pain and patient's disability: preoperatively and within 12-months follow-up. Following the procedures to evaluate the change of vertebral deformity, the angle of local kyphosis was measured.

Results: Preoperative VAS score was 6.54, at discharge it significantly regressed in 95.8% of patients. The overall VAS score at discharge was 1.25 and within 12 months decreased to 0.26. Preoperative ODI score was 50%, at follows-up in all patients it decreased, ranging from 21% to 10%. Reduction of local kyphosis was achieved in 30 (51.7%) vertebrae by average 4.3°. In 9 (37.5%) patients kyphosis of all augmented vertebrae was reduced, in 7 (29.2%) patients procedures reduced kyphosis in part of augmented vertebrae and in 8 patients (33.3%) kyphosis remained unchanged. Asymptomatic complications included cement leak in 10 (17%) vertebrae and intraoperative rupture of 4 (4%) balloons.

Conclusions: Rapid significant pain relief after kyphoplasty followed by long-term pain release and disability reduction obtained in all patients was most probably the result of vertebral augmentation. The correction of local kyphosis had no influence on the outcome.

© 2014 Polish Neurological Society. Published by Elsevier Urban & Partner Sp. z o.o. All rights reserved.

* Corresponding author. Department of Neurosurgery and Peripheral Nerve Surgery, Medical University of Łódź, University Hospital WAM-CSW, Żeromskiego 113, 90-549 Łódź, Poland. Tel.: +48 42 633 30 01; fax: +48 42 633 30 01. E-mail address: krzysztofzapałowicz1@wp.pl (K. Zapałowicz).

¹ Private/permanent address: Urzędnicza 42 app. 66, 91-304 Łódź, Poland. Tel.: +48 601 42 47 17.

² Tel.: +48 42 633 30 01; fax: +48 42 633 30 01.

<http://dx.doi.org/10.1016/j.pjnns.2014.11.005>

0028-3843/© 2014 Polish Neurological Society. Published by Elsevier Urban & Partner Sp. z o.o. All rights reserved.

1. Introduction

There are two minimally invasive percutaneous methods: vertebroplasty and balloon kyphoplasty (BKP), which are widely used for augmentation of vertebrae. The accepted indications for their use include osteoporotic vertebral fractures, spinal myeloma, metastases and haemangiomas [1–5]. In 1987, vertebroplasty was first described as injection of bone cement into vertebral body (VB) causing its mechanical reinforcement and pain relief [1–4]. Vertebroplasty does not inflate the compressed VB; however, in a fraction of fractured vertebrae with mobile bony fragments the reduction in deformity was achieved [2,6]. Percutaneous balloon kyphoplasty (BKP) was introduced in 1998, aiming to correct the kyphotic deformity secondary to vertebral fracture [1,3,4]. In this method two inflatable balloons are inserted under radiofluoroscopic guidance into the VB. Balloons are inflated in order to re-expand the VB and to create a void in its spongy bone, thereafter are deflated and removed. In the next step, the created void is filled with injectable bone cement, most commonly polymethylmethacrylate (PMMA), which consecutively hardens stabilizing the shape of expanded vertebra [1,2,4,5]. After more than a decade of experience, the clinical benefits as well as radiographical results of BKP remain debated [4,6–16]. The objective of this study was to analyse the effects of BKP on correction of local kyphosis, pain relief and patient's quality of life. To the best of authors' knowledge this is the first clinical study of BKP in Polish literature.

2. Materials and methods

This retrospective study included 24 patients (16 females, 8 males) treated with BKP between 2005 and 2008 for painful vertebral compressive fractures (Table 1). The age of participants ranged from 21 to 84 years (mean: 67). The osteoporosis was confirmed in 16 patients based on bone mineral density of the proximal femur, with T-score ranging from –2.52 to –6.80 (mean: –3.74). Osteoporosis was classified as: postmenopausal (9 females), senile (1 male), due to malnutrition (1 female treated for anorexia), linked to coeliac disease and bowel resection (2 males), steroid-induced (2 females) and due to testosterone deficiency after orchiectomy (1 male). Amongst remaining patients, osteopenia was diagnosed in six and myeloma in two. A total of 58 fractured vertebrae (29 thoracic, 29 lumbar) were treated. Fractures were diagnosed by X-ray films, computed tomography (CT) or magnetic resonance image (MRI) and were classified according to Magerl et al. [17] as follows: A1.1 (n = 11), A1.2.1 (n = 41), A1.2.3 (n = 2), A3.1.1 (n = 3) and A3.1.3 (n = 1). Six patients (12 vertebrae) were treated within 3 weeks of symptoms onset, whereas eighteen between 1 and 8 months (mean: 2.5). On examination, all patients presented axial back pain corresponding with the location of fracture and exacerbating by palpation.

The kyphoplasty procedures were performed by the first author, under general anaesthesia, except two realized under sedation combined with local anaesthesia. The patients were placed in prone position, with C-arm installed for biplanar radiofluoroscopic guidance. Kyphon® (Sunnyvale, USA)

Table 1 – Clinical data for patients undergoing balloon kyphoplasty.

Sex/age [years]	T-score/comorbidity	Fractured vertebrae	Kyphosis reduction [$ \Delta\alpha $]
1. F, 74	–3.18	L1	NC
2. F, 38	–5.2; Anorexia	T5, T6, T8, T10, T11, L1	T5: 2°, L1: 5°
3. M, 57	Osteopenia, TS	T7	T7: 3°
4. F, 80	Osteopenia	L2	L2: 7°
5. M, 55	–2.12; myeloma	T4, T6	T4: 2°, T6: 5°
6. M, 74	–3.5; orchiectomy	T12, L1, L2, L4	T12: 2°, L2: 6°, L4: 4°
7. F, 68	Osteopenia	L1, L2	L1: 2°, L2: 5°
8. F, 75	–2.81	L3, L4	L3: 5°
9. M, 41	–3.7; MS	T12, L1	NC
10. F, 77	–3.54	L2, L4	NC
11. M, 60	Myeloma	T11, T12, L1	T12: 3°, L1: 2°
12. M, 69	–5.03; MS	T6	T6: 3°
13. F, 67	–3.45	T11, T12	T11: 3°
14. M, 77	–2.97	L2	NC
15. F, 68	–1.92; osteopenia, hypothyroidism, TS	T9, T12	T9: 2°, T12: 2°
16. M, 78	Osteopenia, RA, ST	T12, L1, L2, L4	NC
17. F, 78	–2.82	L2, L3, L4	NC
18. F, 21	–6.8; SLE, ST	T7–T12	T7: 5°, T8: 10°, T10: 10°, T11: 6°, T12: 3°
19. F, 84	–2.31; osteopenia	T11, L1	NC
20. F, 73	–2.87	L2, L5	NC
21. F, 76	–3.90	L3	L3: 6°
22. F, 80	–3.66	T9, T10, T12, L2, L3	T9: 5°, T10: 6°, L3: 2°
23. F, 65	–2.52	T8	T8: 5°
24. F, 69	–3.83	L1, L4	L1: 5°, L4: 3°
Mean: 67		N = 58	Mean: 4.3°; SD = 2.2°

F, female; M, male; MS, malabsorption syndrome; NC, no correction; RA, rheumatoid arthritis; SD, standard deviation; SLE, systemic lupus erythematosus; ST, steroidotherapy; TS, tobacco smoker.

fabricated the kyphoplasty instruments and bone cement containing PMMA. Through small incisions the working cannulas were inserted into 42 vertebrae with a bipedicular approach and into 16 with unipedicular. Through the working cannula the drill was advanced to create a tunnel for the balloon. According to the diameter of the VB, 20-mm or 15-mm balloons were used, containing 6 ml or 4 ml of liquid, respectively. The balloons were inserted into the cancellous bone of the VB and inflated manually with radiopaque medium. To achieve as much expansion as possible, inflation was carried out until maximum tolerable pressure of 400 psi or maximum balloon volume, thereafter the balloons were deflated and removed. The void was filled with the cement, injected under low pressure. Proportionally to the void dimensions, the injected volume ranged from 3 ml to 10.5 ml per vertebra (mean: 5.5 ml), standard deviation (SD) = 1.96. Mean cement volume calculated for thoracic and lumbar vertebrae was 5.0 ml and 7.0 ml, respectively. The procedure ended in removal of working cannulas and closure of their cutaneous entry points by single sutures. Patients were discharged home the following morning or within 3 days after procedure. In 22 patients the number of vertebrae augmented per session ranged from 1 to 6. Two patients were treated in 2 sessions with intervals lasting 6 weeks and 8 weeks, in these cases the date of last session was established as the beginning of follow-up.

3. Results

The postoperative course was uneventful, repeated fractures were not diagnosed at follow-up. Pain intensity and quality of life were assessed preoperatively, at the day of discharge (pain only) and at follow-up taking place 1 month, 3 months, 6 months and 12 months after kyphoplasty. Five (20.8%) patients were lost from last follow-up for different reasons.

Back pain at the level of fracture was assessed with Visual Analogue Pain Scale (VAS), entailing scores from 0 (no pain at all) to 10 (worst possible pain). At discharge, complete pain relief was noted in 14 (58.3%) patients, significant pain reduction to VAS score = 1–4 in 9 (37.5%), whereas 1 patient declared only 1-point decrease of VAS score. Overall mean VAS pain score decreased from preoperative value 6.54 to 1.25 at discharge and within 12 months its value diminished to 0.26 (Table 2).

The quality of life was evaluated using Oswestry Disability Index (ODI) version 1, consisting on ten sections: pain, personal care, lifting, walking, sitting, standing, sleeping, sex life, social life and travelling [18]. Patients scored each section from 0 (best) to 5 (worst), the sum of scores was turned into percentage of disability. The preoperative mean ODI score was 50%. At 1-month follow-up the disability of all patients diminished, the mean ODI was 21% and at consecutive follow-ups it decreased to 10% (Table 2).

Local kyphosis (LK) was defined as angle between superior and inferior endplates of the fractured vertebra [8,11,16,19]. It was measured on plain radiographs or CT sagittal reformat images obtained preoperatively and after the procedure – before discharge or at first follow-up (Fig. 1). The LK change ($\Delta\alpha$) after kyphoplasty was calculated according to following formula: $\Delta\alpha = \alpha_2 - \alpha_1$, where α_1 and α_2 meant LK angle before and after procedure, respectively; the positive value meant kyphosis, whereas a negative – lordosis. The reduction of LK was achieved in 30 (51.7%) vertebrae with the $|\Delta\alpha|$ ranging from 2° to 10° (mean: 4.3°). In nine (37.5%) patients BKP reduced LK of all augmented vertebrae, in seven (29.2%) reduced LK in fraction of augmented vertebrae, in eight (33.3%) no significant reduction of LK was found (Table 1).

The Mann–Whitney *U* test revealed no difference between postoperative ODI and VAS scores in females and males ($p > 0.05$). The Kruskal–Wallis test revealed no evidence of differences between baseline and post procedural VAS scores in 3 groups of patients: with reduced LK of all augmented vertebrae, reduced LK in fraction of augmented vertebrae and those without reduction of LK ($p > 0.05$).

Complications related to BKP included leak of PMMA in 10 (17%) vertebrae, belonging to 7 (29%) of patients, none of them provoked neurologic symptoms. During procedures, 4 (4%) balloons ruptured, without any damage to patients.

4. Discussion

There is a general consent that BKP corrects vertebral anatomy, reduces pain and improves patient's quality of life with lower incidence of extravertebral cement leaks and clinical complications as compared to vertebroplasty [1–6,9]. However, controversies exist regarding the effectiveness of BKP in reducing the post-fracture kyphosis and assumed superiority of BKP over vertebroplasty or conservative

Table 2 – Evaluation of pain (VAS score) and quality of life (ODI score).

	Baseline	Discharge	1 month	3 months	6 months	12 months
Patients	24	24	24	24	24	19
VAS mean score	6.54	1.25	1.46	0.92	0.50	0.26
VAS score range	2–10	0–8	0–6	0–4	0–2	0–3
SD	2.431	1.984	1.693	1.176	0.722	0.733
ODI mean score	50%	–	21%	16%	12%	10%
ODI score range	8–84%	–	0–50%	0–48%	0–44%	0–32%
SD	21.580	–	17.695	12.956	12.200	10.088

ODI, Oswestry Disability Index.
VAS, Visual Analogue Pain Scale.
SD, standard deviation.

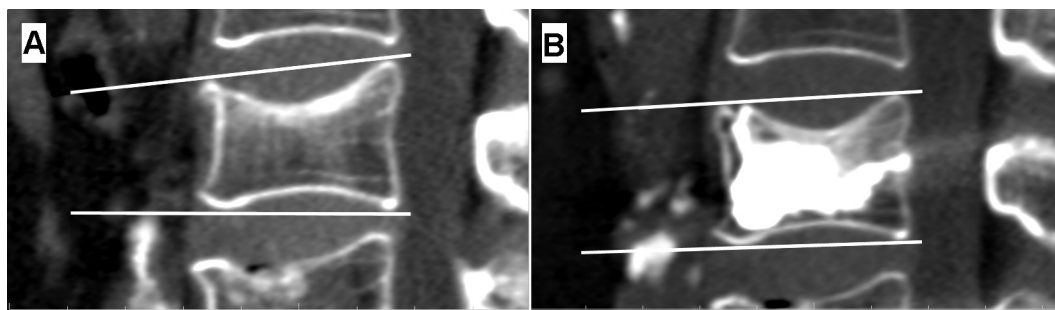


Fig. 1 – Illustration of local kyphosis measurement in the midsagittal plane on reformatted CT scans (Case 8, L3 vertebral body fracture type A1.2.1). The wedge angle between superior and inferior endplates of the fractured vertebra was measured. (A) CT scan obtained before procedure (local kyphosis = 5°). (B) CT scan obtained 2 days after kyphoplasty (local kyphosis = 0°). Local kyphosis reduction $|\Delta\alpha| = 5^\circ$.

treatment [8–10,12,15,16,19,20]. In 2006, Hulme et al. analysed 69 clinical studies and estimated that BKP failed to restore the kyphotic angle or vertebral height in 34% of vertebrae; also concluded that mean kyphotic angle restoration of fractures treated with BKP and of mobile fractures treated with vertebroplasty was similar, equal to 6.6° [3]. This was later confirmed by Hiwatashi et al. [9] and Santiago et al. [20], who pointed out that BKP and vertebroplasty provided the same degree of vertebral height restoration. Regardless of the correction of vertebral geometry, the clinical impact of this radiological result is not known [20]. Lee et al. [11] and Pradhan et al. [19] revealed that reduction of vertebral kyphosis obtained with BKP did not significantly improve the overall spinal alignment. In 2005, Feltes et al. observed alleviation of pain without restoration of VB height [8]. Some authors did not find any association between correction of vertebral deformity and improvement of pain [12,21,22]. In 2007, groups of experts published the position statement on percutaneous vertebral augmentation, concluding that “the performance of BKP instead of vertebroplasty may be due to operator experience or preference” [10]. Above-mentioned opinions confirm lack of evidence-based indications for the use of BKP.

The results presented in this study showed rapid pain relief of 23 (95.8%) patients with a significant decrease of overall mean VAS pain score by 5.29 points at discharge and with further improvement within 12 months. The reduction of disability of all patients came into evidence at a first month follow-up, when the decrease of mean ODI score by 29% was noted. Within following 11 months the mean ODI ranged between 16% and 10%, signifying minimal disability. Above-mentioned results are confirmed in literature [3,6,7,15,16]. However, in our study clinical outcome shows discrepancy with radiological results: reduction of LK was achieved in 51.7% of vertebrae, it succeeded in 66.7% of patients; amongst them only 37.5% had the kyphosis of all fractured vertebrae reduced. This divergence serves as evidence that clinical improvement corresponds with intravertebral cement instillation, whereas it is not proportional to the incidence of deformity correction. The volume of PMMA injected to vertebrae presumably was the main causative factor of pain relief, whereas the reduction of LK might play minor contributing role. The accepted explanation of pain relief after vertebral augmentation is based upon mechanical effect

of cement injected into VB [6,13,23,24]; the contributory role of heat released during exothermic polymerization of PMMA is also taken into account [25]. The correlation between amount of cement injected to VB and clinical results was postulated for both vertebroplasty and BKP [13,23,24]. The amount of cement 13–16% of VB volume is sufficient to restore its compressive strength [23]. Nieuvenhuijse et al. revealed that cement volume equal to 24% of VB volume injected with vertebroplasty technique provided optimal pain relief without increase of complications [24]. Röder et al. estimated for BKP that cement volumes up to 4.5 ml per vertebra resulted in significant pain relief [13]. Retrospective calculations presented in this study revealed that vertebrae were augmented with average cement volume equal to 5.5 ml. It is highly probable, that higher cement volume provided rapid and long-term clinical improvement, however, resulted in increased incidence of extravertebral cement leaks, as compared to literature [3,15]. This study is limited by lack of control group and absence of five patients in the most recent follow-up. In most patients, one-time postoperative imaging (CT or plain X-ray films) served for measurement of LK, repeated radiologic examinations were not performed in order to avoid excessive irradiation of patients and given the lack or recurrent pain at the treated levels.

5. Conclusions

Rapid significant pain relief after kyphoplasty followed by long-term pain release and disability reduction in all patients was most probably the result of vertebral augmentation. The correction of local kyphosis had no influence on the outcome.

Conflict of interest

None declared.

Financial support

None declared.

Ethics

The work described in this article has been carried out in accordance with The Code of Ethics of the World Medical Association (Declaration of Helsinki) for experiments involving humans; EU Directive 2010/63/EU for animal experiments; Uniform Requirements for manuscripts submitted to Biomedical journals.

REFERENCES

- [1] Garfin SR, Hansen AY, Reiley MA. New technologies in spine. Kyphoplasty and vertebroplasty for the treatment of painful osteoporotic compression fractures. *Spine* 2001;26(14):1511–5.
- [2] Mathis JM, Deramond H, Belkoff SM, editors. Percutaneous vertebroplasty and kyphoplasty. 2nd ed. New York: Springer Science+Business Media; 2006 [chapter 8].
- [3] Hulme PA, Krebs J, Ferguson SJ. Vertebroplasty and kyphoplasty: a systematic review of 69 clinical studies. *Spine* 2006;31(17):1983–2001.
- [4] Vaccaro AR, Fehlings MG, Dvorak MF, editors. Spine and spinal cord trauma. Evidence-base management. 1st ed. New York: Thieme Medical Publishers; 2011 [chapter 42].
- [5] Vaccaro AR, Baron EM, editors. Spine surgery. Operative techniques. 2nd ed. Philadelphia: Elsevier Saunders; 2012 [chapter 36].
- [6] Voggenreiter G. Balloon kyphoplasty is effective in deformity correction of osteoporotic vertebral compression fractures. *Spine* 2005;30(24):2806–12.
- [7] Bergmann M, Oberkircher L, Bliemel C. Early clinical outcome and complications related to balloon kyphoplasty. *Orthop Rev* 2012;4(2):e25. <http://dx.doi.org/10.4081/or.2012.e25>.
- [8] Feltes C, Fountas KN, Machinis T. Immediate and early postoperative pain relief after kyphoplasty without significant restoration of vertebral body height in acute osteoporotic vertebral fractures. *Neurosurg Focus* 2005;18(3):E5.
- [9] Hiwatashi A, Westesson P-LA, Yoshiura T. Kyphoplasty and vertebroplasty produce the same degree of height restoration. *AJNR Am J Neuroradiol* 2009;30(4):669–73.
- [10] Jensen ME, McGraw JK, Cardella JF. Position statement on percutaneous vertebral augmentation: a consensus statement developed by the American Society of Interventional and Therapeutic Neuroradiology, Society of Interventional Radiology. American Association of Neurological Surgeons/Congress of Neurological Surgeons, and American Society of Spine Radiology. *J Vasc Interv Radiol* 2007;18(3):325–30.
- [11] Lee TO, Jo DJ, Kim SM. Outcome and efficacy of height gain and sagittal alignment after kyphoplasty of osteoporotic vertebral compression fractures. *J Korean Neurosurg Soc* 2007;42(4):271–5.
- [12] Papanastassiou ID, Phillips FM, Van Meirhaeghe J. Comparing effects of kyphoplasty, vertebroplasty, and non-surgical management in a systematic review of randomized and non-randomized controlled studies. *Eur Spine J* 2012;21(9):1826–43.
- [13] Röder C, Boszczyk B, Perler G. Cement volume is the most important modifiable predictor for pain relief in BKP: results from SWISSpine, a nationwide registry. *Eur Spine J* 2013;22(10):2241–8.
- [14] Schroeder JE, Ecker E, Skelly AC. Cement augmentation in spinal tumors: a systemic review comparing vertebroplasty and kyphoplasty. *Evid Based Spine Care J* 2011;2(4):35–43.
- [15] Taylor RS, Fritzell P, Taylor RJ. Balloon kyphoplasty in the management of vertebral compression fractures: an updated systematic review and meta-analysis. *Eur Spine J* 2007;16(8):1085–100.
- [16] Van Meirhaeghe J, Bastian L, Boonen S. A randomized trial of balloon kyphoplasty and nonsurgical management for treating acute vertebral compression fractures. *Spine* 2013;38(12):971–83.
- [17] Magerl F, Aebi M, Gertzbein SD. A comprehensive classification of thoracic and lumbar injuries. *Eur Spine J* 1994;3(4):184–201.
- [18] Fairbank JCT, Pynsent PB. The Oswestry Disability Index. *Spine* 2000;25(22):2940–53.
- [19] Pradhan BP, Bae HW, Kropf MA. Kyphoplasty reduction of osteoporotic vertebral compression fractures: correction of local kyphosis versus overall sagittal alignment. *Spine* 2006;31(4):435–41.
- [20] Santiago FR, Abela AP, Álvarez LG. Pain and functional outcome after vertebroplasty and kyphoplasty. *Eur J Radiol* 2010;75(2):e108–13.
- [21] Kasperk C, Hillmeyer J, Nöldge G. Treatment of painful vertebral fractures by kyphoplasty in patients with primary osteoporosis: a prospective nonrandomized controlled study. *J Bone Miner Res* 2005;20(4):604–12.
- [22] Stoffel M, Wolf I, Ringel F. Treatment of painful osteoporotic compression and burst fractures using kyphoplasty: a prospective observational design. *J Neurosurg Spine* 2007;6(4):313–9.
- [23] Boszczyk B. Volume matters: a review of procedural details of two randomised controlled vertebroplasty trials of 2009. *Eur Spine J* 2010;19(11):1837–40.
- [24] Nieuwenhuijse MJ, Bollen L, van Erkel AR. Optimal intravertebral cement volume in percutaneous vertebroplasty for painful osteoporotic vertebral compression fractures. *Spine* 2012;37(20):1747–55.
- [25] Belkoff SM, Molloy S. Temperature measurement during polymerization of polymethylmethacrylate cement used for vertebroplasty. *Spine* 2003;28(14):1555–9.