

Application of intraoperative computed tomography in a neurosurgical operating theatre

Zastosowanie śródoperacyjnej tomografii komputerowej na neurochirurgicznej sali operacyjnej

Piotr Gasiński, Piotr Zieliński, Marek Harat, Jacek Furtak, Józefina Rakowska, Dariusz Paczkowski

Klinika Neurochirurgii, 10 Wojskowy Szpital Kliniczny w Bydgoszczy

Neurologia i Neurochirurgia Polska 2012; 46, 6: 536-541

DOI: 10.5114/ninp.2012.32176

Abstract

Background and purpose: The authors describe their own experience in use of intraoperative computed tomography (CT) with the Siemens SOMATOM Sensation in 125 cases.

Material and methods: Intraoperative CT of the head was most often used in functional neurosurgery for stereotactic planning in 32 cases and for control of deep brain stimulation electrode placement in 18 cases. In spine surgery, CT was used most often in spine stabilization to control the placement of implants.

Results: The implant had to be corrected in 7 cases (17% of 41 procedures), and in those cases the need for a revision procedure was therefore avoided. Intraoperative CT was also widely used in emergency procedures and perioperative complications in 13 cases, for control of intraventricular catheter or Rickham port placement in 8 cases, for evaluation of extent of tumour resection in 4 cases, for verification of electrode placement during percutaneous trigeminal rhizotomy in 3 cases, for evaluation of decompression after cervical corpectomy and thoracic discopathy in 3 cases, in complex fractures in 2 cases and as angio-CT after aneurysm clipping in 1 case. There was no significant prolongation of procedure duration. Intraoperative CT proved to be safe for a patient and for personnel. During the three-year evaluation period, the increasing use and indications for intraoperative CT were noted. Integration of CT with navigation is planned in the near future.

Streszczenie

Wstęp i cel pracy: Autorzy przedstawiają doświadczenia własne w zastosowaniu śródoperacyjnej tomografii komputerowej (TK) przy użyciu aparatu Siemens SOMATOM Sensation u 125 chorych.

Materiał i metody: W 10 Wojskowym Szpitalu Klinicznym w Bydgoszczy dwie sale neurochirurgiczne wyposażono w aparat TK umożliwiający wykonywanie badań śródoperacyjnych. Śródoperacyjną TK głowy wykonywano najczęściej w operacjach z zakresu neurochirurgii czynnościowej (do planowania zabiegu stereotaktycznego u 32 chorych i kontroli położenia elektrod po zabiegach głębokiej stymulacji mózgu u 18 chorych). W trakcie operacji kręgosłupa badanie przeprowadzano najczęściej podczas stabilizacji kręgosłupa, aby ocenić położenie implantów.

Wyniki: W 7 na 41 przypadków (17%) poprawiano położenie implantu – śródoperacyjna TK uchroniła tych chorych przed ponowną operacją. Śródoperacyjna TK znalazła również zastosowanie w stanach ostrych i pogorszeniu stanu chorego po zabiegu (13), w ocenie położenia drenu zastawki, drenażu, zbiornika Rickhama (8), w ocenie doszczętności usunięcia guza (4), w ocenie położenia elektrody do elektrokoagulacji zwoju Gassera (3), w ocenie odbarczenia po korpektomii szyjnej i operacji krążka międzykręgowego w odcinku piersiowym (3), w skomplikowanych złamaniach (2) oraz jako angio-TK po klipsowaniu tętniaka (1). Metoda ta nie przedłuża istotnie czasu trwania operacji. Jest bezpieczna dla chorego i dla per-

Correspondence address: Piotr Gasiński, Klinika Neurochirurgii, 10 Wojskowy Szpital Kliniczny, ul. Powstańców Warszawy 5, 85-681 Bydgoszcz, Polska, phone: 503 142 773, e-mail: pgasinski@wp.pl

Received: 23.01.2012; accepted: 29.05.2012

Conclusions: Intraoperative CT is a very useful tool in spine surgery as well as in functional neurosurgery and neurooncology.

Key words: neurosurgery, intraoperative computed tomography, surgical navigation, transpedicular stabilization.

sonelu. Z blisko trzyletniej obserwacji wynika, że częstość wykonywania śródoperacyjnej TK rośnie, a wskazania do jej stosowania rozszerzają się. Planuje się zastosowanie TK na bloku operacyjnym jako jednego z elementów zintegrowanego systemu nawigacji w związku z jej modernizacją.

Wnioski: Śródoperacyjna TK jest bardzo przydatnym urządzeniem zarówno w chirurgii kręgosłupa, jak i w operacjach z zakresu neurochirurgii czynnościowej i neuroonkologii.

Słowa kluczowe: neurochirurgia, śródoperacyjna tomografia komputerowa, nawigacja chirurgiczna, stabilizacja przeznaczona.

Introduction

Computed tomography (CT) uses the projections of the object from different directions to create cross-sectional two-dimensional images (2D) and spatial, three-dimensional images (3D). The introduction of the first CT scanner into clinical practice was a kind of revolution, both technologically and diagnostically. The first tomograph, called the EMI scanner, was built in 1968 by Godfrey Hounsfield. The mathematical foundations of this invention were established by the Austrian mathematician Johann Radon. A typical examination lasted about 25 minutes, and the processing of one image took up to seven minutes [1].

Initially, the CT equipment was applied only to static tests, where the result was obtained after a long analysis time. Thanks to technological progress, the digital data can be calculated very fast so that the image can be viewed just after the examination, or even in real time with the Workstream 4D technology. It enables direct assessment of the three-dimensional images in 3D space as well as in time (fourth dimension, 4D). With this ability, it became possible to use CT for imaging of a beating heart, for example, or in the operating room, as a test performed during surgery.

The first intraoperative CT was used by Shalit in 1978 [2]. Despite several reports on the benefits and usefulness of this method, intraoperative CT is not very common. It is mostly used during spinal surgery and functional neurosurgery [3-6]. It is related to large financial expenditures, as well as difficulties in adapting the operating theatre to its application.

Material and methods

The authors present their experience in the use of intraoperative CT studies using a Siemens SOMATOM

Sensation scanner in 125 patients. In the 10th Military Hospital in Bydgoszcz, during the construction of a new integrated operating suite, two operating rooms were designed for neurosurgery with the CT apparatus able to perform intraoperative examination. Siemens SOMATOM Sensation is a 64-row scanner. This scanner uses several unique technologies, ranging from an X-ray tube with the anode directly cooled with StrattonTM oil, and digital detectors performing acquisition of up to 64 layers in one complete rotation around the patient in time of 0.33 s. This scanner has high performance combined with unmatched isotropic image resolution of 0.33 mm achieved in all modes. SOMATOM Sensation is capable of producing more than 170 images in 1 second. To prevent too much exposure to radiation of the patient, the system technology has the CareDose4D modality to reduce the radiation dose up to 68% compared with standard protocols. Examination of the whole body can be done in 20 s.

The scanner in stand-by mode is hidden behind the steel curtain for protection against radiation. If it is necessary to carry out the study, the patient remains motionless, while the gantry moves on the rails over the region of study. Due to this solution, some construction plans were changed. An anaesthetic panel and operating microscope were suspended from the ceiling; equipment for anaesthesia allows ventilation through the long air hoses. At the time of the CT examination, the neurosurgery and anaesthesiology staff was located in a special room, where the station was operating the scanner, and it was possible to control the patient's vital signs as well as to observe him/her through protective glass. In order to avoid distortion, a Kevlar head holder was always used and the surgical table was made of carbon fibre (Fig. 1).

The study involved 125 persons (60 women and 65 men) operated on for intracranial pathology or diseases of the spine during more than two years, from

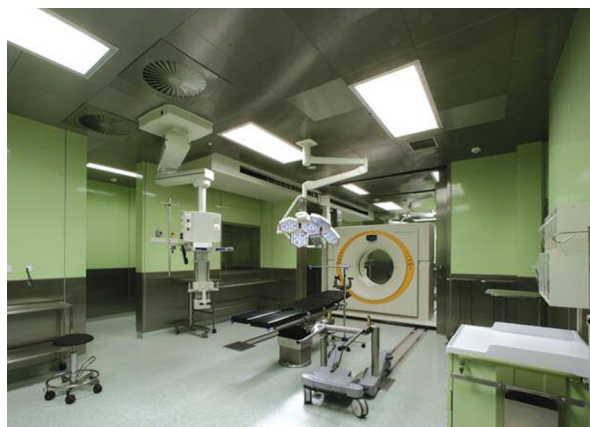

Fig. 1. Operating room with CT - SOMATOM Sensation Open

Table 1. Indications for the reported intraoperative computed tomography studies

Evaluation of spine implants (transpedicular screws, PLIF)	41
Examination for stereotactic surgery planning (stereotactic biopsy, DBS implantation)	32
DBS electrodes verification	18
Worsening in postoperative period and acute indications	13
Ventricular drain and Rickham tank placement verification	8
Tumour resection radicality evaluation	4
Trigeminal lesion electrode verification	3
Verification after cervical and thoracic spinal decompression	3
Complex spine fractures	2
Angio-CT after aneurysm clipping	1

PLIF – posterior lumbar interbody fusion; DBS – deep brain stimulation; CT – computed tomography

November 2008 to January 2011. Patients were subjected to examination under general anaesthesia, except for patients in whom the examination was performed for planning of stereotactic procedures (the examinations were performed under local anaesthesia). After a short period of implementation of intraoperative CT scanning to our everyday clinical practice, duration of one examination was 15 minutes.

Patients qualified for intraoperative CT scanning included those with spine screw placement, stereotactic procedures and tumours requiring extent of removal evaluation (Table 1). During surgery of intracranial pathology, the patient's head was immobilized in a Kevlar

head holder in order to avoid distortion. In the case of spine surgery a carbon operating table was used to avoid artefacts. While performing the CT, the patient was monitored and observed in the room in which the workstation is. Images were obtained immediately after the examination. In some cases, 3D technology was used to obtain the three-dimensional reconstruction.

Results

Among all patients who underwent intraoperative CT, it was necessary to perform two examinations in two patients and three examinations in one case. During the CT examination, there were no technical problems; security and monitoring of a patient were unaffected.

Intraoperative CT was most commonly used in functional neurosurgery for planning stereotactic surgery (CT head with frame scan for fusion with previously acquired magnetic resonance images [MRI]). Such stereotactic functional surgery was performed in 32 patients. Earlier, such examinations were performed in a remote CT laboratory. With the implementation of intraoperative CT, we found a lot of advantages over the earlier solution, including: (1) reduced risk of displacing the frame and the error in the course of several repositionings of the patient, (2) shorter treatment time measured from placement to taking off a stereotactic frame, and (3) significantly improved patient and staff comfort.

CT was also performed during deep brain stimulation (DBS) surgery to determine the location of the electrodes and to exclude complications after implantation of electrodes. Intraoperative CT images of the implanted electrodes were fused with MRI images obtained in preoperative planning. In this way, it excluded any errors that arose during the implementation and mounting of electrodes, which apart from macrostimulation addition, the use of atlases of the basal ganglia and planning based on MRI, further increased the accuracy and effectiveness of DBS. In two out of 18 patients (11%), it was necessary to correct the position of electrodes, which greatly improved the efficiency of stimulation (Fig. 2).

In 13 cases, CT was used due to deterioration of the patient immediately after surgery and in case of urgent indications for neurosurgery in the event of failure of the hospital steady CT. It is worth noting that the intraoperative CT was not and cannot be treated as an additional scanner in the hospital, because each use requires the preservation of the regime in the operating suite, and these indications may be used only in situations of an imminent threat to life.

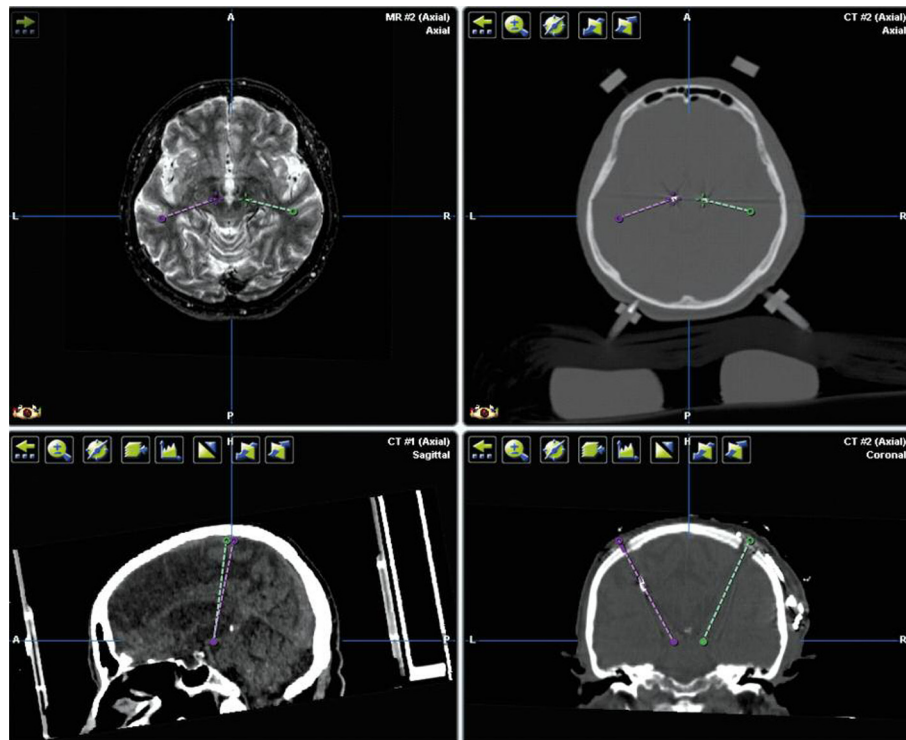


Fig. 2. Fusion between intraoperative CT scan and MRI planning during deep brain stimulation

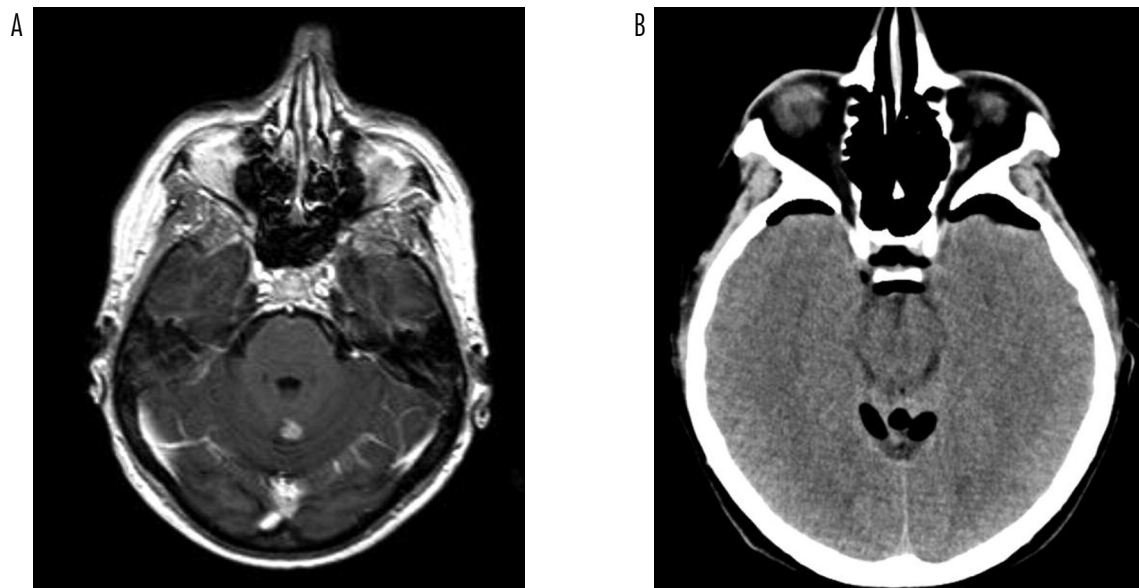

Fig. 3. MRI before surgery and intraoperative CT – assessment of tumour removal

In eight patients, intraoperative CT was used to evaluate the position of the ventriculoperitoneal shunt, ventricular drainage and drain of the Rickham tank. The study was not performed routinely, but only in the

case of surgeon's doubts. In three cases (37%), it was necessary to correct the position of the drain. In our view this is a useful method for intraoperative diagnosis, especially for less experienced surgeons.

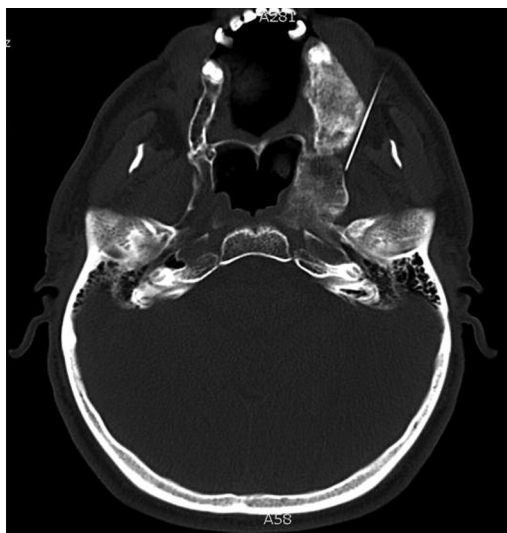

Fig. 4. CT during Gasserian ganglion electrocoagulation in patient with craniofacial fibrous dysplasia

During the tumour surgery, radicality of tumour resection was evaluated in four cases of small tumours, despite the use of intraoperative neuronavigation (Fig. 3).

Three patients underwent the CT to assess the position of the needle in the course of electrocoagulation of the trigeminal ganglion. The literature highlights the significant improvements in the safety and efficacy due to this method, especially in technically difficult cases – one of the patients suffering from fibrous dysplasia of facial bones had significantly altered anatomy of that region (Fig. 4).

In one case, angio-CT was performed. It was during MCA aneurysm clipping surgery to evaluate the flow in all distal branches for confirmation of vessel patency. However, it seems that the procedure for the implementation of angio-CT during the operation is quite time-consuming, and requires the involvement of numerous staff. The result was qualitative, not quantitative, as opposed to intraoperative Doppler examination. Thus, it seems that the intraoperative examination of angio-CT has more disadvantages than advantages in comparison to ultrasound.

The CT during spinal surgery was usually performed during the study stabilization of the spine to assess the position of the implants – screws and posterior lumbar interbody fusion cages (PLIF). In 7 out of 41 cases (17%) the implant was repositioned after the CT examination. If the examination was carried out on the next day after surgery, correction would be needed (not necessarily in all cases). Thus, intraoperative CT has helped to avoid revision surgery in those seven patients.

In three cases CT was used to control for radical decompression after thoracic disc removal and cervical spondylosis. In 2 cases, CT was used during surgery of complex injuries of the spine (Fig. 5).

Discussion

The results show how versatile and diverse the application of CT in the operating room can be. Initially, it was a study which was planned to be used mainly in functional neurosurgery and neuro-oncology. However,

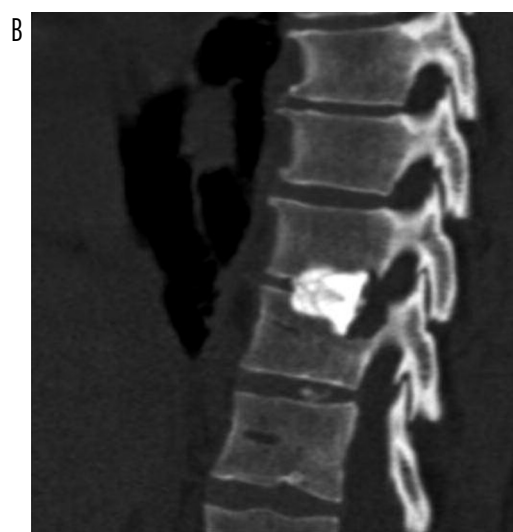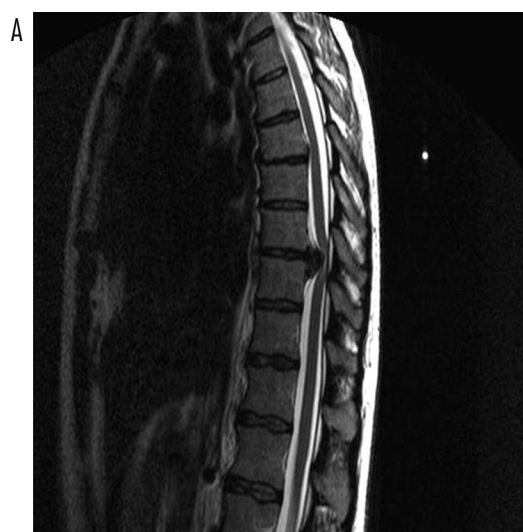


Fig. 5. MRI before and CT after thoracic discectomy by thoracotomy

over time it proved to be very useful also in spine surgery, particularly to assess the positions of implants in the spine. Further indications for CT, including examination during electrocoagulation of the trigeminal ganglion, are systematically implemented.

There are plans to use CT in the operating room as part of the integrated neuronavigation system. After making these changes and fusion of CT with the neuronavigation system, the frequency of examinations will surely increase significantly. It is worth noting that the interest in using this method is increasing steadily. There were 16 intraoperative CT examinations performed in 2008. A more than twofold increase in the number of CT examinations performed in the operating room was noted in 2010 in comparison to 2009 (74 and 35 cases, respectively). The authors also observed a significant shortening of single examination time, which currently takes about 15 minutes.

A very important issue is the safety of patients and staff during the study using X-rays. Staff present in the operating room during surgery are kept in a shielded area, but they have full control over the patient and the CT device, both visually and also using the console with full monitoring. The authors did not observe any complications or technical difficulties in the application of intraoperative imaging studies. It was preceded, however, by numerous consultations at the stage of building a new operating suite including room arrangement and adjustment of anaesthetic apparatus, Kevlar head holder, carbon operating table and ceiling mounted equipment in the operating room.

Conclusions

1. Intraoperative CT is very useful in spinal surgery as well as in functional neurosurgery and brain tumour surgery.
2. Intraoperative CT did not prove its versatility in vascular surgery in the treatment of vascular aneurysm clipping because of the availability of intraoperative Doppler.
3. Intraoperative CT does not significantly prolong the duration of surgery.
4. It is safe for both the patient and operating room personnel.
5. The nearly 3-year observation shows that the use of intraoperative CT is increasing steadily and the indications for its use are expanding. The plan is to use CT in the operating room as part of the integrated navigation system.

6. The introduction of CT in the operating suite for reasons of security technology and procedures is only possible during the construction of a new operating suite or comprehensive modernization.

Disclosure

Authors report no conflict of interest.

References

1. Curry T.S., Dowdey J., Murry R. Christensen's physics of diagnostic radiology. *Lea & Febiger*, Philadelphia 1990.
2. Steudel W.I., Nabhan A., Shariat K. Intraoperative CT in spine surgery. *Acta Neurochir Suppl* 2011; 109: 169-174.
3. Hum B., Feigenbaum F., Cleary K., et al. Intraoperative computed tomography for complex craniocervical operations and spinal tumor resections. *Neurosurgery* 2000; 47: 374-381.
4. Tormenti M.J., Kostov D.B., Gardner P.A., et al. Intraoperative computed tomography image-guided navigation for posterior thoracolumbar spinal instrumentation in spinal deformity surgery. *Neurosurg Focus* 2010; 28: E11.
5. Holly L.T., Foley K.T. Intraoperative spinal navigation. *Spine* 2003; 28: S54-61.
6. Beck M., Mittlmeier T., Gierer P., et al. Benefit and accuracy of intraoperative 3D-imaging after pedicle screw placement: a prospective study in stabilizing thoracolumbar fractures. *Eur Spine J* 2009; 18: 1469-1477.