

A rare case of *Trichosporon* brain abscess, successfully treated with surgical excision and antifungal agents

Rzadki przypadek ropnia mózgu wywołanego przez *Trichosporon*, skutecznie leczony wycięciem chirurgicznym i lekami przeciwgrzybiczymi

Keivan Basiri¹, Mohsen Meidani², Farshid Rezaie², Shabnam Soheilnader¹, Farzad Fatehi³

¹Neurology Department, Isfahan University of Medical Sciences, Iran

²Infectious and Tropical Diseases Department, Isfahan University of Medical Sciences, Iran

³Neurology Department, Shariati Hospital, Tehran University of Medical Sciences, Iran

Neurologia i Neurochirurgia Polska 2012; 46, 1: 92-95

DOI: 10.5114/ninp.2012.27180

Abstract

Trichosporonosis is an acute, sometimes fatal infection with the potential capability of disseminating to multiple deep organs. More than 100 cases of trichosporonosis have been described, particularly in patients with neutropenia or haematological malignancies. In 1970, Watson *et al.* described the first case of brain trichosporonosis; the patient died 4 weeks after admission. Herein, we describe a 34-year-old man with a history of autoimmune hepatitis, hypothyroidism, and alopecia totalis, treated with corticosteroids, who was admitted with left lower limb weakness. Brain MRI revealed a diffuse brain lesion in the right frontoparietal area mimicking a brain abscess. After resection of the lesion, *Trichosporon asahii* was isolated from the abscess. Further treatment with antifungal agents resulted in improvement in clinical status. To the best of our knowledge, this is the second case of *Trichosporon* brain abscess since the first description in 1970 and the first case of successful treatment of *Trichosporon* brain abscess.

Key words: *Trichosporon*, fungal infection, brain abscess, immunocompromised.

Streszczenie

Trichosporonoza to ostre, niekiedy śmiertelne w skutkach zakażenie, w przebiegu którego może dochodzić do wielonarządowego rozsiewu. Dotąd opisano ponad 100 przypadków chorych na trichosporonozę, zwłaszcza pacjentów z neutropenią lub nowotworami krwi. W 1970 r. Watson i wsp. opisali po raz pierwszy przypadek ropnia mózgu spowodowanego przez *Trichosporon*; chory zmarł po 4 tygodniach.

W niniejszej pracy przedstawiono przypadek 34-letniego mężczyzny obciążonego autoimmunologicznym zapaleniem wątroby, niedoczynnością tarczycy i łysieniem całkowitym, leczonego kortykosteroidem, który został przyjęty do szpitala z powodu niedowładu lewej kończyny dolnej. W badaniu mózgu za pomocą rezonansu magnetycznego (RM) stwierdzono rozlane ognisko uszkodzenia okolicy czołowo-ciemieniowej prawej, przypominające ropień mózgu. Po chirurgicznym wycięciu zmiany z ropnia wyizolowano *Trichosporon asahii*. Leczenie przeciwgrzybicze przyniosło poprawę stanu klinicznego. Zgodnie z naszą wiedzą jest to drugi opisany przypadek ropnia mózgu spowodowanego przez *Trichosporon* i pierwszy, w którym leczenie zakończyło się powodzeniem.

Słowa kluczowe: *Trichosporon*, zakażenie grzybicze, ropień mózgu, upośledzenie odporności.

Correspondence address: Farzad Fatehi, M.D., Assistant Professor of Neurology, Tehran University of Medical Sciences, Shariati Hospital, North Kargar Street, Tehran, Iran, phone +98 912 818 6300, e-mail: fatehifa@gmail.com

Received: 8.02.2011; accepted: 22.07.2011

Introduction

Deep-seated trichosporonosis is a type of fatal opportunistic infection that usually develops in immunocompromised hosts. In 1970, the first case of brain infection with *Trichosporon* spp. was reported in a 39-year-old African woman suffering from metastatic adenocarcinoma, who had a *Trichosporon cutaneum* brain abscess [1]. Since then, there have been numerous descriptions of serious trichosporonosis in immunosuppressed patients, particularly in patients with neutropenia or haematological malignancies [2]. Most of the reported cases have been leukopenic and a few have had organ transplantation, HIV infection, burns, chronic ambulatory peritoneal dialysis, or catheter-acquired fungaemia [3]. Herein, we describe the second case of *Trichosporon*

brain abscess since the first report in 1970 by Watson *et al.* [1]. In contrast to the patient described by Watson *et al.*, our case providentially improved clinically after the initiation of treatment.

Case report

A 34-year-old man with a history of autoimmune hepatitis, hypothyroidism, and alopecia totalis was admitted with left lower limb weakness. Four months prior to admission, the diagnosis of autoimmune hepatitis had been made after an episode of icterus. He had been treated for autoimmune hepatitis, alopecia totalis and hypothyroidism with mercaptopurine (75 mg daily), levothyroxine daily and prednisone (50 mg daily). Three weeks before admission he had encountered left lower

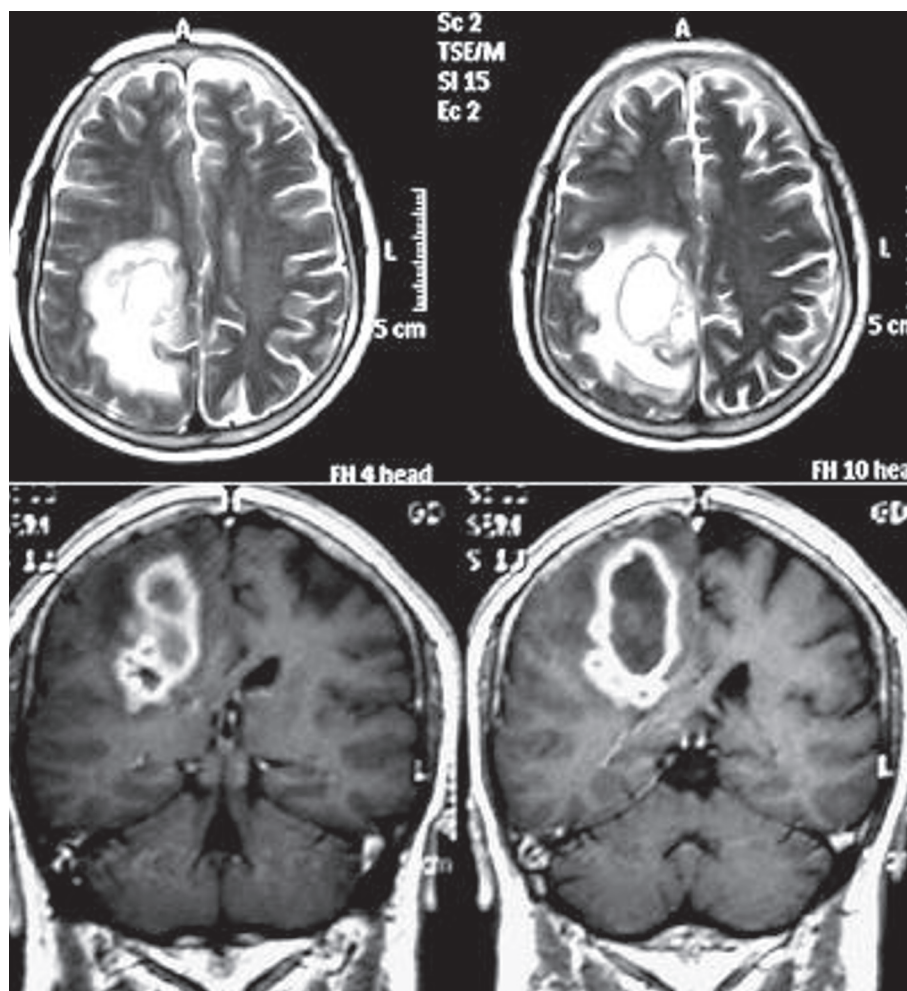


Fig. 1. Axial T2-weighted brain MRI demonstrating a large mass in the frontoparietal area compressing the lateral ventricle. On coronal T1-weighted MRIs with contrast, rim enhancement is seen

limb paraesthesia followed by left-sided foot drop, and during the next few days the weakness had progressed. The physical examination was normal except for left hemiparesis (Medical Research Council grade 4) and Babinski sign on the left side.

Brain MRI revealed a diffuse brain lesion in the right frontoparietal area which was hypointense on T1-weighted images with rim enhancement and hyperintense on T2-weighted images and in FLAIR sequence. The finding was suggestive of brain abscess or glioblastoma multiforme (Fig. 1). One week later, an episode of focal seizure was detected and treatment with carbamazepine was started.

Stereotactic aspiration was performed and the analysis showed pus. Direct smear and culture were negative for bacteria. Empirical therapy with vancomycin

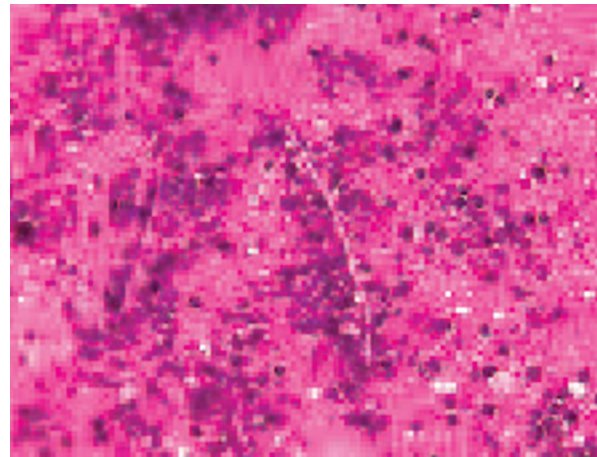


Fig. 2. The microscopic slide shows budding cells germinating to create typical *Trichosporon* hyaline hyphae

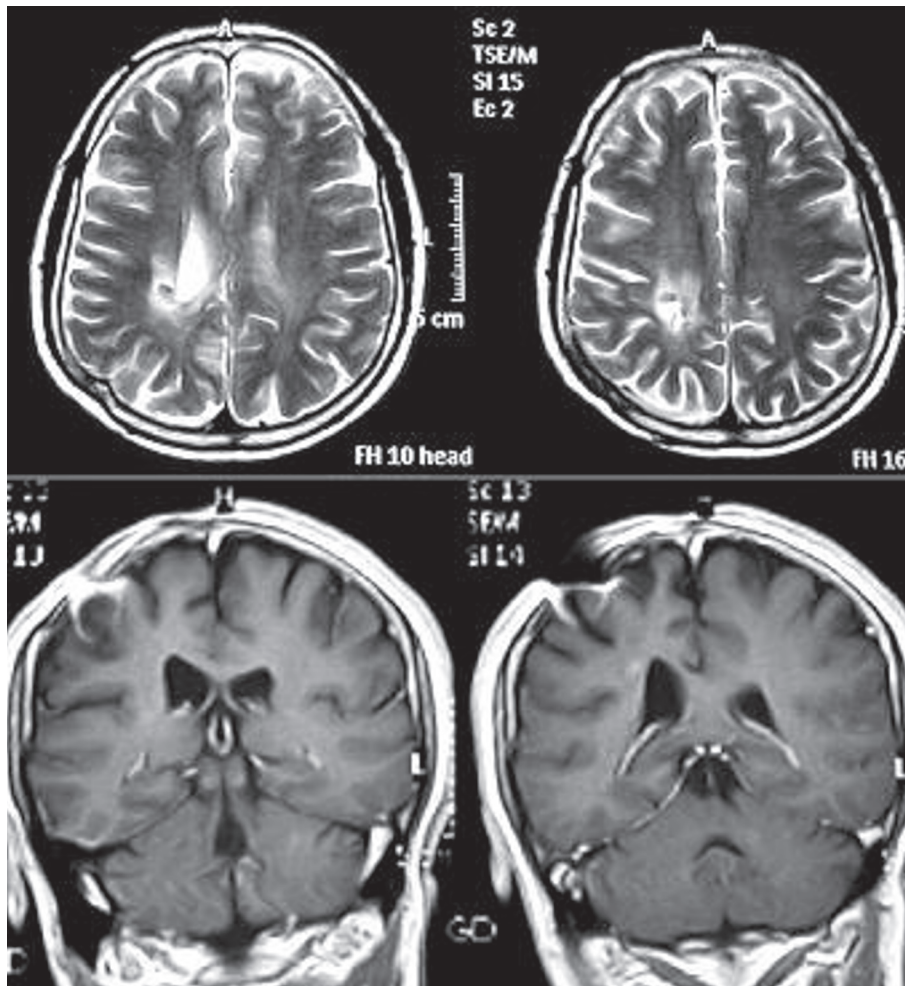


Fig. 3. After one year of treatment, the lesion is completely resolved and only the remnant of resection is seen

(1 g two times daily), meropenem (2 g three times daily) and amphotericin B (started with 30 mg/d and then increased to 70 mg/d) was begun and continued for 3 weeks. Repeated brain MRI with gadolinium demonstrated no change in the size of the lesion. The lesion was resected completely and the pathological examination revealed yeast-like cells and hyphae on Gram stain and *Trichosporon asahii* on culture (Fig. 2). Four weeks after the surgery, the patient was discharged with oral itraconazole (200 mg b.i.d.).

After one year of treatment, he was quite well with mild left lower limb weakness, and brain MRI with gadolinium demonstrated complete resolution of the brain lesion with no evidence of recurrence (Fig. 3).

Discussion

Trichosporon spp. are pathogenic yeasts that inhabit the skin and respiratory flora and are known to cause superficial and deep infections. Superficial infection of hair shafts caused by *Trichosporon* is known as white piedra. White piedra presents as a soft white nodule on hairs in the axillae, scalp, and genital region; by contrast, a deep localized or disseminated fatal infection is seen in immunocompromised patients [4]. This is the first description of successful treatment of brain trichosporonosis since 1970, when the first deep-seated trichosporonosis was reported. More than 100 patients with deep trichosporonosis have been described; approximately 60% have been severely neutropenic, usually with acute leukaemia [5,6]. In retrospective analysis of cases encountered in Japan between 1992 and 2007, the mortality rate was 76% [7]. The outcome of the infection often depends on the extent of the infection and the immune status of the host.

The *Trichosporon* genus is characterized by the production of septate hyphae, yeasts, and pseudohyphae, and yeast-like growth on culture media. A review of the literature reveals that disseminated *Trichosporon* infections are usually associated with two species, *Trichosporon capitatum* and *T. beigelii*. There is a case of fatal invasive pulmonary infection caused by *T. beigelii* in a heart transplant recipient [8]. *T. beigelii* funguria in renal transplant recipients has been reported previously and is thought typically to be benign [9]. Other less common manifestations of trichosporonosis include peritonitis [10], endophthalmitis [11], cholangitis, and hepatitis [4]. In one study, the majority of cases had acute leukaemia (82%), neutropenia (85%), and a history of intensive chemotherapy (91%), and in 91% (30 cases)

trichosporonosis occurred as a breakthrough infection during antifungal therapy [7].

Our patient was cured completely after the resection along with a course of amphotericin B and itraconazole. Many patients with profound neutropenia or endocarditis do not respond to any form of treatment. Currently, optimum therapy is an azole in combination with granulocyte-macrophage colony-stimulating factor (GM-CSF) in a persistently neutropenic patient infected with *Trichosporon* [12].

Disclosure

Authors report no conflict of interest.

References

1. Watson K.C., Kallichurum S. Brain abscess due to trichosporon cutaneum. *J Med Microbiol* 1970; 3: 191-193.
2. Murray-Leisure K.A., Aber R.C., Rowley L.J., et al. Disseminated trichosporon beigelii (cutaneous) infection in an artificial heart recipient. *JAMA* 1986; 256: 2995-2998.
3. Mirza S.H. Disseminated trichosporon beigelii infection causing skin lesions in a renal transplant patient. *J Infect* 1993; 27: 67-70.
4. Fleming R.V., Walsh T.J., Anaissie E.J. Emerging and less common fungal pathogens. *Infect Dis Clin North Am* 2002; 16: 915-933.
5. Itoh T, Hosokawa H., Kohdera U., et al. Disseminated infection with trichosporon asahii. *Mycoses* 1996; 39: 195-199.
6. Hung C.C., Chang S.C., Chen Y.C., et al. Trichosporon beigelii fungemia in patients with acute leukemia: Report of three cases. *J Formos Med Assoc* 1995; 94: 127-131.
7. Suzuki K., Nakase K., Kyo T, et al. Fatal trichosporon fungemia in patients with hematologic malignancies. *Eur J Haematol* 2010; 84: 441-447.
8. Grossi P, Farina C., Fiocchi R., et al. Prevalence and outcome of invasive fungal infections in 1,963 thoracic organ transplant recipients: A multicenter retrospective study. Italian study group of fungal infections in thoracic organ transplant recipients. *Transplantation* 2000; 70: 112-116.
9. Lussier N., Laverdiere M., Delorme J., et al. Trichosporon beigelii funguria in renal transplant recipients. *Clin Infect Dis* 2000; 31: 1299-1301.
10. Kalawat U., Sharma K.K. Trichosporon peritonitis following duodenal perforation. *Saudi J Gastroenterol* 2010; 16: 43-45.
11. Walia H., Tucci V.T., Greene J.N., et al. A case of endogenous trichosporon endophthalmitis treated with micafungin and voriconazole. *J Glob Infect Dis* 2009; 1: 71-74.
12. Sasaki E., Tashiro T., Kuroki M., et al. Effects of macrophage colony-stimulating factor (m-csf) on anti-fungal activity of mononuclear phagocytes against trichosporon asahii. *Clin Exp Immunol* 2000; 119: 293-298.