

Percutaneous closure of the left atrial appendage to prevent ischaemic stroke in patients with atrial fibrillation who require but have contraindications to oral anticoagulation

Przejskórne zamknięcie uszka lewego przedsionka w zapobieganiu udarom niedokrwiennym mózgu u pacjentów z migotaniem przedsionków, którzy mają przeciwwskazania do leczenia doustnymi antykoagulantami

Przemysław Węglarz¹, Tomasz Bochenek¹, Maciej Świąt², Ewa Konarska-Kuszevska¹, Wojciech Wróbel¹, Bogusława Czarnik³, Katarzyna Spisak-Borowska⁴, Grzegorz Opala², Maria Trusz-Głuz¹

¹ Katedra i Klinika Kardiologii, Śląski Uniwersytet Medyczny, SPSK7, Katowice

² Katedra i Klinika Neurologii, Śląski Uniwersytet Medyczny, SP CSK, Katowice

³ Oddział Anestezjologii i Intensywnej Terapii, SPSK7, Katowice

⁴ Oddział Neurologii, Szpital w Oświęcimiu

Neurologia i Neurochirurgia Polska 2012; 46, 1: 87-91

DOI: 10.5114/ninp.2012.27178

Abstract

Atrial fibrillation (AF) is associated with a five-fold increased risk for stroke due to cardioembolic events. Most strokes in patients with AF arise from thrombus formation in the left atrial appendage (LAA). Oral anticoagulation is a standard treatment of AF patients with high risk of stroke. However, the main drawbacks of oral anticoagulation are high risk of major bleeding and imperfect effectiveness dependent on a very narrow therapeutic range. In this article, based on two case reports, we describe a method of percutaneous closure of the LAA. We discuss indications, describe the procedure and mention possible complications. LAA closure seems to be a promising tool to prevent AF-related strokes in a selected group of patients.

Key words: ischaemic stroke, left atrial appendage, antithrombotic therapy.

Streszczenie

Migotanie przedsionków (*atrial fibrillation* – AF) zwiększa pięciokrotnie ryzyko wystąpienia udaru niedokrwiennego mózgu. Większość udarów w grupie osób z AF pochodzi ze skrzeplin, które tworzą się w uszku lewego przedsionka. U pacjentów obciążonych dużym ryzykiem standardem jest stosowanie terapii przeciwkrzepliwej. Leczenie to ma jednak istotne ograniczenia – zwiększa ryzyko poważnych krwawień, a jego skuteczność często jest nie najlepsza z powodu wąskiego zakresu terapeutycznego. W artykule przedstawiono nową metodę, tj. zamknięcie uszka lewego przedsionka techniką przejskórna, i opisano przypadki dwóch leczonych nią pacjentów. Autorzy określili wskazania do zabiegu, jego przebieg, a także możliwe powikłania. Przejskórne zamknięcie uszka lewego przedsionka jest obiecującą metodą zapobiegania udarom mózgu związanym z AF w wyselekcjonowanej grupie chorych.

Słowa kluczowe: udar niedokrwienny, uszko lewego przedsionka, terapia przeciwkrzepliwa.

Correspondence address: dr Tomasz Bochenek, I Katedra i Klinika Kardiologii Śląskiego Uniwersytetu Medycznego, ul. Ziołowa 45/47, 40-635 Katowice, e-mail: tbochun@poczta.onet.pl

Received: 26.02.2011; accepted: 6.07.2011

Introduction

Atrial fibrillation (AF), a chaotic and irregular contraction of the atria, is the most common arrhythmia, affecting 1-2% of the general population and resulting in a significant number of hospitalizations. AF is associated with a five-fold increased risk of stroke due to cardioembolic events [1], being a substantial independent risk factor regardless of whether it is paroxysmal or permanent. AF-related stroke results in significantly increased mortality and morbidity when compared to non-AF causes of stroke [2,3]. Most strokes in patients with AF arise from thrombus formation in the left atrial appendage (LAA) [4]. The pathogenesis is not fully understood but relative stasis, which occurs in the appendage due to its shape and the trabeculations within it, is thought to play a major role [5]. Medical management with oral antico-

agulants is a standard treatment of AF patients with high risk of stroke but its usefulness is limited due to high risk of major bleeding and imperfect effectiveness of anticoagulation dependent on a very narrow therapeutic range demanding frequent monitoring and dose adjustments. Even direct thrombin or Xa factor inhibitors, the most recently developed drugs covering the latter drawback, are still associated with bleeding risk and are therefore contraindicated in high-risk patients.

For easier stratification of high-risk patients, two scales have been developed recently. The CHA₂DS₂-VASc score helps in assessment of stroke risk in non-valvular AF (see Table 1). Those patients with one major risk factor or ≥ 2 'clinically relevant non-major' stroke risk factors (essentially CHA₂DS₂-VASc score of ≥ 2) should be treated with oral anticoagulation. If the patient obtains a maximum score of 9, the adjusted stroke rate (%/year) is 15.2%.

Another useful tool is the HAS BLED scale – a new simple bleeding risk score that allows assessment of bleeding risk in AF patients. A score of ≥ 3 indicates 'high risk' and some caution and regular review of the patient is needed following the initiation of antithrombotic therapy, whether with vitamin K antagonists or aspirin. This scale is presented in Table 2.

Interventional techniques for occlusion of the LAA represent a promising therapeutic option for stroke prevention. These methods may be considered in patients with AF who require anticoagulants, but have high risk of bleeding or in those with very labile INR levels. Several surgical techniques of LAA closure are being employed with varying success rates in stroke risk reduction. When surgical LAA closure is performed, excision of the appendage is the most reliable method. However, there is ongoing concern about discontinuing anticoagulation after surgical treatment due to the high rate of unsuccessful closure [6].

The recent approach to close the LAA in high-risk patients makes use of the transfemoral approach. The first Polish experiences with the use of the Watchman device were published in 2009 [7]. In our report, we describe two patients with AF with high risk of both thromboembolic stroke and bleeding complications who were successfully treated via the percutaneous approach using the new Amplatzer Cardiac Plug device.

Procedure description

The procedure is performed by an interventional cardiologist in the catheterization laboratory with the use

Table 1. CHA₂DS₂-VASc Score. Maximum score is shown in brackets. Score for both patients was calculated

Risk factor	Patient 1	Patient 2
Congestive heart failure/ LV dysfunction (1)	0	1
Hypertension (1)	1	1
Age ≥ 75 years (2)	2	2
Diabetes mellitus (1)	1	1
Stroke/TIA/thromboembolism (2)	2	2
Vascular disease (1)	1	0
Age 65-74 years (1)	0	0
Sex category (i.e. female sex) (1)	1	1
Total score (maximum, 9)	8	8

LV – left ventricle, TIA – transient ischaemic attack

Table 2. HAS BLED scale. Score is shown in brackets. Score for both patients was calculated

Risk factor	Patient 1	Patient 2
Hypertension (1)	1	1
Abnormal renal and liver function (1 point each)	1	0
Stroke (1)	1	0
Bleeding (1)	0	1
Labile INRs (1)	0	0
Elderly (e.g. age > 65 years) (1)	1	1
Drugs or alcohol (1 point each)	0	0
Total score (maximum, 9)	4	3

of fluoroscopy. The presence of an echocardiographer, anaesthesiologist and assisting nurse is essential. Closure of the appendage is performed in general anaesthesia. To begin, the femoral vein is punctured and a sheath is inserted. Next the puncture of the atrial septum is performed under X-ray control and with the assistance of transoesophageal echocardiography (TEE). There is no need to perform this step in the case of patent foramen ovale, or atrial septal defect. After crossing to the left atrium with the catheter, measurements of the appendage with dye injection are made (Fig. 1). Subsequently, the occluder may be transferred to the appendage with echo measurements (Fig. 2). The implant is placed in the orifice of the LAA, preventing the passage of thrombi into the arterial circulation. After checking its stable position, the mechanism is released and catheters are withdrawn. Figure 3 shows a transoesophageal echocardiographic image of the occluder. After the procedure, the patient usually remains supine for four hours to prevent local complications after puncture of the vein and insertion of large sheaths.

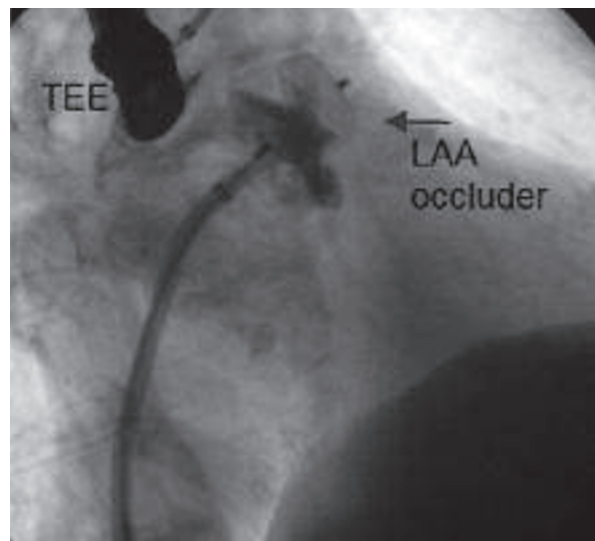
Case reports

Patient 1

An 80-year-old woman presented with hypertension, paroxysmal AF and a history of ischaemic stroke three years ago and upper gastrointestinal bleeding. On the CHA₂DS₂-VASc scale she scored 8 points, which translates to 6.7% yearly risk of ischaemic stroke (Table 1). On the HAS-BLED scale she scored 4 points (Table 2),

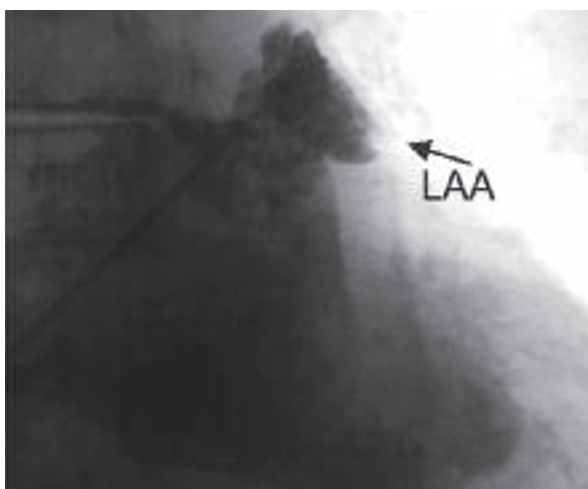
indicating significantly increased risk of bleeding on oral anticoagulation.

We performed obliteration of the LAA with a right femoral vein approach to the venous system. After interatrial septum puncture with TEE guidance and serial measurements, a 20-mm Amplatzer Cardiac Plug device was chosen. After placing the device in the LAA orifice securely, the mechanism was successfully released with no complications. The impermeability was checked with contrast dye under fluoroscopy. The patient was discharged home a few days after the occlusion with advice



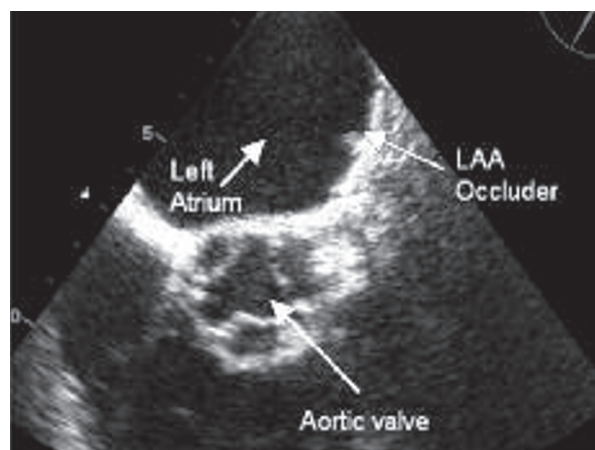
TEE – transoesophageal echocardiography, LAA – left atrial appendage

Fig. 2. Proper placement of occluder in ostium of left atrial appendage. The dye does not cross to the appendage; thus the structure is successfully excluded



LAA – left atrial appendage

Fig. 1. The dye is injected through the catheter to the left atrial appendage



LAA – left atrial appendage

Fig. 3. Transoesophageal echocardiography image of the appendage closed by the occluder. Three-month follow-up study

to continue both aspirin (75 mg daily) and clopidogrel (75 mg daily) for 6 months. Endocarditis prophylaxis was advised. At three-month follow-up the patient remained well with no complications and no further cerebrovascular accidents. TEE revealed good placement of the device within the LAA.

Patient 2

A 78-year-old woman presented with hypertension, diabetes on oral medication, long history of persistent AF and ischaemic stroke with haemorrhagic transformation in September 2010. CHA2DS2-VASc score was 8 points (Table 1) and HAS BLED score was 3 (Table 2). In echocardiography, left ventricle ejection fraction was slightly diminished and concentric heart hypertrophy was present.

The LAA was approached via the right transfemoral route. Due to presence of patent foramen ovale, puncture of the septum was not necessary. Following serial measurements, the Amplatzer Cardiac Plug 26 mm was chosen to obliterate the orifice of the appendage. After performing a stability test, the device was released. There were no complications and the procedure was completed successfully. Four days later patient was discharged home. The patient received aspirin (75 mg daily) and clopidogrel (75 mg daily) only for one month due to relative contraindications to longer, 6-month therapy. Endocarditis prophylaxis was advised. After 3 months, TEE revealed good placement of the device within the LAA and presence of a minor thrombus on the atrial disc of the device, which completely resolved after 4 weeks of therapy with low molecular weight heparin.

Discussion

Oral anticoagulation with vitamin K antagonist (VKA) is the mainstay in stroke prevention in AF patients, but there are several drawbacks. Most important is increased bleeding risk, particularly with INR values > 3.5-4.0. Chronic treatment with oral anticoagulant necessitates regular anticoagulation monitoring and dose adjustment. Multiple interactions with other drugs and food hamper use of VKA. Especially in elderly patients anticoagulation monitoring can be difficult and this age group is prone to higher bleeding risk [8]. In addition, patients on VKA appear to be undertreated for at least one third of time with the INR value remaining below the therapeutic range [9]. Novel long-

expected anticoagulants, direct thrombin or Xa factor antagonist, seem to cover the inconvenience related to regular anticoagulation monitoring with at least the same efficacy as VKA [10], but the bleeding risk is still present. Therefore pursuing a new, non-pharmacological approach is more than justified.

Recently, important data regarding efficacy and safety of percutaneous LAA closure have been released. A randomized controlled trial of 707 patients treated with percutaneous closure of the LAA ($n = 463$) or warfarin ($n = 244$) reported all-cause strokes per 100 patient-years of 2.3 and 3.2, respectively (rate ratio 0.71, credible interval [CrI] 0.35 to 1.64). The efficacy of percutaneous closure of the LAA with this device was non-inferior to that of warfarin therapy. Successful closure was reported in 88% (408/463) of patients [11]. In a case series of 111 patients, stroke was noted in 2 patients at 173- and 215-day follow-up. In both patients, TEE performed at 1 and 6 months revealed a stable device with no thrombogenic layer on the surface. Those findings led to the suggestion that closing the LAA may become an alternative in patients with AF and a contraindication for lifelong anticoagulation treatment [12].

Regarding the safety of LAA closure, few severe cardiac complications have been reported. Tamponade requiring median sternotomy, pericardiocentesis and ligation of the LAA occurred in 1 patient 4 hours after the procedure in the case series of 111 patients cited above. This patient later developed deep vein thrombosis and died 27 days after the procedure, which was attributed to cerebral haemorrhage associated with anticoagulation therapy. Holmes *et al.* reported pericardial effusion successfully treated surgically or with pericardiocentesis in 5% of patients (22/463), and pericardial effusion not requiring drainage in 2% (8/463) of patients. Cardiac arrest 30 minutes after the procedure because of device embolisation was reported in 1 patient, who subsequently died, in a case series of 73 patients [13]. Other potential complications of LAA closure include local bleeding, embolisation, endocarditis, arrhythmia, stroke and transient ischaemic attack (TIA). Nevertheless, all of those remain rarely reported until now. We did not experience complications or major difficulties when performing the closure of LAA in both our patients.

Apparently, percutaneous LAA closure is not an alternative for all patients with AF who require anticoagulation but appears to be a therapeutic option for patients with very high risk of bleeding. One can assume

that it will become more common as the population of patients with AF who require other than pharmacological treatment is rapidly growing.

Disclosure

Authors report no conflict of interest.

References

1. Camm A.J., Kirchhof P., Lip G.Y., et al. Guidelines for the management of atrial fibrillation: the Task Force for the Management of Atrial Fibrillation of the European Society of Cardiology (ESC). *Eur Heart J* 2010; 31: 2369-2429.
2. Wolf P.A., Abbott R.D., Kannel W.B. Atrial fibrillation as an independent risk factor for stroke: the Framingham study. *Stroke* 1991; 22: 983-988.
3. Marini C., De Santis F., Sacco S., et al. Contribution of atrial fibrillation to incidence and outcome of ischemic stroke: results from a population-based study. *Stroke* 2005; 36: 1115-1119.
4. Beinart R., Heist E.K., Newell J.B., et al. Left atrial appendage dimensions predict the risk of stroke/TIA in patients with atrial fibrillation. *J Cardiovasc Electrophysiol* 2011; 22: 10-15.
5. Al-Saady N.M., Obel O.A., Camm A.J. Left atrial appendage: structure, function, and role in thromboembolism. *Heart* 1999; 82: 547-554.
6. Kanderian A.S., Gillinov A.M., Pettersson G.B., et al. Success of surgical left atrial appendage closure: assessment by transesophageal echocardiography. *J Am Coll Cardiol* 2008; 52: 924-929.
7. Kukuła K., Kłopotowski M., Konka M., et al. Zamknięcie uszka lewego przedsionka przy użyciu systemu PLAATO u chorych wysokiego ryzyka z migotaniem przedsionków – obserwacja długoterminowa. *Post Kardiol Interw* 2009; 5: 51-57.
8. Kakar P., Lane D., Lip G.Y.H. Bleeding risk stratification models in deciding on anticoagulation in patients with atrial fibrillation: a useful complement to stroke risk stratification schema. *Chest* 2006; 130: 1296-1299.
9. Connolly S.J., Pogue J., Eikelboom J., et al., ACTIVE W Investigators. Benefit of oral anticoagulant over antiplatelet therapy in atrial fibrillation depends on the quality of international normalized ratio control achieved by centers and countries as measured by time in therapeutic range. *Circulation* 2008; 118: 2029-2037.
10. Schirmer S.H., Baumhäkel M., Neuberger H.R., et al. Novel anticoagulants for stroke prevention in atrial fibrillation. *J Am Coll Cardiol* 2010; 56: 2067-2076.
11. Holmes D.R., Reddy V.Y., Turi Z.G., et al.; PROTECT AF Investigators. Percutaneous closure of the left atrial appendage versus warfarin therapy for prevention of stroke in patients with atrial fibrillation: a randomized non-inferiority trial. *Lancet* 2009; 374: 534-542.
12. Ostermayer S.H., Reisman M., Kramer P.H., et al. Percutaneous left atrial appendage transcatheter occlusion (PLAATO system) to prevent stroke in high-risk patients with non-rheumatic atrial fibrillation: results from the international multi-center feasibility trials. *J Am Coll Cardiol* 2005; 46: 9-14.
13. Park J.W., Leithäuser B., Gerk U., et al. Percutaneous left atrial appendage transcatheter occlusion (PLAATO) for stroke prevention in atrial fibrillation: 2-year outcomes. *J Invasive Cardiol* 2009; 21: 446-450.