

# Radiation therapy in paediatric gliomas: our institutional experience

## Radioterapia w glejakiach u dzieci – doświadczenia własne

Daya Nand Sharma, Shikha Goyal, Sandeep Muzumder, Kunhi Parambath Haresh, Amit Bahl, Parmod Kumar Julka, Goura Kisor Rath

Department of Radiation Oncology, All India Institute of Medical Sciences, New Delhi, India

Neurologia i Neurochirurgia Polska 2010; 44, 1: 28–34

### Abstract

**Background and purpose:** The aim of our retrospective study was to analyze the clinical outcome of paediatric glioma patients treated with radiation therapy (RT) in our institution.

**Material and methods:** We retrieved the case records of all children with gliomas (age < 18 years) who received RT in our department between 2004 and 2007. We analyzed the information regarding patients' demography, clinical details, treatment given, RT details, and survival. The event-free survival (EFS), the period from the date of completion of RT to the date of the event, i.e. death/recurrence, was calculated with respect to age, sex, location of tumour (brainstem vs. non-brainstem), histopathology (low grade vs. high grade), extent of surgical resection, dose and duration of RT, and use of chemotherapy.

**Results:** A total of 70 children with glioma received RT during the above-mentioned period. The 3-year EFS rate for all patients was 44% and the median EFS period was 18 months. The 3-year EFS in patients who underwent surgical decompression and no surgery was 58% and 25%, respectively ( $p < 0.05$ ). Patients with brainstem lesions had statistically significantly lower 3-year EFS to non-brainstem gliomas (28% vs. 56%,  $p < 0.01$ ). Chemotherapy use showed no statistically significant trend towards better survival.

**Conclusions:** RT is an effective modality of treatment in paediatric glioma patients in our setup. Early use of RT in incompletely resected low-grade gliomas is worth revisiting.

### Streszczenie

**Wstęp i cel pracy:** Celem retrospektywnego badania była ocena wyników leczenia dzieci chorych na glejaki, u których prowadzono radioterapię w ośrodku autorów.

**Materiał i metody:** Odszukano dokumentację medyczną wszystkich dzieci (wiek < 18 lat) chorych na glejaki, które w latach 2004–2007 były leczone w ośrodku autorów za pomocą radioterapii. W każdym przypadku przeanalizowano informacje dotyczące danych demograficznych chorych, szczegółowych danych klinicznych, stosowanego leczenia, szczegółów stosowanej radioterapii i czasu przeżycia. Czas przeżycia do wystąpienia zdarzenia (zgonu lub nawrotu choroby) (*event-free survival* – EFS) obliczono w odniesieniu do wieku, płci, umiejscowienia guza (guzy pnia mózgu w porównaniu z guzami poza pniem mózgu), charakterystyki histopatologicznej guza (guzy o małym stopniu złośliwości w porównaniu z guzami o dużym stopniu złośliwości), doszczętności chirurgicznego wycięcia guza, dawki i czasu radioterapii oraz zastosowania chemioterapii.

**Wyniki:** W analizowanym okresie radioterapii poddano 70 dzieci chorych na glejaki. Odsetek trzyletniego EFS dla wszystkich pacjentów wyniósł 44%, a mediana EFS wyniosła 18 miesięcy. Trzyletni EFS u chorych, u których guz wycięto chirurgicznie, wyniósł 58%, a u chorych, których nie operowano, 25% ( $p < 0,05$ ). Odsetek trzyletnich EFS był znacznie mniejszy u chorych z guzami pnia mózgu niż z guzami poza pniem mózgu (odpowiednio 28 i 56%,  $p < 0,01$ ). Stwierdzano nieistotny statystycznie trend w kie-

Correspondence address: Dr Daya Nand Sharma, F-39, Ansari Nagar, New Delhi 110029 India, phone 91-11-26178213, fax 91-11-26589476, e-mail: sharmadn@hotmail.com

Received: 17.09.2009; accepted: 4.01.2010

ing. Results of chemotherapy in high-grade glioma and brainstem gliomas are encouraging.

**Key words:** paediatric glioma, radiation therapy, retrospective analysis.

runku dłuższego przeżycia wśród chorych poddanych chemioterapii.

**Wnioski:** Radioterapia jest skuteczną metodą leczenia dzieci chorych na glejaki, leczonych w ośrodku autorów. Warto ponownie rozważyć możliwość wczesnej radioterapii w częściowo wyciętych glejakach o małej złośliwości. Wyniki chemioterapii w przypadkach glejaków o dużej złośliwości zlokalizowanych w pniu mózgu są zadowalające.

**Słowa kluczowe:** glejaki u dzieci, radioterapia, analiza retrospektywna.

## Introduction

Central nervous system (CNS) tumours are the second commonest cancers in Indian children after lymphoma/leukaemias [1]. More than 50% of all paediatric CNS tumours are gliomas [2,3]. In contrast to adults, low-grade gliomas (LGG) are commoner and carry better prognosis in children. Location wise, infratentorial location is more frequent as compared to those in adults [4]. Though surgery remains the mainstay treatment in paediatric gliomas, radiation therapy (RT) also plays an important role. It is mainly indicated as adjuvant treatment for all high-grade gliomas (HGG) and incompletely resected or progressive LGG; and as definitive treatment, with or without chemotherapy in inoperable gliomas.

The planning and delivery of RT for children is technically challenging, especially in those requiring daily anaesthesia. Immobilization with head casts and other accessories is essential for precise treatment. Though RT plays a vital role, radiation-related late side-effects remain a concern. With the advances in imaging and radiation delivery methods, it is possible to confine the radiation dose to the target area and minimize the radiation to normal brain and therefore reduce late adverse effects [5]. The aim of our study is to analyze the clinical outcome of paediatric astrocytic glioma patients treated with RT.

## Material and methods

For this retrospective analysis, we retrieved the case records of all the paediatric astrocytic glioma patients who received RT in our department between 2004 and 2007. Within each case record, we analyzed the information regarding the patient's demography, clinical details,

diagnosis, treatment given, RT details, and survival. Inclusion criteria consisted of: (1) age less than 18 years, (2) histopathological diagnosis of glioma of any grade or (3) convincing radiological diagnosis of glioma in the absence of histopathological diagnosis. Patients who defaulted the treatment in between, as well as patients with medulloblastoma, ependymoma and other non-glioma histology, were excluded from the present analysis.

The initial clinical workup of the patients consisted of detailed clinical/neurological examination, complete blood count, liver and kidney function tests, plain chest X-ray, and computed tomography (CT) or magnetic resonance imaging (MRI) of the brain (and spine, if necessary). After the surgery or biopsy, patients were referred for RT. Patients who were not eligible for biopsy due to lesions located in the brainstem/inaccessible areas were directly sent to our RT clinic. Expected benefit and sequelae of RT were explained in detail to the parents of each child. All children who were thought to require anaesthesia during RT (children up to 5 years of age in general, and uncooperative children) were sent to the pre-anaesthesia clinic (PAC) for assessment. After the PAC check-up, eligible patients were then called for RT planning. All the patients who required general anaesthesia were essentially admitted to the RT indoor unit. Others were treated on an out patient department basis. Patients were simulated on an X-ray/CT-simulator and treated on a linear accelerator/cobalt. Meticulous shielding of the field was done wherever necessary.

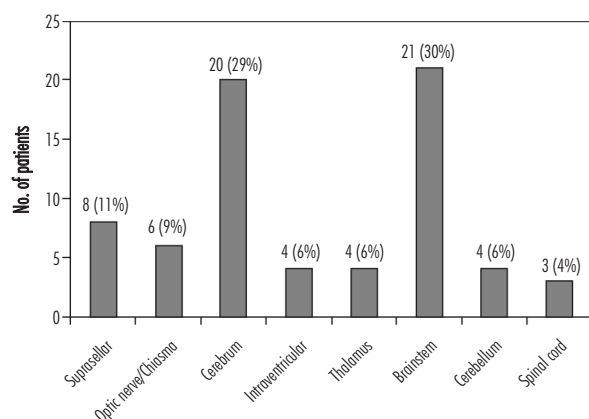
The various indications of RT in our patients were as follows: (1) high-grade tumours, (2) inoperable tumours and (3) low-grade tumours with post-surgery residual or progressive disease. The usual dose of RT was 50-56 Gy for low-grade gliomas and for children below the age of 5 years and 56-60 Gy for high-grade gliomas and patients above the age of 5 years.

**Table 1.** Symptoms at clinical presentation

Symptom	Number	Percentage
Headache	42	60
Seizures	14	20
Cranial nerve palsy	27	39
Limb weakness	15	21
Vision loss	20	19
Cerebellar symptoms	16	23

**Table 2.** Histopathological subtypes

Subtype	Number	Percentage
Pilocytic astrocytoma	22	32
Diffuse fibrillary astrocytoma	4	6
Oligodendroglioma	3	4
Anaplastic astrocytoma	4	6
Mixed gliomas	3	4
Glioblastoma	8	11
Unknown histology	21	30
Others	5	7
Total	70	100



**Fig. 1.** Distribution of patients according to anatomical location of the tumour

During the course of RT, patients were assessed at least once weekly. Complete blood count was done for each patient every week. Follow-up was done every month for the first 6 months and then every 3 months till 2 years. Neuroimaging (CT or MRI) was performed every 6 months or earlier in case of symptomatic deterioration.

Statistical analysis was performed using the statistical software SPSS, version 11.5. The EFS was defined as the period from the date of completion of RT to the date of occurrence of the event, i.e. death or recurrence. EFS

was determined using the Kaplan-Meier survival method [6] with respect to age (below and above 5 years), sex, location of the tumour (brainstem vs. non-brainstem), histopathological characteristics (low-grade vs. high-grade), extent of surgical resection, dose and duration of RT, and use of chemotherapy. Log-rank test was used to determine the *p*-value and *p* < 0.05 was considered significant.

## Results

A total of 70 children with glioma received RT between 2004 and 2007. Their median age was 10 years (range 2-18 years). About 80% of patients were above 5 years of age. There were 42 males and 28 females in the study group. Duration of presenting symptoms ranged from 10 days to 18 months (median 4 months). Various symptoms at clinical presentation are shown in Table 1. Headache was the commonest symptom.

Histopathologically, pilocytic astrocytoma was the commonest subtype. Numbers and percentages of histological subtypes of tumours are provided in Table 2. The brainstem lesions which could not be biopsied were put in a separate histopathological variety. Distribution of patients according to histopathological grade of the tumour was as follows: grade I – 22, grade II – 7, grade III – 7, grade IV – 8, unknown grade – 5, and brainstem – 21 patients. Patients who had brainstem lesions and unknown grade lesions were treated like HGG. Figure 1 shows the anatomical location of tumours in our patients. Brainstem was the commonest site (21 patients), followed by cerebral cortex (20 patients). Most brainstem tumours were diffuse (18 out of 21). The remaining 3 brainstem lesions were exophytic tumours but all three of them were inoperable due to poor general condition of the patient or refusal by the parents.

Of the 70 patients, 45 underwent some form of surgery before RT and the remaining 25 patients were scheduled for RT directly since they were not eligible for surgery. Table 3 shows the details of surgical treatment. Twenty-five patients could not undergo any surgical procedure because of an inaccessible lesion site or poor general condition. Of the 45 patients, 11 underwent gross total excision and 32 underwent debulking surgery in the form of near-total excision or partial removal of the tumour.

Details of RT are outlined in Table 4. Almost all patients received local field RT, except one who received whole brain RT in view of the multi-centricity of the

tumour. Most patients received a total dose of 56 Gy in 28 fractions over 5.5 weeks. One patient, who had spinal cord glioma with paraplegia, received palliative radiotherapy with 20 Gy/5 fractions/1 week in view of the poor general condition. Due to deteriorating clinical condition, one patient could not complete the prescribed dose of 56 Gy and could receive only a total dose of 38 Gy. One patient with multicentric tumour received whole brain RT for a total dose of 40 Gy/20 fractions/4 weeks. All other patients received a minimum total dose of 45 Gy. Nineteen patients received concurrent and/or adjuvant chemotherapy (mostly temozolomide). A total of 64 chemotherapy cycles were given in these 19 patients (average 3 cycles per patient).

The follow-up period ranged from 2 to 50 months, with a median of 18 months. The overall EFS for all patients is depicted in Fig. 2. The 3-year EFS was 44% and the median EFS period was 18 months. Age (< 5 years vs. > 5 years) and sex of the patients did not correlate with EFS. As shown in Fig. 3, the 3-year EFS for LGG and HGG was 46% and 41% respectively ( $p = 0.9$ ). As shown in Fig. 4, patients with brainstem lesions had statistically significantly lower 3-year EFS than those with non-brainstem gliomas (28% vs. 56%,  $p < 0.01$ ). Extent of surgery was associated with significantly improved EFS (Fig. 5). The 3-year EFS in patients who underwent partial resection and no surgery was 58% and 25% respectively ( $p < 0.042$ ). The dose of radiation (56 Gy vs. 60 Gy), dose per fraction (1.8 Gy vs. 2.0 Gy) and type of external beam radiation therapy machine (Cobalt-60 vs. linear accelerator) had no correlation with the outcome. Though a small proportion of patients received chemotherapy (19/70), the 3-year EFS was slightly (but not significantly) better with chemotherapy (Fig. 6).

Due to the short follow-up period, late toxicity was not analyzed in this study. Interruption during the course of RT was considered as indirect incidence of acute toxicity. Eleven patients had interruptions of more than 1-week duration during RT; 6 of them belonged to the RT-alone group (6/51) and 5 belonged to the chemoradiotherapy group (5/19).

## Discussion

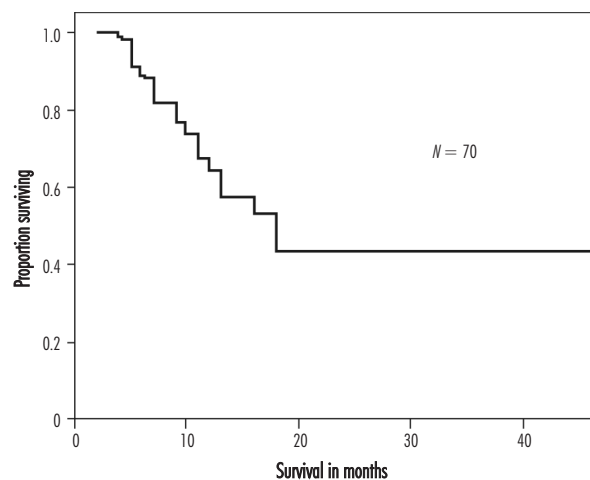
Facilities for RT of paediatric CNS tumours are limited to a few centres in a developing country such as India for various reasons. Management of such patients requires involvement of multiple specialties including

**Table 3.** Details of surgery

Surgical procedure	No. of patients	Percentage
Gross total excision	11	16
Near total excision	13	18
Partial excision	19	27
Biopsy only	2	3
No surgery	25	36
Total	70	100

**Table 4.** Details of radiation therapy

Attribute	
Total dose (Gy)	
range	20-60
median	56
No. of fractions	
range	5-30
median	28
Dose per fraction (Gy)	
range	1.8-4.0
median	2.0
Duration of RT course	
6 weeks	45 patients
more than 8 weeks	11 patients
median duration	6 weeks
no. of patients who required GA	12
RT machine	
cobalt-60	46
linear accelerator (15-18 MV X-rays)	24
Chemotherapy (concurrent and/or adjuvant)	
yes	19 patients
no	51 patients



**Fig. 2.** Event-free survival of all patients

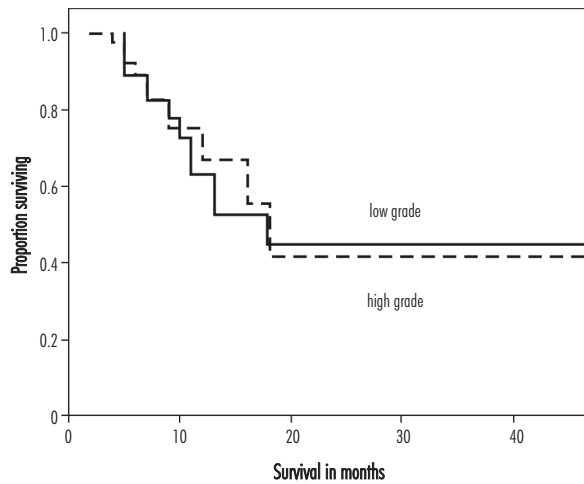


Fig. 3. Event-free survival of patients with low grade vs. high grade gliomas

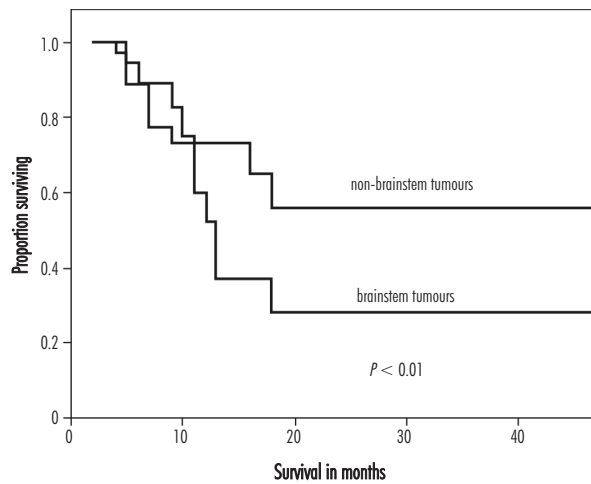


Fig. 4. Event-free survival of patients with brainstem vs. non-brainstem gliomas

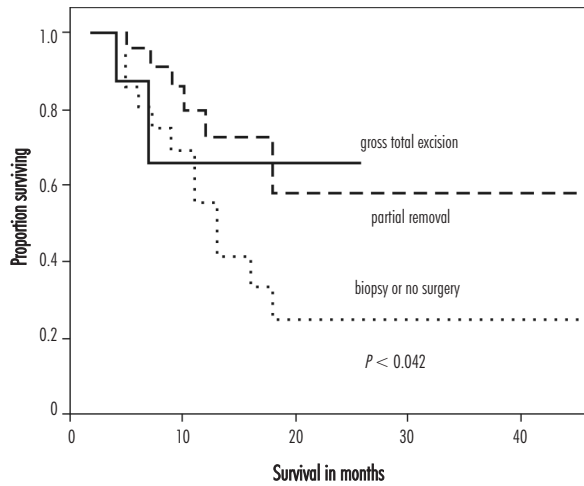


Fig. 5. Event-free survival of patients with surgery vs. no surgery

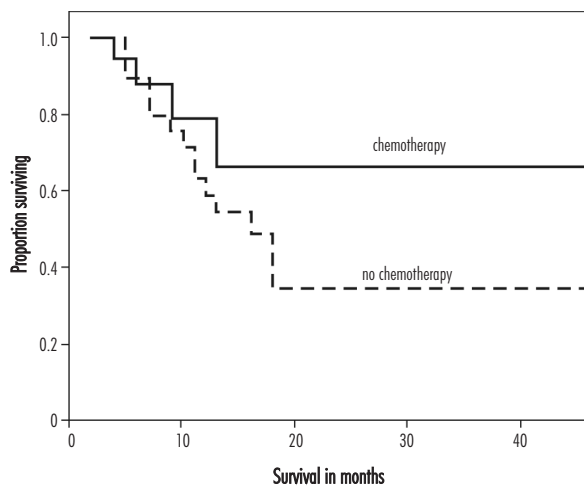


Fig. 6. Event-free survival with and without the use of chemotherapy

neurosurgery and neuroradiology. Most children below the age of 5 years require anaesthesia every day during the delivery of RT and it is therefore a cumbersome treatment. Facilities of RT, in general, are limited. Our centre is an apex medical institute and its cancer centre is one of the 25 regional cancer centres in India. Our experience being reported here represents the outcome of paediatric glioma patients treated at an apex medical centre. Most series [7-10] on paediatric gliomas are not pure glioma series and they include patients with a wide spectrum of tumours including medulloblastomas, ependymomas, etc. The series by Varan *et al.* [10], though titled “astrocytic tumours in children”, excluded patients with optic glioma, brainstem glioma, and diencephalic tumours. Our series comprised patients with paediatric gliomas only and therefore our results may not be strictly comparable with these studies [7-10]. Apparently, EFS for the entire group of patients in our series seems to be lower than the literature since our series had a sizeable number of brainstem lesions which are known to have worse prognosis.

As reported in other series [7-8,11], the extent of surgery before RT is associated with improved survival. We also noticed significantly better survival (58% vs. 25%) in patients who had undergone surgery than those who had no surgery (Fig. 5).

RT provides better results in LGG as compared with HGG. In our series, the 3-year EFS rate was marginally better in favour of LGG (Fig. 3) but it was not statistically significant. This may be due to two factors. Firstly, LGG generally have good prognosis and routine adjuvant RT is not required. However, in the

case of patients who show symptomatic and radiological progression during the follow-up, RT alone or after re-resection plays a vital role; the outcome may not be as good as in those who undergo complete resection and do not show further progression. Several patients with LGG in our series were considered for RT when they had either significant post-surgery residual disease or progression on MRI with or without deteriorating clinical symptoms. The other reason could be that, in our setup, patients find it difficult to comply with the MRI surveillance policy very strictly due to MRI costs and the long distances to travel. Therefore, several of these patients, when they show progression, report for the follow-up with frank clinical progression with large tumours not amenable to complete re-resection. RT for such patients may be less effective. Therefore, early use of RT in patients with post-surgery residual disease may be worth re-visiting. There is, however, a study [12] in adult patients with LGG showing better progression-free survival with use of RT immediately after surgery/biopsy as compared to RT used due to progression. In this study, Arm A patients received RT within 8 weeks after resection or biopsy and Arm B patients received RT when they showed clinical and/or radiological progression. Progression-free survival at 5 years was significantly better in Arm A as compared to Arm B (44% vs. 37%,  $p = 0.02$ ). We feel that for incompletely resected tumours, RT should be initiated early since the modern 3D conformal RT techniques such as stereotactic RT, intensity modulated RT (IMRT), etc. have shown reduced morbidity in several trials [5,9,13].

RT remains an essential component of treatment in HGG even after gross total excision. The 3-year EFS rate of 41% in HGG in our study is more or less the same as reported by Bauman *et al.* [7] and Varan *et al.* [10] in their series.

The various RT parameters did not alter the outcome significantly. The duration of overall treatment (more than 8 weeks) seems to have a correlation with worse outcome in our series but it could not reach statistical significance due to the small number of patients (11 out of 70) completing RT in 8 weeks or more time. Various studies [14,15] have tried altered fractionation schedules in the form of hyperfractionation [14] and accelerated fractionation [15], especially in malignant gliomas and brainstem gliomas, but failed to show any significant benefit over conventional fractionation.

Several trials [16-19] have reported their results with the use of chemotherapy in paediatric gliomas.

Various chemotherapeutic drugs are used in different combinations for both LGG [17] and HGG [16,18,19]. Temozolomide, which has shown promising results in adult glioblastoma multiforme [20], has shown varying results in paediatric gliomas. In our study we have used chemotherapy on a selective basis. Though there was no rigid policy for selection of patients for chemotherapy, it was avoided in patients with poor general condition, low socioeconomic status and unwillingness for chemotherapy. Temozolomide for glioblastoma multiforme and combination of carboplatin and etoposide for other HGG and brainstem tumours were the preferred regimens. Our results have shown a trend towards improved EFS, though not statistically significant, with the use of chemotherapy (Fig. 6).

Brainstem glioma is an important group of CNS tumours in children. Conventional RT remains the standard of care for such patients, but the outcome continues to be poor, with 5-year survival ranging from 20% to 30% [3,4,21,22]. The 3-year EFS of 28% in our series is consistent with that reported in the literature. Chemotherapy with newer agents such as temozolomide [23] has been tried in some recent studies in order to improve the survival, and the results are encouraging.

## Conclusions

Our results of RT in HGG and brainstem gliomas in children are consistent with those in the literature. However, the results of LGG in our series are probably not very decent, possibly because of our policy of delaying the RT till progression after surgery. We therefore suggest a revisit of the policy of early use of RT for incompletely resected LGG even though they are asymptomatic.

## Disclosure

Authors report no conflict of interest.

## References

1. Indian Council of Medical Research. Population-based cancer registry. *Indian Council of Medical Research*, New Delhi, India 2001-2003.
2. Packer R.J. Childhood brain tumors: accomplishments and ongoing challenges. *J Child Neurol* 2008; 23: 1122-1127.
3. Freeman C.R., Farmer J.P., Taylor R.E. Central nervous system tumors in children. In: Halperin E.C., Perez C.A., Brady L.W.

- (eds.). Perez and Brady's principles and practice of radiation oncology. 5<sup>th</sup> edition. *Lippincott Williams & Wilkins*, Philadelphia 2008, pp. 1822.
4. Halperin E.C., Constine L.S., Tarbell N.J., et al. Pediatric radiation oncology. 4<sup>th</sup> edition. *Lippincott Williams & Wilkins*, Philadelphia 2005.
  5. Kirsch D.G., Tarbell N.J. Conformal radiation therapy for childhood CNS tumors. *Oncologist* 2004; 9: 442-450.
  6. Kaplan E.L., Meier P. Nonparametric estimation from incomplete observations. *J Am Stat Assoc* 1958; 53: 457-481.
  7. Bauman G., Fisher B., Cairney E., et al. Radiotherapy for pediatric central nervous system tumors: a regional cancer centre experience. *J Neurooncology* 2004; 68: 285-294.
  8. Jenkin D. Long-term survival of children with brain tumors. *Oncology (Williston Park)* 1996; 10: 715-719.
  9. Merchant T.E., Zhu Y., Thompson S.J., et al. Preliminary results from a phase II trial of conformal radiation therapy for pediatric patients with localized low grade astrocytoma and ependymoma. *Int J Radiat Oncol Biol Phys* 2002; 52: 325-332.
  10. Varan A., Akyüz C., Akalan N., et al. Astrocytic tumors in children: treatment results from a single institution. *Childs Nerv Syst* 2007; 23: 315-319.
  11. Pollack I.F. The role of surgery in pediatric gliomas. *J Neurooncol* 1999; 42: 271-288.
  12. Karim A.B., Afra D., Cornu P., et al. Randomized trial on the efficacy of radiotherapy for cerebral low-grade glioma in the adult: European Organization for Research and Treatment of Cancer Study 22845 with the Medical Research Council study BRO4: an interim analysis. *Int J Radiat Oncol Biol Phys* 2002; 52: 316-324.
  13. Marcus K.J., Goumnerova L., Billett A.L., et al. Stereotactic radiotherapy for localized low grade gliomas in children: final results of a prospective trial. *Int J Radiat Oncol Biol Phys* 2005; 61: 374-379.
  14. Freeman C.R. Hyperfractionated radiotherapy for diffuse intrinsic brain stem tumors in children. *Pediatr Neurosurg* 1996; 24: 103-110.
  15. Lewis J., Lucraft H., Gholkar A. UKCCSG study of accelerated radiotherapy for pediatric brain stem gliomas. United Kingdom Childhood Cancer Study Group. *Int J Radiat Oncol Biol Phys* 1997; 38: 925-929.
  16. Pollack I.F., Boyett J.M., Finlay J.L. Chemotherapy for high grade gliomas of childhood. *Childs Nerv Syst* 1999; 15: 529-544.
  17. Khaw S.L., Coleman L.T., Downie P.A., et al. Temozolomide in pediatric low-grade glioma. *Pediatr Blood Cancer* 2007; 49: 808-811.
  18. Verschuur A.C., Grill J., Lelouch-Tubiana A., et al. Temozolomide in pediatric high-grade glioma: a key for combination therapy? *Br J Cancer* 2004; 91: 425-429.
  19. Lashford L.S., Thiesse P., Jouvett A., et al.; a United Kingdom Children's Cancer Study Group and French Society for Pediatric Oncology Intergroup Study. Temozolomide in malignant gliomas of childhood: a United Kingdom Children's Cancer Study Group and French Society for Pediatric Oncology Intergroup Study. *J Clin Oncol* 2002; 20: 4684-4691.
  20. Stupp R., Mason W.P., van den Bent M.J., et al.; European Organisation for Research and Treatment of Cancer Brain Tumor and Radiotherapy Groups; National Cancer Institute of Canada Clinical Trials Group. Radiotherapy plus concomitant and adjuvant temozolomide for glioblastoma. *N Engl J Med* 2005; 352: 987-996.
  21. Broniscer A., Gajjar A. Supratentorial high-grade astrocytoma and diffuse brainstem glioma: two challenges for the pediatric oncologist. *Oncologist* 2004; 9: 197-206.
  22. Freeman C.R., Farmer J.P. Pediatric brain stem gliomas: a review. *Int J Radiat Oncol Biol Phys* 1998; 40: 265-271.
  23. Broniscer A., Iacono L., Chintagumpala M., et al. Role of temozolomide after radiotherapy for newly diagnosed diffuse brainstem glioma in children. *Cancer* 2005; 103: 133-139.