

Bartłomiej Syzdol¹, Marek Antoni Lew¹, Magdalena Maria Woźniak¹

Department of Paediatric Radiology, Medical University of Lublin, Poland

A rare cause of dyspnoea and chest pain in adolescent post-traumatic patient

Corresponding author:

Bartłomiej Syzdol, MD
 Department of Paediatric Radiology,
 Medical University of Lublin
 Al. Raclawickie 1 St.,
 20-059, Lublin, Poland
 e-mail: bartlomiej.syzdol@gmail.com

Medical Research Journal 2024;
 Volume 9, Number 3, 310–312
 DOI: 10.5603/mrj.101608
 Copyright © 2024 Via Medica
 ISSN 2451-2591
 e-ISSN 2451-4101

ABSTRACT

This paper presents a case of a 16-year-old boy with dyspnoea and chest pain after injury with changes in the lung observed on the radiograph that may have suggested post-traumatic fluid. Further examinations revealed atelectasis that was caused by compression of the left lung by fluid that originated from pulmonary metastases of the tumour located in the left testicle. Vigilance should be maintained during the physical examination and history taking. Initial symptoms may suggest a traumatic aetiology, while the cause could be different and an acute or chronic process unrelated to trauma should be considered.

Keywords: testicular cancer; metastases; paediatric oncology; computed tomography

Med Res J 2024; 9 (3): 310–312

A 16-year-old boy was admitted to the hospital with soreness in the left half of his chest and dyspnoea, which prevented him from getting out of bed on his own. On admission, the patient was very weak and suffering from strong chest pain. Physical examination revealed a respiratory rate of 44/min, a saturation of 96% and a diminished vesicular murmur at the left side of the chest. Due to the patient's report of an injury during handball training on the previous day, a chest radiograph and chest computed tomography (CT) were performed, which revealed fluid in the left pleural cavity with atelectatic changes (Fig. 1A, B). After surgical consultation, a pleural drainage was performed. Due to the haematoma formed after pleural drainage, the patient was transferred to the Department of Paediatric Surgery and Traumatology, where approximately 2000 mL of bloody contents were drained within 3 days without symptoms accompanying bleeding into the pleural cavity. As the cause of the symptoms and lung changes was still unclear further investigations were considered including examinations of the abdomen, pelvis and scrotum. At this stage on physical examination, a large left testicular tumour was observed. A testicular ultrasound revealed a tumour of the left testicle (Supplementary File — Fig. S1, S2). Laboratory tests showed increased levels of tumour markers beta human chorionic gonadotropin (11290 mIU/mL) and alpha-fetoprotein (1173 ng/mL).

CT was performed (Fig. 1C, D) and revealed metastatic tumours in the lung. Orchiectomy of the left testicle was performed, and the patient was qualified for combination chemotherapy for high-risk germ cell tumours according to the VIP regimen (etoposide, ifosfamide, cisplatin). Four weeks after starting chemotherapy, a follow-up CT scan was performed (Supplementary File — Fig. S3).

Atelectasis describes the condition of decreased volume of lung parenchyma due to reduced aeration of alveoli. It can be caused by obstruction, inability to re-expand the lung and increased surface tension. Usually, the symptoms of atelectasis are nonspecific due to the different mechanisms causing it, and thus it is easy to misinterpret it by treating it as a disease in itself and not as a manifestation of the underlying disease [1, 2]. The presented case of a 16-year-old boy emphasizes that the symptoms reported by the patient should be considered holistically. The described patient reported only dyspnoea and chest pain on the left side. Radiological examinations revealed atelectatic changes. Significantly, the atelectasis was caused by compression of the left lung by fluid that originated from pulmonary metastases of a tumour located in the left testicle. The possibility of testicular cancer in men aged 15–35 should be considered, as it is the most common solid malignancy in this age group, and overall

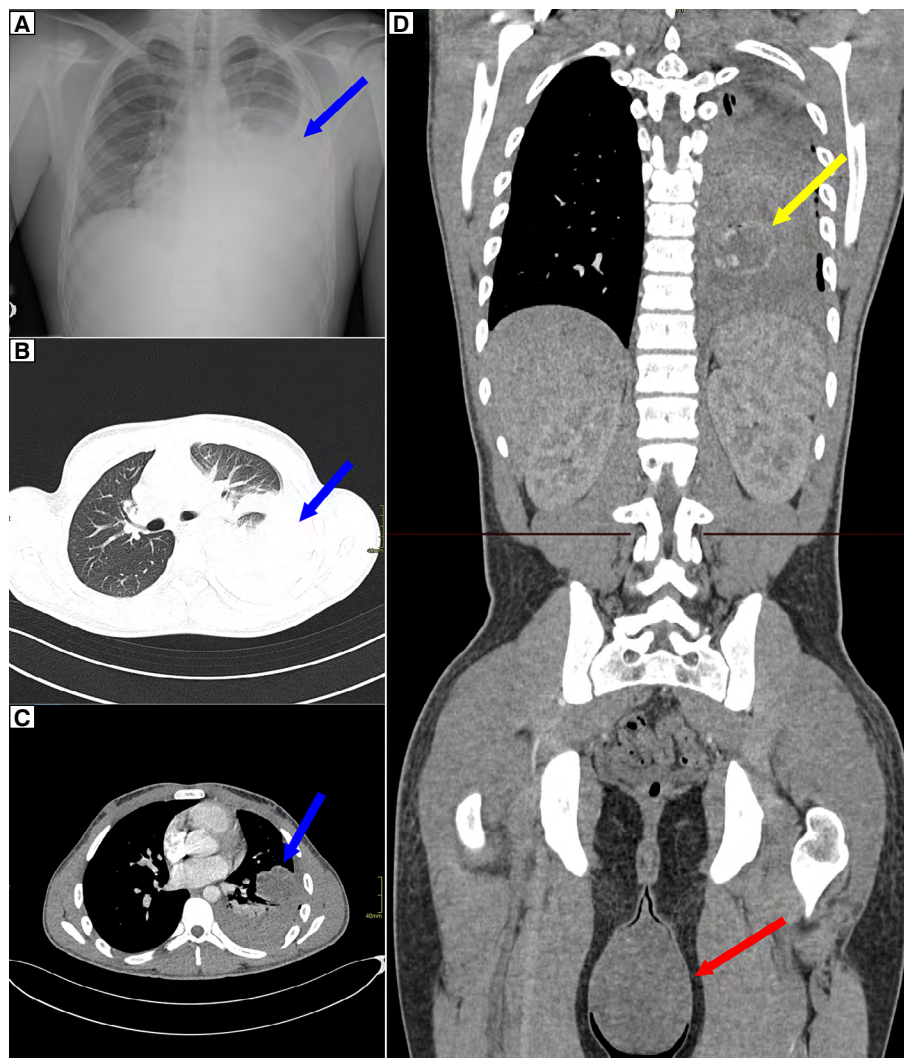


Figure 1. **A.** chest radiograph, accumulation of fluid in the left lung (blue arrow); **B.** computed tomography (CT) scan showing atelectatic area and fluid in the left lung (blue arrow); **C.** CT scan, axial view, reduced atelectasis with persistent fluid and pulmonary metastases (blue arrow) visualized for the first time; **D.** CT scan, coronal view, pulmonary metastases (yellow arrow) and significantly enlarged left testicle (red arrow)

occurs in only 1% of cancers in men [3]. Because of its sparse symptoms (occurrence of acute pain in only 10%) and patients' embarrassment to report testicular problems, diagnosis may be delayed or missed [4, 5]. Vigilance should be maintained during the physical examination and history taking. Initial symptoms of the present patient suggested a traumatic aetiology, and the changes in the lung observed on the radiograph may have suggested post-traumatic fluid. In this case, the cause was completely different and an acute or chronic process unrelated to trauma should be considered. Understanding the situations in which atelectasis is more likely to occur and the underlying pathophysiological mechanisms helps in the diagnosis [1].

Article information

Acknowledgements: None.

Ethics statement: Ethical approval is not required for this study by local or national guidelines. Patient data is fully anonymous.

Author contributions: BS — conception and design of the work, writing — original draft preparation, editing, project administration; MAL — collecting data, interpretation of data, writing — editing; MMW — writing — editing, supervising, final approval.

Funding: None.

Conflict of interest: None declared.

Supplementary material: Supplementary File including 3 figures.

References

1. Carlsen K, Crowley S, Smevik B. Atelectasis. *Kendig's Disorders of the Respiratory Tract in Children*. 2019: 1027–1033.e1, doi: [10.1016/b978-0-323-44887-1.00070-5](https://doi.org/10.1016/b978-0-323-44887-1.00070-5).
2. Peroni DG, Boner AL. Atelectasis: mechanisms, diagnosis and management. *Paediatr Respir Rev*. 2000; 1(3): 274–278, doi: [10.1053/prv.2000.0059](https://doi.org/10.1053/prv.2000.0059), indexed in Pubmed: [12531090](https://pubmed.ncbi.nlm.nih.gov/12531090/).
3. Siegel RL, Giaquinto AN, Jemal A. Cancer statistics, 2024. *CA Cancer J Clin*. 2024; 74(1): 12–49, doi: [10.3322/caac.21820](https://doi.org/10.3322/caac.21820), indexed in Pubmed: [38230766](https://pubmed.ncbi.nlm.nih.gov/38230766/).
4. Chung P, Warde P, Chung P, et al. Testicular cancer: seminoma. *BMJ Clin Evid*. 2011; 2011, indexed in Pubmed: [21477387](https://pubmed.ncbi.nlm.nih.gov/21477387/).
5. Öztürk Ç, Fleer J, Hoekstra HJ, et al. Delay in Diagnosis of Testicular Cancer; A Need for Awareness Programs. *PLoS One*. 2015; 10(11): e0141244, doi: [10.1371/journal.pone.0141244](https://doi.org/10.1371/journal.pone.0141244), indexed in Pubmed: [26606249](https://pubmed.ncbi.nlm.nih.gov/26606249/).