

Anna Maria Rzewuska-Fijałkowska¹ , Bartłomiej Syzdoł¹ , Monika Żybowska¹ ,
Wiktoria Ewa Sielwanowska¹ , Paulina Oleksa² , Kacper Jasiński² , Daria Żuraw³ 

¹Medical University of Lublin, Poland

²University Clinical Hospital No.4 in Lublin, Poland

³Central Clinical Hospital, University Clinical Center of Warsaw Medical University, Poland

The biliary obstruction of the small intestine — Barnard syndrome

Corresponding author:

Bartłomiej Syzdoł, MD
Medical University of Lublin
Aleje Racławickie 1 St.,
20-059 Lublin, Poland
e-mail: bartlomiej.syzdol@gmail.com

Medical Research Journal 2024;
DOI: 10.5603/mrj.101467 Copyright
© 2024 Via Medica ISSN 2451-2591
e-ISSN 2451-4101

ABSTRACT

Introduction and aim: The biliary obstruction of the small intestine (Barnard syndrome) is a rare condition of gastrointestinal obstruction due to gallstones, accounting for approximately 1.4–6% of all obstruction cases.

Description of the case: The study presents an 88-year-old woman admitted to the hospital due to abdominal pain and faecal vomiting. An abdominal X-ray revealed single, short levels of fluid and gastrointestinal obstruction was suspected. The patient was qualified for an exploratory laparotomy. In the ileum, a hard, movable lesion with a diameter of 2 cm was found about 10 cm from the Bauhin valve. The stone was evacuated. No complications were observed in the postoperative period, and on the 12th day, the patient was discharged home in good condition.

Conclusion: Analysing the above clinical case, it can be concluded that biliary obstruction is a very rare disease, which is difficult to diagnose. It is worth paying attention to the possibility of this disease in patients who suffer from gallstones.

Keywords: biliary obstruction, gallstones, the obstruction of the small intestine

Med Res J 2024

Introduction

The biliary obstruction of the small intestine (Barnard syndrome) is a rare condition of gastrointestinal obstruction due to gallstones, accounting for approximately 1.4–6% of all obstruction cases [1]. The characteristic symptoms of the disease are gas retention, abdominal cramps, vomiting and nausea. The bile obstruction of the small intestine can occur in any segment of the intestine, but usually, it is most often located in its anatomical stenoses: near the ileocecal valve and in the area of the duodenojejunal flexure. In radiological diagnostics, the characteristic symptoms make up the Rigler's triad, which are: aerobilia (presence of air in the bile ducts), intestinal obstruction, and the presence of a mineralized deposit on a plain radiograph of the abdominal cavity [1]. Among patients over 65 years old, biliary obstruction of the small intestine accounts for approximately 25% of all causes of high intestinal obstruction [2]. The mortality ranges between 12% and 20% [3].

Aim of the study

The study presents a case of an 88-year-old female hospitalized due to biliary obstruction of the small intestine (Barnard syndrome).

Description of the case

An 88-year-old female patient was admitted to the emergency room due to severe abdominal pain and faecal vomiting for several days. The female reported acute pancreatitis due to cholelithiasis with cholangitis. For this reason, she also underwent endoscopic retrograde cholangiopancreatography (ERCP). Moreover, the patient stated that she suffers from chronic rheumatoid arthritis and hypertension and had endoplasty of the hip joint. Laboratory tests showed leucocytosis — 13.000/ μ L (reference range: 4.500–11.000/ μ L) and elevated C-reactive protein — 21 mg/L (reference range: 0–10 mg/L). Imaging examinations were performed:

abdominal X-ray (Fig. 1) and computed tomography. Features of gastrointestinal obstruction were found. The patient was admitted to the surgical department.

The next day, an ultrasound examination (USG) revealed distended loops of the small intestine with residual liquid contents and free fluid between the loops. The patient was urgently qualified for surgical treatment. An exploratory laparotomy was performed under general anaesthesia. After opening the peritoneal cavity, a small amount of yellowish fluid was aspirated. In the small intestine, about 10 cm from the Bauhin's valve, a hard, movable lesion with a diameter of about

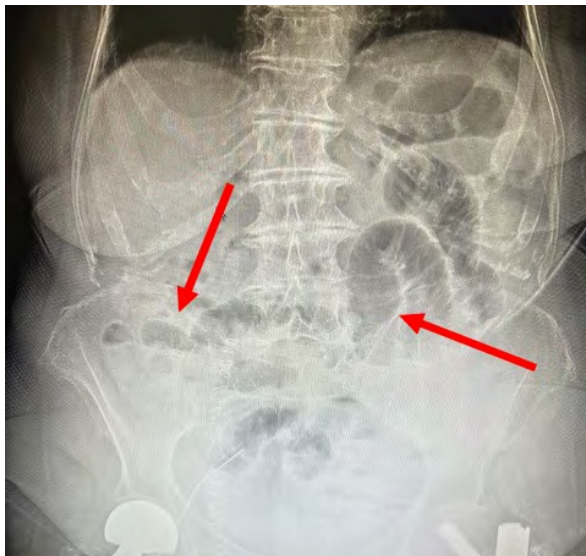

Figure 1. Abdominal X-ray showed short fluid levels in the mid-abdomen and distended intestinal loops. Red arrows represent described changes

2 cm was found — it was suspected to be a gallstone. The wall of the small intestine was incised and the stone was evacuated (Fig. 2). Also, a small amount of intestinal contents was aspirated. Then, the peritoneal cavity was rinsed with a physiological solution. A drain from a separate incision was placed in the pouch of Douglas, leading it out into the right iliac fossa. Analgesic treatment and prophylactic antibiotic therapy were applied.

One week after laparotomy, USG in the mid-abdomen and on the left side of the lower abdomen showed constantly dilated intestinal loops with residual content and peristalsis. The intrahepatic tracts were not dilated but visible gas bubbles were still visible. An abdominal X-ray was also taken (Fig. 3).

The patient was in good condition and did not report any pain. No complications were observed in the postoperative interview. Twelve days after surgery, the female was discharged home with recommendations for follow-up at the surgical clinic.

Discussion

Biliary obstruction occurs as a result of blockage of the digestive tract by a gallstone, usually larger than 2–2.5 cm, which enters the intestinal lumen most often through a fistula from the gallbladder. A distinction is made between Bouveret's syndrome, i.e. blockage of the duodenum by a gallstone, and Barnard's syndrome, which is a mechanical obstruction of the small intestine caused by a bile deposit [4]. Clinical symptoms are usually poorly expressed, and the correct diagnosis is delayed and hindered by numerous chronic comorbidities,

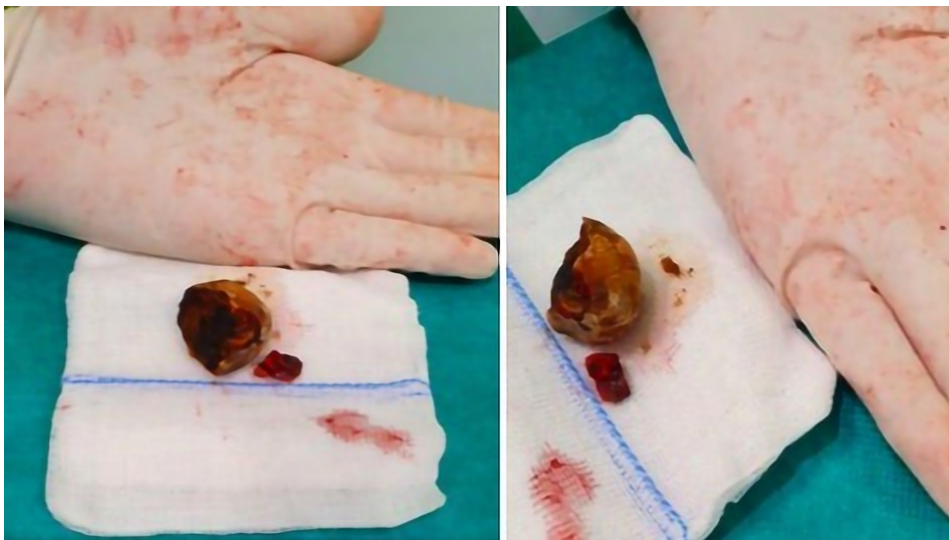

Figure 2. The gallstone

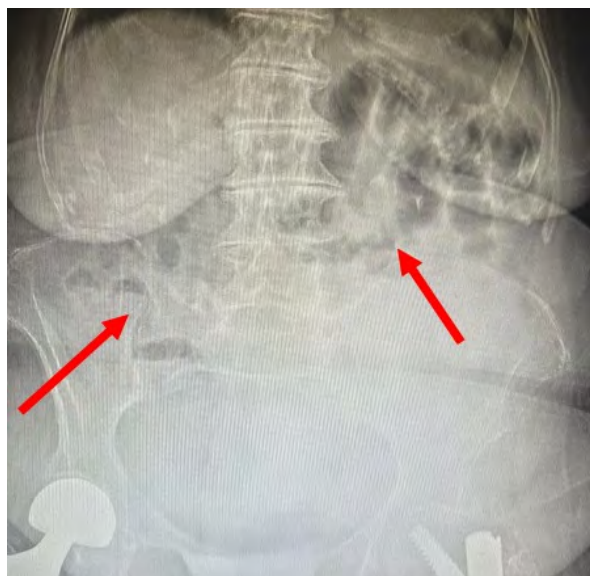


Figure 3. An abdominal X-ray showed short fluid levels and dilated gas-filled intestinal loops remaining in the mid-abdomen. Red arrows represent described changes

such as cardiovascular diseases and diabetes, which often occur in elderly patients [5, 6]. The treatment of choice for biliary obstruction is surgery, and the main goal of treatment is to remove the deposit obstructing the gastrointestinal tract [5]. After the diagnosis is made, the treatment process should be planned to take into account: the general condition, age, comorbidities, location of the obstruction, presence of local inflammation, the number and size of deposits, and the width of the fistula. Methods of surgical treatment can be divided into one-stage and two-stage treatment. During the one-stage operation, the wall of the small intestine is incised, the stone is removed, the gallbladder is removed, and the vesico-intestinal fistula is eliminated. This method is reserved for younger patients in good general condition, without symptoms of circulatory and respiratory failure. In the case of two-stage treatment, an enterolithotomy with stone removal is performed, followed by a delayed cholecystectomy with the treatment of the vesico-intestinal fistula [7]. The following treatment was used in the presented case report, mostly due to the advanced age of the patient. Endoscopy may play an important role due to its less invasive nature and lower complication rate than the classic surgical approach [8]. Endoscopic treatment is effective when the stone is located in the stomach, bulb or descending part of the duodenum [9].

Conclusions

Analysing the above clinical case, it can be concluded that biliary obstruction is a rare disease. The results of radiological examination are ambiguous, and the reported symptoms are non-specific, which extends the time of correct diagnosis. It is worth paying attention to the possibility of this disease among patients who suffer from gallstones.

Article information

Ethics statement: Verbal informed consent was obtained for anonymized patient information to be published in this case report, due to the fact that the patient was not able to sign the consent.

Author contributions: Each author of this article has made substantial contributions to the conception, design, implementation and interpretation.

Acknowledgements: None.

Conflict of interest: None declared.

Supplementary material: None.

Funding: None.

References

1. Kożuch M, Jarosz M, Milek T, et al. Przypadek niedrożności żółciowej jelita cienkiego. *Prz Gastroenterol.* 2008; 3(5): 268–270.
2. Chuah PS, Curtis J, Misra N, et al. Pictorial review: the pearls and pitfalls of the radiological manifestations of gallstone ileus. *Abdom Radiol (NY).* 2017; 42(4): 1169–1175, doi: [10.1007/s00261-016-0996-0](https://doi.org/10.1007/s00261-016-0996-0), indexed in Pubmed: [27896385](https://pubmed.ncbi.nlm.nih.gov/27896385/).
3. Karadimos D, Keelan S, Maundura M, et al. Impacted duodenal gallstone presenting as gastric outlet obstruction: a rare case of Bouveret syndrome. *ANZ J Surg.* 2020; 90(3): 379–381, doi: [10.1111/ans.15142](https://doi.org/10.1111/ans.15142), indexed in Pubmed: [30983134](https://pubmed.ncbi.nlm.nih.gov/30983134/).
4. Chang L, Chang M, Chang HM, et al. Clinical and radiological diagnosis of gallstone ileus: a mini review. *Emerg Radiol.* 2018; 25(2): 189–196, doi: [10.1007/s10140-017-1568-5](https://doi.org/10.1007/s10140-017-1568-5), indexed in Pubmed: [29147883](https://pubmed.ncbi.nlm.nih.gov/29147883/).
5. Nuño-Guzmán CM, Marín-Contreras ME, Figueroa-Sánchez M, et al. Gallstone ileus, clinical presentation, diagnostic and treatment approach. *World J Gastrointest Surg.* 2016; 8(1): 65–76, doi: [10.4240/wjgs.v8.i1.65](https://doi.org/10.4240/wjgs.v8.i1.65), indexed in Pubmed: [26843914](https://pubmed.ncbi.nlm.nih.gov/26843914/).
6. Caldwell KM, Lee SJ, Leggett PL, et al. Bouveret syndrome: current management strategies. *Clin Exp Gastroenterol.* 2018; 11: 69–75, doi: [10.2147/CEG.S132069](https://doi.org/10.2147/CEG.S132069), indexed in Pubmed: [29497323](https://pubmed.ncbi.nlm.nih.gov/29497323/).
7. Braźnik A, Kuczia M. Niedrożność jelita cienkiego wywołana przez kamień żółciowy – opis przypadku. *Państwo i Społeczeństwo.* 2020; 4: 77–83, doi: [10.48269/2451-0858-pis-2020-4-008](https://doi.org/10.48269/2451-0858-pis-2020-4-008).
8. Varre JS, Wu JL, Hopmann P, et al. Endoscopic and surgical management of Bouveret's syndrome complicated by gallstone ileus. *J Surg Case Rep.* 2021; 2021(10): rjab464, doi: [10.1093/jscr/rjab464](https://doi.org/10.1093/jscr/rjab464), indexed in Pubmed: [34729172](https://pubmed.ncbi.nlm.nih.gov/34729172/).
9. Kozieł S, Papaj P, Dobija-Kubica K, et al. Gall-Stone Ileus--Own Patients And Literature Review. *Pol Przegl Chir.* 2015; 87(5): 260–267, doi: [10.1515/pjs-2015-0051](https://doi.org/10.1515/pjs-2015-0051), indexed in Pubmed: [26172166](https://pubmed.ncbi.nlm.nih.gov/26172166/).