

Primary antiphospholipid syndrome in a male with myocardial infarction with non-obstructive coronary arteries and a history of stroke

Paweł Rostoff^{1,2}, Dominika Drwiła-Stec^{1,2}, Krzysztof Karwat^{1,2}, Małgorzata Urbańczyk-Zawadzka^{2,3},
Jadwiga Nessler^{1,2}, Ewa Konduracka^{1,2}

¹Department of Coronary Disease and Heart Failure, Institute of Cardiology, Jagiellonian University Medical College, Kraków, Poland

²John Paul II Hospital, Kraków, Poland

³Department of Radiology and Diagnostic Imaging, John Paul II Hospital, Kraków, Poland

Correspondence to:

Paweł Rostoff, MD, PhD,
Department of Coronary Disease
and Heart Failure,
Institute of Cardiology,
Jagiellonian University Medical
College, John Paul II Hospital,
Prądnicka 80,
31–202 Kraków, Poland,
phone: +48 12 614 22 18,
e-mail: pawel.rostoff@uj.edu.pl

Copyright by the Author(s), 2023

DOI: 10.33963/KPa2022.0176

Received:

October 19, 2022

Accepted:

November 27, 2022

Early publication date:

December 20, 2022

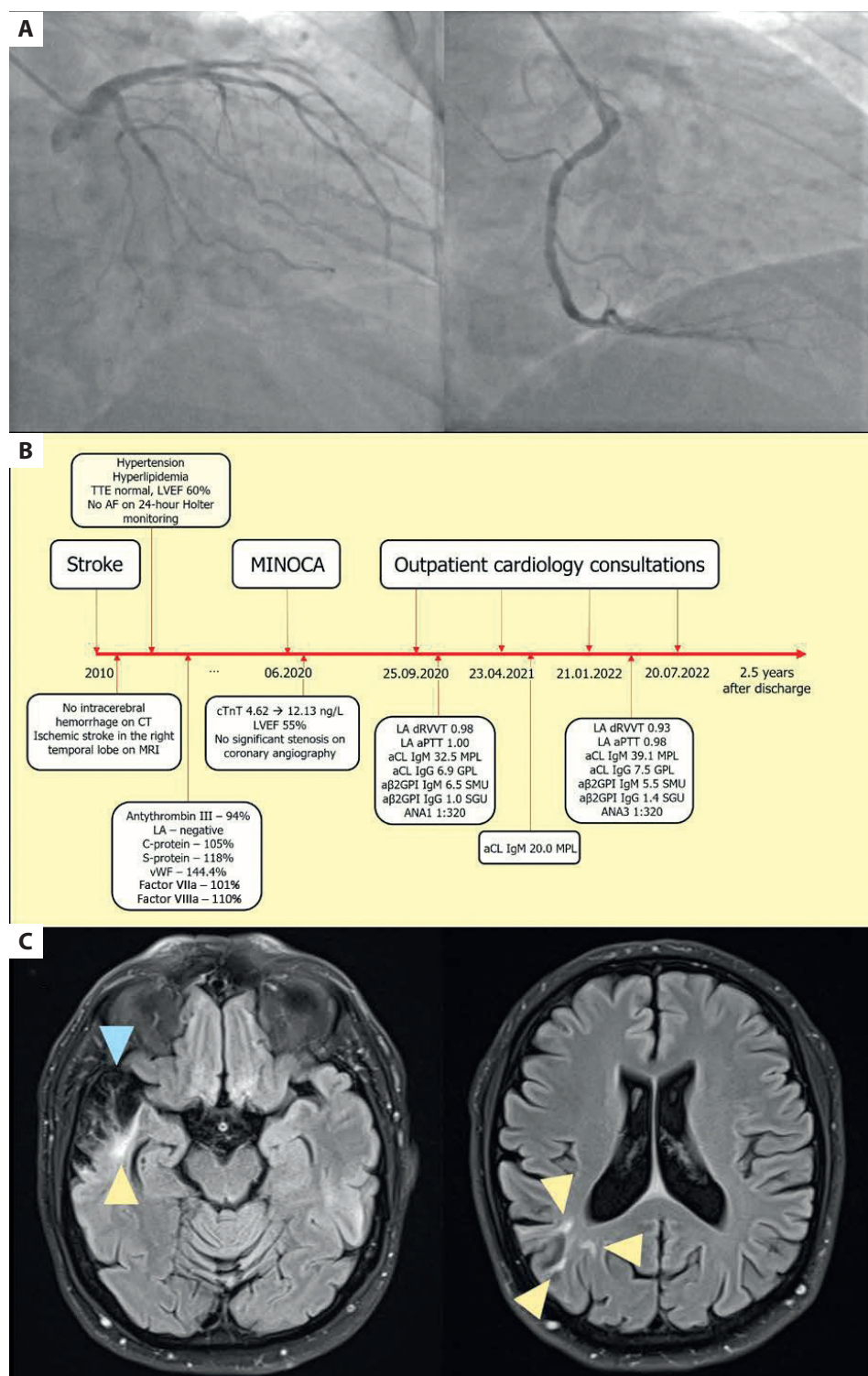
A 55-year-old man with obesity, hypertension, hyperlipidemia, and a history of right-sided ischemic stroke at the age of 45 was referred to a cardiology outpatient center after hospitalization for non-ST-segment elevation myocardial infarction with non-obstructive coronary arteries (Figure 1A; Supplementary material, Video S1–S6). Non-ST-segment elevation myocardial infarction with non-obstructive coronary arteries was diagnosed based on typical symptoms and dynamics of high-sensitive cardiac troponin T levels: 4.62 ng/l on admission and 114.80 ng/l after 6 hours (normal: 0–14 ng/l). No ischemic changes were observed on the electrocardiogram. Other causes of increased serum high-sensitive cardiac troponin T were excluded. Transthoracic echocardiography showed normal ventricular function, left ventricular ejection fraction of 55%, without significant valve defects.

Three months later, at a follow-up outpatient center visit, he was completely free of cardiovascular symptoms. The electrocardiogram showed pathologic Q waves in the lateral leads, and transthoracic echocardiography showed no abnormalities. Cardiac magnetic resonance imaging showed no pathology. No stenosis was found on carotid duplex ultrasound. Routine blood test results were normal, except for mildly reduced red blood cell parameters and elevated levels of low-density lipoprotein cholesterol (2.90 mmol/l) and triglycerides (2.02 mmol/l). Inherited thrombophilia was excluded.

Since we suspected antiphospholipid syndrome (APS), the plasma levels of antiphospholipid antibodies (aPL) were measured. The lupus anticoagulant in the dilute Russell's viper venom time (dRVVT) and activated partial thromboplastin time (aPTT) assays was absent. The anticardiolipin antibodies (aCL) IgM were elevated (32.5 MPL [normal, 0–17.0 MPL]) while aCL IgG as well as anti-β2-glycoprotein I antibodies (aβ2GPI) IgM and IgG were normal. A weakly positive titer of antinuclear antibodies (ANA 1:320) was also found. Single-positive APS was diagnosed.

According to the current recommendations [1–3], aPL levels were reassessed after ≥12 weeks. Elevated aCL IgM were found to persist both after 8 months (20.0 MPL) and 20 months (39.1 MPL) (Figure 1B). Despite the still weakly positive titers of antinuclear antibodies (ANA 3 1:320), elevated levels of anti-double-stranded deoxyribonucleic acid antibodies (anti-dsDNA), anti-nucleosome, and anti-histone antibodies were not detected. There was also no clinical evidence of systemic connective tissue disease or another secondary cause of APS at 2-year follow-up.

Magnetic resonance imaging of the brain showed an extensive area of malacic lesions in the right temporal lobe. Moreover, in the cerebral hemispheres, there were single small areas of raised signal in the sequence with a long time of repetition, consistent with nonspecific demyelinating lesions, primarily ischemic (Figure 1C).



In chronic pharmacotherapy, aspirin 75 mg/d, metoprolol succinate 25 mg/d, valsartan 80 mg bid, and rosuvastatin 10 mg/d were used. APS is characterized by venous, arterial, or microvascular thrombosis and/or adverse pregnancy outcomes in the presence of persistent laboratory evidence of aPL [1–3]. As acquired thrombophilia, APS can be diagnosed at any age but is 5-fold less common in men [1–3]. Acute myocardial infarction is a very rare (2.8%) manifes-

tation of APS [4, 5]. Despite indications to use warfarin in APS patients with arterial thromboembolism, our patient was treated with aspirin, given his relatively low aCL levels, with close ambulatory surveillance and follow-up outpatient visits every 6 months. It is also important to search for other cardiovascular risk factors and their appropriate treatment, which can significantly improve the prognosis of APS patients.

Article information

Acknowledgments: The authors thank Professor A. Undas for her valuable comments on the content of the article.

Conflict of interest: None declared.

Funding: The study was supported by a research grant: N41/DBS/001004 from the Jagiellonian University Medical College (to PR).

Open access: This article is available in open access under Creative Commons Attribution-Non-Commercial-No Derivatives 4.0 International (CC BY-NC-ND 4.0) license, which allows downloading and sharing articles with others as long as they credit the authors and the publisher, but without permission to change them in any way or use them commercially. For commercial use, please contact the journal office at kardiologiapolska@ptkardio.pl.

REFERENCES

1. Calcaterra I, Tufano A, Lupoli R, et al. Cardiovascular disease and antiphospholipid syndrome: how to predict and how to treat? *Pol Arch Intern Med.* 2021; 131(2): 161–170, doi: 10.20452/pamw.15415, indexed in Pubmed: 32491304.
2. Lóczy L, Kappelmayer J, Tarr T, et al. Antiphospholipid syndrome and the risk of myocardial infarction: current evidence and uncertainties. *Kardiol Pol.* 2020; 78(1): 6–14, doi: 10.33963/KP.15090, indexed in Pubmed: 31808421.
3. Žigon P. Do antiphospholipid antibodies enhance thromboembolic risk in patients with cancer? *Pol Arch Intern Med.* 2020; 130(12): 1026–1028, doi: 10.20452/pamw.15724, indexed in Pubmed: 33355433.
4. Cervera R, Piette JC, Font J, et al. Antiphospholipid syndrome: clinical and immunologic manifestations and patterns of disease expression in a cohort of 1,000 patients. *Arthritis Rheum.* 2002; 46(4): 1019–1027, doi: 10.1002/art.10187, indexed in Pubmed: 11953980.
5. Zasada W, Bobrowska B, Plens K, et al. Acute myocardial infarction in young patients. *Kardiol Pol.* 2021; 79(10): 1093–1098, doi: 10.33963/KP.a2021.0099, indexed in Pubmed: 34472075.