

Challenging coronary cannulation after insertion of a self-expandable transcatheter aortic valve: The distal anchor-guide catheter extension sliding technique

Giuseppe Talanas, Pierluigi Merella, Marco Saderi, Giovanni Lorenzoni, Cristiana Denurra, Gavino Casu

Clinical and Interventional Cardiology, Sassari University Hospital, Sassari, Italy

Correspondence to:
Giuseppe Talanas, MD,
Clinical and Interventional
Cardiology, Sassari University
Hospital,
Via Enrico De Nicola,
07100 Sassari, Italy,
phone: +39 0 79 206 154 01,
e-mail: giuseppe.talanas@aouss.it
Copyright by the Author(s), 2022
DOI: 10.33963/KPa.2022.0275
Received: November 1, 2022
Accepted: November 27, 2022
Early publication date:
December 4, 2022

A 71-year-old male with a previous coronary artery bypass graft, multiple percutaneous coronary interventions (PCI), and transcatheter aortic valve replacement (TAVR) performed in 2019 with an Evolut R 29 mm (Medtronic, Minneapolis, MN, US) was admitted for refractory angina. Selective coronary cannulation (CC) was impossible due to the metallic valve stent frame while a semi-selective angiography permitted observation of severe stenosis in both mid right coronary (RCA) and ostial circumflex (CFx) arteries (Figure 1A–B). Then, with a floating AL 1 6 F guide catheter (GC),

we performed a flying-wire advancement in the RCA (Supplementary material, *Video S1*). After anchoring a 2.0/15 mm balloon in the mid RCA, we gently slid a 6 F guide catheter extension (GCE) over this wire into the proximal RCA, which we named distal anchor-GCE sliding technique (Figure 1C, Supplementary material, *Video S2*). After this maneuver, two overlapping stents were successfully implanted in the mid RCA (Figure 1D, Supplementary material, *Video S3*). The same technique, using the same AL 1 6 F GC, was successfully used to stent the left

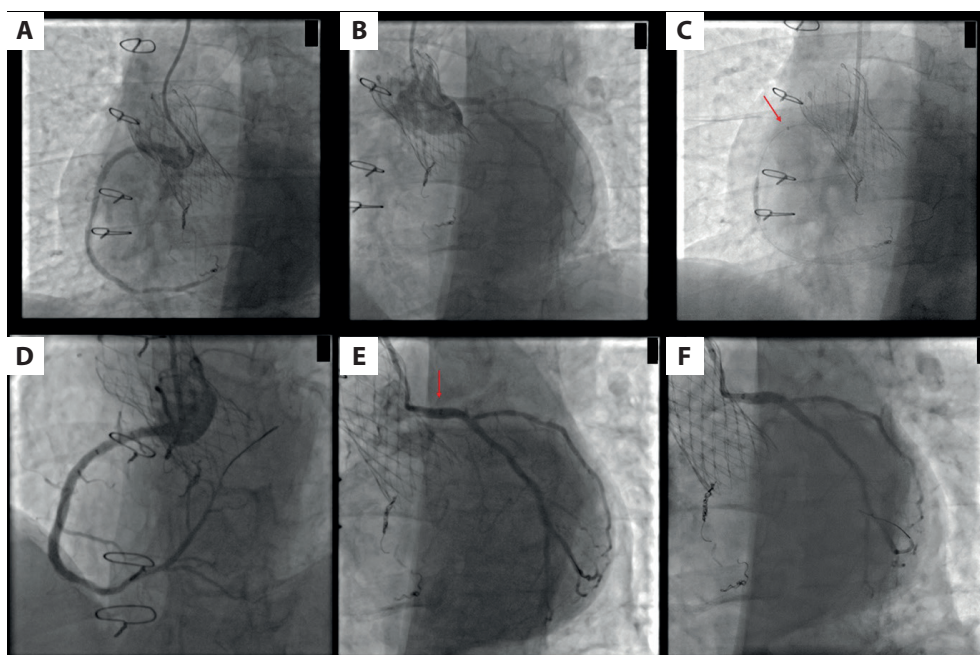


Figure 1. A–B. Semi-selective angiography shows severe stenosis of both mid RCA and ostial CFx arteries. C. Anchoring balloon in mid RCA and simultaneous advancement of GCE in proximal RCA (red arrow). D. Final angiographic result after insertion of two overlapping stents in the mid RCA. E. Selective engagement of the left main with GCE (red arrow). F. Final angiographic result after stent implantation in the left main-proximal CFx artery

Abbreviations: CFx, circumflex artery; GCE, guide catheter extension; RCA, right coronary artery

main-proximal CFX (Figure 1E, 1F, Supplementary material, Video S4, and S5).

CC after TAVR represents a main issue and unsuccessful CC was reported in up to 7.7% of patients after TAVR [1]. The initial orientation of some transcatheter heart valves (THV) such as Evolut in some configurations improved the commissural alignment and reduced the risk of coronary artery overlap [2]. Recently, a study reported that patients with misaligned supra-annular THV, low sinus of Valsalva, and higher THV-sinus of Valsalva relation are at the highest risk of impaired CC after TAVR [3]. Although the use of GCE has been recently described after TAVR in a small case series [4], a lack of standardization in the use of GCE is a common problem for operators. In this case, the combined use of a flying wire advancement and the distal anchor-GCE sliding technique may have had a key role in facilitating both CC and PCI equipment delivery.

Supplementary material

Supplementary material is available at https://journals.viamedica.pl/kardiologia_polska.

Article information

Conflict of interest: None declared.

Funding: None.

Open access: This article is available in open access under Creative Commons Attribution-Non-Commercial-No Derivatives 4.0 International (CC BY-NC-ND 4.0) license, which allows downloading and sharing articles with others as long as they credit the authors and the publisher, but without permission to change them in any way or use them commercially. For commercial use, please contact the journal office at kardiologiapolska@ptkardio.pl.

REFERENCES

1. Barbanti M, Costa G, Picci A, et al. Coronary cannulation after transcatheter aortic valve replacement: the RE-ACCESS study. *JACC Cardiovasc Interv.* 2020; 13(21): 2542–2555, doi: [10.1016/j.jcin.2020.07.006](https://doi.org/10.1016/j.jcin.2020.07.006), indexed in Pubmed: [33069648](https://pubmed.ncbi.nlm.nih.gov/33069648/).
2. Tang GHL, Zaid S, Fuchs A, et al. Alignment of Transcatheter Aortic-Valve Neo-Commissures (ALIGN TAVR): Impact on Final Valve Orientation and Coronary Artery Overlap. *JACC Cardiovasc Interv.* 2020; 13(9): 1030–1042, doi: [10.1016/j.jcin.2020.02.005](https://doi.org/10.1016/j.jcin.2020.02.005), indexed in Pubmed: [32192985](https://pubmed.ncbi.nlm.nih.gov/32192985/).
3. Tarantini G, Nai Fovino L, Scotti A, et al. Coronary access after transcatheter aortic valve replacement with commissural alignment: the ALIGN-ACCESS study. *Circ Cardiovasc Interv.* 2022; 15(2): e011045, doi: [10.1161/CIRCINTERVENTIONS.121.011045](https://doi.org/10.1161/CIRCINTERVENTIONS.121.011045), indexed in Pubmed: [35167332](https://pubmed.ncbi.nlm.nih.gov/35167332/).
4. Bharadwaj AS, Bhatheja S, Sharma SK, et al. Utility of the guideliner catheter for percutaneous coronary interventions in patients with prior transcatheter aortic valve replacement. *Catheter Cardiovasc Interv.* 2018; 91(2): 271–276, doi: [10.1002/ccd.27211](https://doi.org/10.1002/ccd.27211), indexed in Pubmed: [28795527](https://pubmed.ncbi.nlm.nih.gov/28795527/).