

# Orbital atherectomy for heavily calcified coronary lesions in a patient with heart failure and severely impaired left ventricular ejection fraction

Mateusz Tajstra, Krzysztof Wilczek, Łukasz Pyka, Mariusz Gąsior

3<sup>rd</sup> Department of Cardiology, Medical University of Silesia in Katowice, Silesian Center for Heart Diseases, Zabrze, Poland

## Correspondence to:

Mateusz Tajstra, MD, PhD,  
3<sup>rd</sup> Department of Cardiology,  
Medical University of Silesia  
in Katowice,  
Silesian Center for Heart Diseases,  
Szpitalna 2,  
41–800 Zabrze, Poland,  
phone: +48 32 373 36 74,  
e-mail: mateusztajstra@wp.pl

Copyright by the Author(s), 2023

DOI: 10.33963/KPa2022.0292

## Received:

July 6, 2022

## Accepted:

October 21, 2022

## Early publication date:

December 12, 2022

Percutaneous coronary interventions (PCI) of calcified lesions strongly and independently affect early angiographic and long-term clinical outcomes [1, 2]. Currently, the Diamondback 360 Coronary Orbital Atherectomy (COA) System (Cardiovascular Systems) is one of the few tools allowing optimal immediate and long-term PCI outcomes. Although the safety and efficacy of COA in PCI have been reported earlier, current evidence on its use in patients with severely impaired left ventricular ejection fraction (LVEF) is limited [3, 4]. Moreover, a recently published case study showed effectiveness and safety of rotational atherectomy in high-risk PCI patients with low LVEF [5]. This report describes PCI with COA in a patient with heart failure (HF) and severely impaired LVEF.

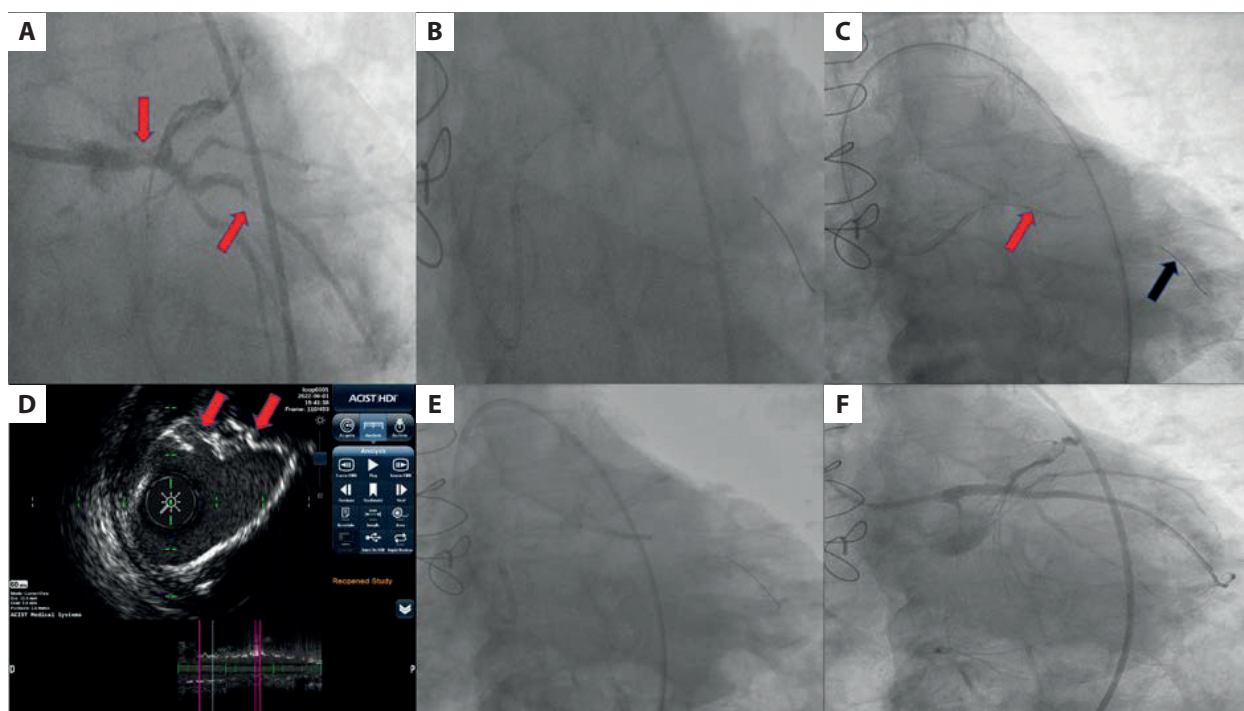
A 72-year-old male with arterial hypertension and hyperlipidemia after an anterior ST-segment elevation myocardial infarction (2011) was diagnosed in March 2022 with multivessel coronary artery disease. He underwent surgical revascularization in April 2022 with the use of left internal mammary artery to left anterior descending coronary artery (LIMA-LAD) graft, with no possibility to sew grafts in the severely calcified strong obtuse marginal 2 (OM 2) and a chronically occluded right coronary artery. The patient was admitted to our center for elective PCI of the left main and OM 2. On admission, the patient presented with stable coronary syndrome — in Canadian Cardiovascular Society class II and stable HF, in New York Heart Association class II. LVEF was 22% with anterior wall akinesia and inferior wall hypokinesia. Coronary angiography showed good LIMA-LAD graft function, with collaterals to the right coronary artery and

significant calcified narrowing of the distal left main, ostial circumflex, and OM 2 (Figure 1A; Supplementary material, Video S1)

The left coronary artery was engaged via the femoral approach with a 45 cm armored arterial sheath and intubated with a 7 F extra-backup 3.75 guiding catheter. A ViperWire Advance guidewire was introduced to the distal part of the OM 2. The intravascular ultrasound probe did not pass through the target lesion (Figure 1B). Coronary orbital atherectomy using Diamondback 360™ with Classic Crown 1.25 mm (Figure 1C, Supplementary material, Video S2) with five runs was performed, without any hemodynamic, rhythm, or conduction disturbances. Intravascular ultrasonography after COA showed calcium fractures (Figure 1D).

A pre-dilatation using non-compliant balloons and a guide extension catheter (Figure 1E) followed by implantation of two drug-eluting stents produced excellent angiographic outcomes (Figure 1F; Supplementary material, Video S3). Final intravascular ultrasound imaging confirmed good apposition/expansion of the implanted stents without any complications (Supplementary material, Video S4). Due to a slow flow in the small OM 1 and distal circumflex arteries, a glycoprotein IIb/IIIa blocker (eptifibatide) was administered. One hour later after the procedure, an episode of ventricular fibrillation successfully defibrillated was recorded. Thereafter, no chest pain or new electrocardiogram changes were observed. The patient was discharged home eight days later.

Orbital atherectomy appears to be safe and effective in patients with HF and severely impaired LVEF.



**Figure 1.** **A.** Initial coronary angiography with severely calcified lesions in the left main and obtuse marginal 2 arteries (red arrows). **B.** An unsuccessful attempt to pass the intravascular ultrasound probe through the lesion. **C.** Coronary orbital atherectomy using Diamondback 360™ with Classic Crown 1.25 mm (Cardiovascular Systems) (Corona Crown — red arrow, ViperWire Advance™ Coronary Guide Wire — black arrow). **D.** Intravascular ultrasonography using an ACIST High Definition Catheter after coronary orbital atherectomy (calcium fractures — red arrows). **E.** Post-dilatation using a non-compliant balloon and guide extension (GuideLiner V3). **F.** Final angiographic result

### Supplementary material

Supplementary material is available at [https://journals.viamedica.pl/kardiologia\\_polska](https://journals.viamedica.pl/kardiologia_polska)

### Article information

**Conflict of interest:** None declared.

**Funding:** None.

**Open access:** This article is available in open access under Creative Commons Attribution-Non-Commercial-No Derivatives 4.0 International (CC BY-NC-ND 4.0) license, which allows downloading and sharing articles with others as long as they credit the authors and the publisher, but without permission to change them in any way or use them commercially. For commercial use, please contact the journal office at [kardiologiapolska@ptkardio.pl](mailto:kardiologiapolska@ptkardio.pl).

### REFERENCES

1. Génèreux P, Madhavan MV, Mintz GS, et al. Ischemic outcomes after coronary intervention of calcified vessels in acute coronary syndromes. Pooled analysis from the HORIZONS-AMI (Harmonizing Outcomes With Revascularization and Stents in Acute Myocardial Infarction) and ACUITY (Acute Catheterization and Urgent Intervention Triage Strategy) TRIALS. *J Am Coll Cardiol.* 2014; 63(18): 1845–1854, doi: 10.1016/j.jacc.2014.01.034, indexed in Pubmed: 24561145.
2. Génèreux P, Redfors B, Witzenbichler B, et al. Two-year outcomes after percutaneous coronary intervention of calcified lesions with drug-eluting stents. *Int J Cardiol.* 2017; 231: 61–67, doi: 10.1016/j.ijcard.2016.12.150, indexed in Pubmed: 28040289.
3. Chambers JW, Feldman RL, Himmelstein SI, et al. Pivotal trial to evaluate the safety and efficacy of the orbital atherectomy system in treating de novo, severely calcified coronary lesions (ORBIT II). *JACC Cardiovasc Interv.* 2014; 7(5): 510–518, doi: 10.1016/j.jcin.2014.01.158, indexed in Pubmed: 24852804.
4. Lee MS, Shlofmitz E, Kaplan B, et al. Real-world multicenter registry of patients with severe coronary artery calcification undergoing orbital atherectomy. *J Interv Cardiol.* 2016; 29(4): 357–362, doi: 10.1111/joic.12310, indexed in Pubmed: 27358246.
5. Pawlik A, Januszek R, Rzeszutko Ł, et al. High-risk percutaneous coronary angioplasty with rotational atherectomy and left ventricular assist device of chronically occluded left ascending artery in an obese patient with very low ejection fraction. *Kardiol Pol.* 2022; 80(4): 491–492, doi: 10.33963/KP.a2022.0034, indexed in Pubmed: 35113999.