



## Hybrid percutaneous atrial septal defect closure with surgical occluder fixation

**Authors:** Roman Przybylski, Jędrzej Reczuch, Maciej Bochenek, Tomasz Witkowski, Krzysztof Reczuch, Wiktor Kuliczkowski

**Article type:** Clinical vignette

**Received:** April 28, 2021

**Accepted:** July 26, 2021

**Published online:** July 28, 2021

This article is available in open access under Creative Common Attribution-Non-Commercial-No Derivatives 4.0 International (CC BY-NC-ND 4.0) license, allowing to download articles and share them with others as long as they credit the authors and the publisher, but without permission to change them in any way or use them commercially.

## Hybrid percutaneous atrial septal defect closure with surgical occluder fixation

Roman Przybylski<sup>1</sup>, Jędrzej Reczuch<sup>2</sup>, Maciej Bochenek<sup>1</sup>, Tomasz Witkowski<sup>2, 3</sup>, Krzysztof Reczuch<sup>2, 4</sup>, Wiktor Kuliczkowski<sup>2, 3</sup>

<sup>1</sup>Clinic of Cardiac Transplantation and Mechanical Circulatory Support, Wrocław Medical University, Wrocław, Poland

<sup>2</sup>Department of Heart Diseases, University Hospital, Wrocław, Poland

<sup>3</sup>Department of Cardiology, Wrocław Medical University, Wrocław, Poland

<sup>4</sup>Department of Heart Diseases, Wrocław Medical University, Wrocław, Poland

**Short title:** Hybrid percutaneous ASD closure

**Conflict of interest:** None declared.

### Corresponding author:

Jędrzej Reczuch, MD,

Department of Heart Diseases, University Hospital,

Borowska 213, 55–556 Wrocław,

phone: +48 71 736 42 57,

e-mail: jedrzej.reczuch@gmail.com

A 62-year-old woman with a history of dyspnea at ordinary activities was admitted for atrial septal defect (ASD) type 2 treatment. Transthoracic echocardiography revealed diastolic dysfunction of the left ventricle, right heart enlargement, atrial septal aneurysm, and an atrial septal defect with left to right shunt. The Qp:Qs was 1.7. The probability of pulmonary hypertension was moderate. The transesophageal echocardiogram showed a 17 × 10 mm ostium secundum ASD with a left to right shunt, an atrial septal aneurysm protruding into the right atrium, deficiency of superior vena cava rim and short aortic rim (Supplementary material, *Video S1* — ASD). The inferior vena cava (IVC) rim was limp. Following the European Society of Cardiology recommendations this morphology is an indication to surgical repair, however due to patient's moderate frailty the Heart Team chose device closure instead, as it seemed technically suitable [1, 2].

The pressures in the right heart were assessed: right ventricle — 27/4 mean 7 mm Hg, pulmonary artery — 18/8 mean 13 mm Hg, mean wedge pressure 8 mm Hg, transpulmonary gradient 5 mm Hg,

cardiac output 5.5 l/min, pulmonary vascular resistance 0.9 Wood units. After the “stop-flow” technique balloon sizing the 20 mm “Cera” occluder was successfully placed. Despite the rim deficiency, the device was stable during the tug test. However, due to an atrial septum aneurysm, the IVC rim was loose providing poor support for the device with a risk of detachment. The device was removed and the concept of hybrid intervention came up.

Under general anesthesia a lateral thoracotomy and an opening of the pericardial sac were performed. The Lifetech Cera 20 mm occluder was delivered through the right femoral vein. Both discs were expanded at optimal positions. Compression of the right atrium wall by forceps localized in transesophageal echocardiography pointed where the suture should be placed. Simultaneously the cardiologist pulled the device to an optimized position for suturing. The right atrial disc was fixated to the limp IVC rim by a single suture placed by the surgeon through the right atrium wall (Supplementary material, *Video S2* — device suturing). A standard tug test was performed (Supplementary material, *Video S3* — tug test). The device had efficient support from the inferior-posterior side. The occluder was then released (Supplementary material, *Video S4* — device detachment from delivery cable). The pericardial sac and the thoracic wall were closed. The patient was extubated the same day. The transthoracic echocardiography performed the next day showed an insignificantly small residual shunt (Supplementary material, *Video S5* — final result). The patient was discharged after 8 days.

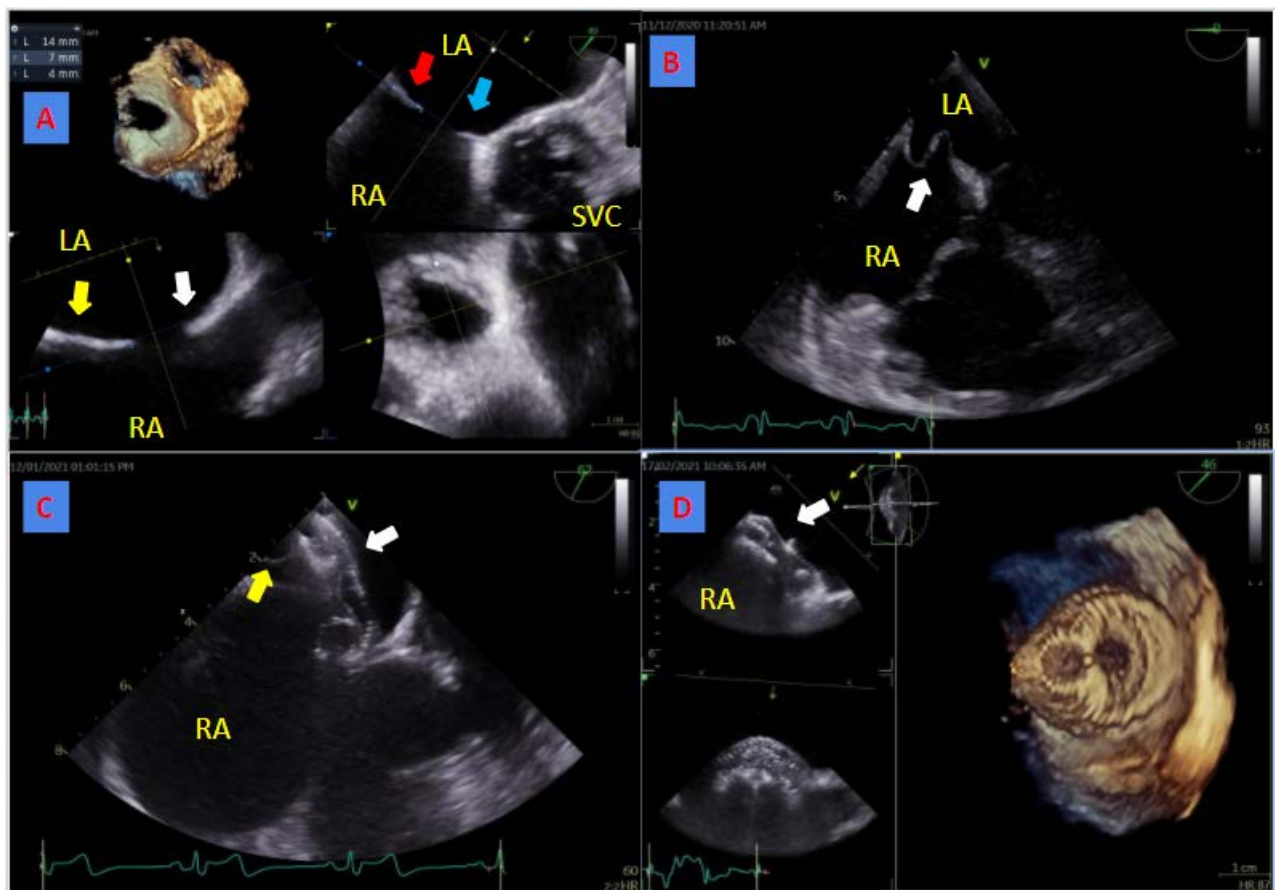
To the best of our knowledge, it was the first case of a hybrid percutaneous ASD closure. This unique approach allowed us to perform device closure in a patient that due to frailty could have had an uncertain clinical course if operated classically. This type of hybrid procedure may prove helpful in future interventions.

### **Acknowledgements**

We thank Mr Przemysław Węglarz for the support given during planning of the procedure.

### **REFERENCES**

1. Baumgartner H, De Backer J, Babu-Narayan S, et al. 2020 ESC Guidelines for the management of adult congenital heart disease. *Eur Heart J.* 2021; 42(6): 563–645, doi: [10.1093/eurheartj/ehaa554](https://doi.org/10.1093/eurheartj/ehaa554), indexed in Pubmed: [32860028](https://pubmed.ncbi.nlm.nih.gov/32860028/).
2. Grygier M, Sabiniewicz R, Smolka G, et al. Percutaneous closure of atrial septal defect: a consensus document of the joint group of experts from the Association of Cardiovascular



**Figure 1.** **A.** The 3D reconstruction of interatrial septum with atrial septal defect type II localized in the superior and anterior aspect of the septum. The postero-superior rim (superior vena cava rim) is absent (white arrow), the postero-inferior rim is 14 mm (yellow arrow), the posterior rim is 7 mm (red arrow), the antero-superior rim (aortic rim) is minimal (blue arrow — 4 mm). The shape of the ASD is elliptical with diameters of 10 and 17 mm respectively. **B.** Transesophageal echocardiography, midesophageal 4-chamber view. The white arrow points to the interatrial septal aneurysm. **C.** The first attempt for ASD closure. Transesophageal echocardiography, modified mid-esophageal aortic valve view during the push test. The white arrow points to the implanted occluder device, the yellow arrow points to the interatrial septal aneurysm giving poor support to the implanted device. **D.** The hybrid approach. The 3D reconstruction of the implanted Lifetech Cera 20 mm occluder after being successfully secured by a single surgical suture.

Abbreviations: ASD, atrial septal defect