

# Current approach to transfemoral aortic valve replacement

Aktualne postępowanie podczas TAVI z dostępu przezudowego

Paweł Kleczyński, Danuta Sorysz, Łukasz Rzeszutko, Jarosław Trębacz, Marek Tomala, Robert Sobczyński, Maciej Bagiński, Beata Bobrowska, Jerzy Sadowski, Dariusz Dudek

Institute of Cardiology, Jagiellonian University Medical College, Krakow, Poland

## Abstract

We present a case of a 73 year-old male with severe aortic stenosis and high perioperative risk who was considered as a candidate for percutaneous valve treatment. After precise clinical assessment, the subject underwent successful transfemoral aortic valve replacement with a 29 mm device in analgosedation.

**Key words:** aortic stenosis, high perioperative risk, TAVR

Kardiol Pol 2013; 71, 2: 203–204

## CASE REPORT

The patient was a 73 year-old male with severe symptomatic aortic stenosis and symptoms of chronic heart failure (class III according to the New York Heart Association functional classification). The presence of several comorbidities including arterial hypertension, severe chronic obstructive pulmonary disease requiring long-term use of bronchodilators and steroids, and pulmonary hypertension, contributed to the logistic Euroscore I of 13% and Society of Thoracic Surgeons score of 3%. An echocardiographic assessment revealed a preserved left ventricular ejection fraction of 60%; mild hypertrophy of the ventricle walls; tricuspid, severely calcified aortic valve with valvular gradient 86/54 mm Hg and aortic valve area of 0.7 cm<sup>2</sup>. Systolic pressure in the right ventricle was estimated at 60 mm Hg. In transoesophageal echocardiogram, the aortic annulus diameter was 26 mm. Coronary angiography showed a significant stenosis in the mid portion of the left anterior descending artery which was successfully treated with two bare-metal stents (4.0 × 13 mm and 3.5 × 14 mm) through the radial approach. The distance from the aortic annulus to the ostium of the left main coronary artery was estimated at 12 mm. Angiography of iliac and lower limb arteries revealed a diameter of both right and left common femoral artery of 9 mm. The subject was discussed at a Heart Team meeting and scheduled for transcatheter aortic-valve implantation

(TAVI) with recommendation for femoral access and use of 29 mm Edwards Sapien XT prosthesis (Edwards Lifesciences, Irvine, CA, USA).

A TAVI procedure was performed in analgosedation (sulfentanil and propofol intravenous infusion) and under transthoracic echocardiography control. A temporary pacemaker designed for rapid pacing was inserted at right subclavian vein access. A diagnostic 6 French pigtail catheter was introduced to the ascending aorta through the right radial artery for intraprocedural imaging purposes. The right common femoral artery was properly punctured for index procedure. The calcified aortic valve was crossed with the support of a 6 French Amplatz left 1.0 diagnostic catheter. The wire was exchanged for a superstiff one. A 20 F expandable sheath was inserted. Balloon aortic valvuloplasty was performed using a 12 French 25 × 40 mm balloon under pacing at 180 bpm. Afterwards, a successful implantation of a 29 mm Edwards-Sapien XT valve under pacing at 180 bpm was performed (Fig. 1). The duration of the procedure was 120 min. with 0.9 mGy of radiation. The post-procedural transthoracic echocardiogram showed a gradient of 14/8 mm Hg with trivial aortic regurgitation and no paravalvular leaks.

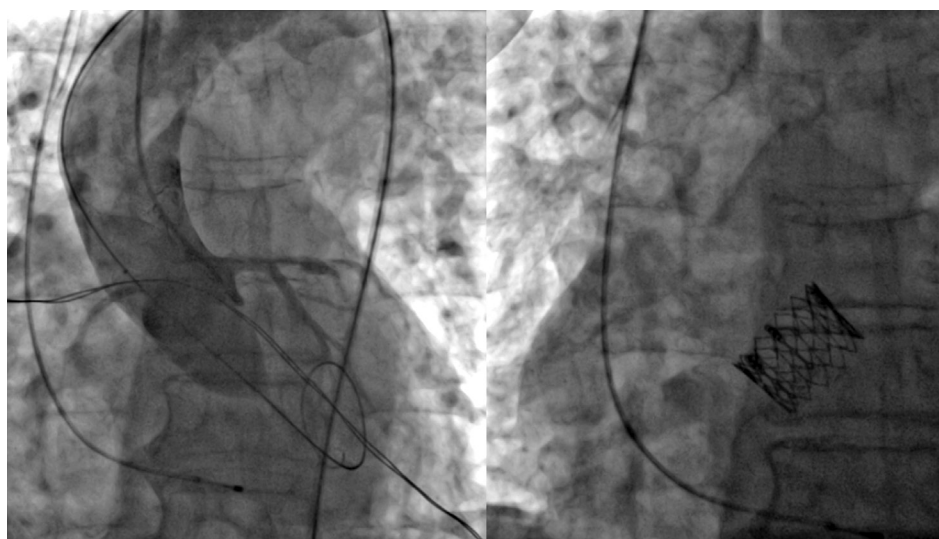
## DISCUSSION

The learning objective of the presented case is to show the possibility of a minimally invasive approach for TAVI in

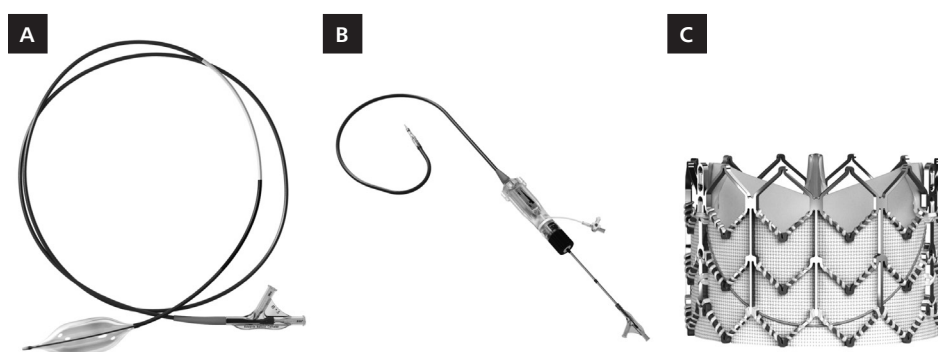
### Address for correspondence:

Paweł Kleczyński, MD, PhD, 2<sup>nd</sup> Department of Cardiology, Institute of Cardiology, ul. Kopernika 17, 31–501 Kraków, Poland, tel: +48 12 424 71 74, e-mail: kleczu@interia.pl

Copyright © Polskie Towarzystwo Kardiologiczne



**Figure 1.** Intraprocedural images: balloon aortic valvuloplasty with 25 × 40 mm balloon and 29 mm Edwards Sapien XT prosthesis after successful deployment



**Figure 2.** New 29 mm device set; **A.** Balloon dedicated to balloon aortic valvuloplasty; **B.** Delivery system of the 29 mm; **C.** Edwards Sapien XT 29 mm

a high-risk subject. The patient was managed with analgo-sedation only to avoid the stress related to general anaesthesia. There was no need for intubation and mechanical ventilation during the procedure. A temporary pacemaker was inserted through the subclavian vein and was kept for 72 h, as is routine in our centre, so the risk of haematoma and threats resulting from immobility were reduced. By puncturing of the radial artery for diagnostic purposes during the procedure, a bleeding complication related to potential femoral access was also avoided. Moreover, in mid-May 2012 a new 29 mm device (Fig. 2), covering the aortic annulus diameter between 25–27 mm, was released by Edwards for general clinical use. The minimal required diameter of common femoral artery is 7.5 mm. The balloon used for balloon aortic valvuloplasty is 25 × 40 mm. The height of the device is 19.1 mm, so the distance between aortic annulus and coronary ostia is crucial.

**Conflict of interest:** none declared

### References

1. Cribier A, Eltchaninoff H, Bash A et al. Percutaneous transcatheter implantation of an aortic valve prosthesis for calcific aortic stenosis: first human case description. *Circulation*, 2002; 106: 3006–3008.
2. Vahanian A, Alferi O, Al-Attar N et al. European Association of Cardio-Thoracic Surgery; European Society of Cardiology; European Association of Percutaneous Cardiovascular Interventions. Transcatheter valve implantation for patients with aortic stenosis: a position statement from the European Association of Cardio-Thoracic Surgery (EACTS) and the European Society of Cardiology (ESC), in collaboration with the European Association of Percutaneous Cardiovascular Interventions (EAPCI). *Eur Heart J*, 2008; 29: 1463–1470.
3. Leon MB, Smith CR, Mack M et al. Transcatheter aortic-valve implantation for aortic stenosis in patients who cannot undergo surgery. *N Engl J Med*, 2010; 363: 1597–1607.
4. Smith CR, Leon MB, Mack MJ et al. Transcatheter versus surgical aortic-valve replacement in high-risk patients. *N Engl J Med*, 2011; 364: 2187–2198.