

# Complete transcatheter treatment of multiple heart valve diseases

Łukasz Wiewiórka<sup>1</sup>, Jarosław Trębacz<sup>1</sup>, Andrzej Gackowski<sup>2,3,4</sup>, Robert Sobczyński<sup>5</sup>, Maciej Stąpór<sup>1</sup>, Janusz Konstanty-Kalandyk<sup>3,6</sup>, Paweł Kleczyński<sup>3,7</sup>, Robert Musiał<sup>8</sup>, Bogusław Kapelak<sup>3,6</sup>, Jacek Legutko<sup>3,7</sup>

1 Department of Interventional Cardiology, John Paul II Hospital, Kraków, Poland

2 Department of Coronary Artery Disease and Heart Failure, Institute of Cardiology, Jagiellonian University Medical College, Kraków, Poland

3 John Paul II Hospital, Kraków, Poland

4 Noninvasive Cardiovascular Laboratory, John Paul II Hospital, Kraków, Poland

5 Department of Cardiac Surgery and Transplantation, John Paul II Hospital, Kraków, Poland

6 Department of Cardiac Surgery and Transplantation, Institute of Cardiology, Jagiellonian University Medical College, Kraków, Poland

7 Department of Interventional Cardiology, Institute of Cardiology, Jagiellonian University Medical College, Kraków, Poland

8 Department of Anaesthesiology and Intensive Therapy, John Paul II Hospital, Kraków, Poland

Transcatheter heart valve therapies shed new light on effective treatment not only in the elderly but also in patients with concomitant comorbidities such as porcelain aorta or those who have undergone chest radiation therapies and who are not appropriate candidates for surgery.<sup>1</sup> Transcatheter “edge-to-edge” Mitra- and Tri-Clip repair together with transcatheter aortic valve implantation have been described as valuable therapy options for this subset of patients.<sup>2-4</sup>

A 59-year-old man was admitted to our department with acute exacerbation of left and right ventricular heart failure. His medical history included myocardial infarction treated with primary percutaneous coronary intervention of the right coronary artery, chronic kidney disease (stage III), and chemotherapy with subsequent chest radiation therapy due to Hodgkin lymphoma. Blood tests revealed a significantly increased serum N-terminal brain natriuretic peptide level of 7232 pg/ml (reference range <125 pg/ml). Echocardiography showed a slightly decreased left ventricular ejection fraction (48%), severe aortic stenosis (aortic valve area, 0.9 cm<sup>2</sup>; V max, 3 m/s; mean pressure gradient, 20 mm Hg), severe mitral regurgitation (MR) type IIIb (based on the Carpentier functional classification) (effective regurgitant orifice, 0.6 cm<sup>2</sup>; regurgitant volume, 90 ml), and severe tricuspid regurgitation (TR) with an estimated right ventricular systolic pressure (RVSP) of 90 mm Hg (FIGURE 1A-1C). Coronary angiography excluded severe coronary

artery disease requiring revascularization. Surgical risk assessed with the logistic EuroScore II was 7.75%, and with the Society of Thoracic Surgeons score, 3.86%. The Heart Team discussed the case and scheduled the patient for transcatheter treatment due to the history of chest radiation therapy. During the index hospital stay, a successful implantation of a self-expandable Portico 29-mm valve (Abbott, Santa Clara, California, United States) was performed. Despite the successful transcatheter aortic valve implantation and optimal medical therapy, the patient still presented with symptoms of class IV heart failure according to the New York Heart Association classification and required invasive ventilation. The control transesophageal echocardiography confirmed severe MR and TR suitable for transcatheter treatment. Four weeks later, under general anesthesia, a MitraClip procedure was performed with 2 NTr clips deployed on the mitral leaflets, and a third clip was implanted on the septal and anterior tricuspid valve leaflet (FIGURE 1D-1E). Echocardiography confirmed good hemodynamic results with moderate MR (MR regurgitant volume, 22 ml; effective regurgitant orifice, 0.15 cm<sup>2</sup>; mean pressure gradient, 8 mm Hg), (FIGURE 1F) and mild TR. Despite a decrease in left ventricular ejection fraction to 40%, a significant increase in stroke volume from 40 ml to 70 ml was observed, with a significant reduction of RVSP to 45 mm Hg. These values confirmed that a successful MitraClip

## Correspondence to:

Łukasz Wiewiórka, MD,  
Department of Interventional  
Cardiology, John Paul II Hospital,  
ul. Prądnicza 80, 31-202 Kraków,  
Poland, phone: +48 12 614 3501,  
email: drlucwie@gmail.com  
Received: December 6, 2020.

## Revision accepted:

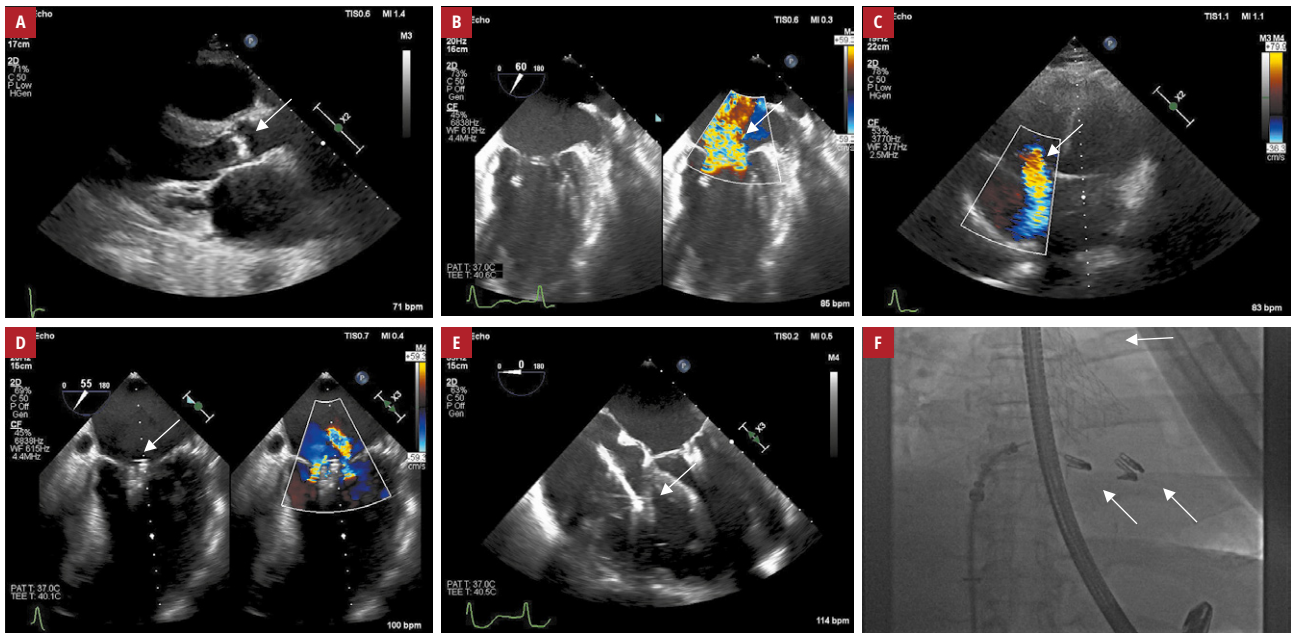
January 26, 2021.

## Published online:

February 8, 2021.

Kardiologia Pol. 2021; 79 (3): 350-351  
doi:10.33963/KP.15799

Copyright by the Author(s), 2021



**FIGURE 1** **A** – transthoracic echocardiography, the parasternal long-axis view, showing severe calcifications of the aortic valve (arrow); **B** – transesophageal echocardiography, the intercommissural view, showing severe functional mitral regurgitation (arrow); **C** – transthoracic echocardiography, the 4-chamber view, showing severe tricuspid regurgitation (arrow); **D** – transesophageal echocardiography, the midesophageal 4-chamber view, showing released clips during tricuspid clip implantation (arrow); **E** – transesophageal echocardiography, the intercommissural view, showing 2 clips implanted at the A2–P2 segments of the mitral valve, mild residual mitral regurgitation (arrow); **F** – fluoroscopy showing 2 implanted MitraClips, a TriClip, and an aortic valve prosthesis (arrows). The transesophageal probe was in the transgastric position.

procedure may lead to RVSP reduction.<sup>5</sup> As a result, significant clinical improvement was achieved, and the patient could be discharged home. During 6-month follow-up, echocardiography confirmed a good result of valve interventions with New York Heart Association class II symptoms.

According to the European Society of Cardiology guidelines, surgical treatment for patients with defects in multiple valves is the optimal choice. However, choosing the optimal method, including transcatheter heart valve intervention, can often be difficult and cannot be based only on classic risk scales, as they do not include clinically essential factors such as chest radiation therapies.

## ARTICLE INFORMATION

**CONFLICT OF INTEREST** None declared.

**OPEN ACCESS** This is an Open Access article distributed under the terms of the Creative Commons Attribution-NonCommercial-NoDerivatives 4.0 International License (CC BY-NC-ND 4.0), allowing third parties to download articles and share them with others, provided the original work is properly cited, not changed in any way, distributed under the same license, and used for non-commercial purposes only. For commercial use, please contact the journal office at [kardiologiapolska@ptkardio.pl](mailto:kardiologiapolska@ptkardio.pl).

**HOW TO CITE** Wiewiórka Ł, Trębacz J, Gackowski A, et al. Complete transcatheter treatment of multiple heart valve diseases. *Kardiol Pol.* 2021; 79: 350-351. doi:10.33963/KP.15799

## REFERENCES

- 1 Baumgartner H, Falk V, Bax JJ, et al. 2017 ESC/EACTS Guidelines for the management of valvular heart disease. *Eur Heart J.* 2017; 38: 2739-2786.
- 2 Parma R, Zembala MO, Dąbrowski M, et al. Transcatheter aortic valve implantation. Expert Consensus of the Association of Cardiovascular Interventions of the Polish Cardiac Society and the Polish Society of Cardio-Thoracic Surgeons,

approved by the Board of the Polish Cardiac Society and National Consultants in Cardiology and Cardiac Surgery. *Kardiol Pol.* 2017; 75: 937-964.

3 Bonow RO, O’Gara PT, Adams DH, et al. Multisociety expert consensus systems of care document 2019 AATS/ACC/SCAI/STS expert consensus systems of care document: operator and institutional recommendations and requirements for transcatheter mitral valve intervention: a Joint Report of the American Association for Thoracic Surgery, the American College of Cardiology, the Society for Cardiovascular Angiography and Interventions, and The Society of Thoracic Surgeons. *Catheter Cardiovasc Interv.* 2020; 95: 866-884.

4 Leon MB, Smith CR, Mack M, et al. Transcatheter Aortic-Valve Implantation for Aortic Stenosis in Patients Who Cannot Undergo Surgery. *N Engl J Med.* 2010; 363: 1597-1607.

5 Banasiak A, Pregowski J, Skowroński J, et al. Normalization of pulmonary hypertension after experimental pulmonary denervation therapy and MitraClip implantation in a patient initially disqualified from heart transplant. *Kardiol Pol.* 2020; 78: 945-946.