

Removal of the left ventricular lead with femoral access

Usunięcie lewej elektrody komorowej z dostępu udowego

Marcin Grabowski¹, Marcin Michalak¹,
Jakub Zawadzki¹, Radosław Wilimski²,
Grzegorz Opolski¹

¹Katedra i Klinika Kardiologii,
Warszawski Uniwersytet Medyczny

²Kliniki Kardiologii i Katedry i Kliniki Kardiologii
Warszawskiego Uniwersytetu Medycznego

ABSTRACT

A 55-year-old man with signs of infectious endocarditis was admitted to the clinic in order to remove the CRT-D system. Due to difficult anatomical conditions and technical limitations, the decision was made to perform two-stage procedure and removal of the left ventricular lead by access from the femoral vein.

Key words: lead extraction, femoral approach, Needle's Eye Snare

Kardiol. Inwazyjna 2017; 12 (3), 9–11

STRESZCZENIE

Mężczyzna, 55-letni, z objawami infekcyjnego zapalenia wsierdza został przyjęty do kliniki w celu usunięcia układu CRT-D. Z uwagi na trudne warunki anatomiczne i ograniczenia techniczne, zdecydowano o przeprowadzeniu zabiegu dwuetapowo i usunięciu lewej elektrody komorowej przez dostęp z żyły udowej.

Słowa kluczowe: usuwanie elektrody, dostęp udowy, Needle's Eye Snare

Kardiol. Inwazyjna 2017; 12 (3), 9–11

Case report

A 55-year-old man was referred to our clinic for extraction of a Cardiac Resynchronization Therapy Defibrillator (CRT-D) because of lead-dependent infective endocarditis. The CRT-D was implanted 7 years earlier in primary prevention due to chronic heart failure with decreased left ventricular ejection fraction (LFEV = 30%). His medical history was positive for myocardial infarction, left bundle branch block, paroxysmal atrial flutter and electrical storm treated with radiofrequency ablation.

The patient was qualified for transvenous lead extraction via left subclavian vein. The procedure was performed in general anaesthesia with on-site cardiac surgery backup. Originally simple traction revealed heavy adhesions in the subclavian region. The locking stylet (Liberator[®] Beacon[®] Tip Locking Stylet, Cook Medical Inc.) along with 10F and 11.5F mechanical telescopic sheaths (Byrd Dilator[®] sheaths, Cook Medical Inc.) were used (Fig. 1). It allowed to remove completely only the right ventricular lead and the left ventricular (LV) lead was disrupted with its tip wedged in the lateral branch of coronary sinus. The atrial lead was extracted with hand-powered sheath (Evolution[®] RL Controlled-Rotation Dilator Sheath Set) (Fig. 2). It was decided to stage the procedure and to continue it with femoral access.

In the second stage, self-locking device station Needle's Eye Snare[®] (Cook Medical Inc.) was introduced to the inferior vena cava through the right femoral vein. The LV lead was grabbed at the level of right atrium and the outer sheath was advanced

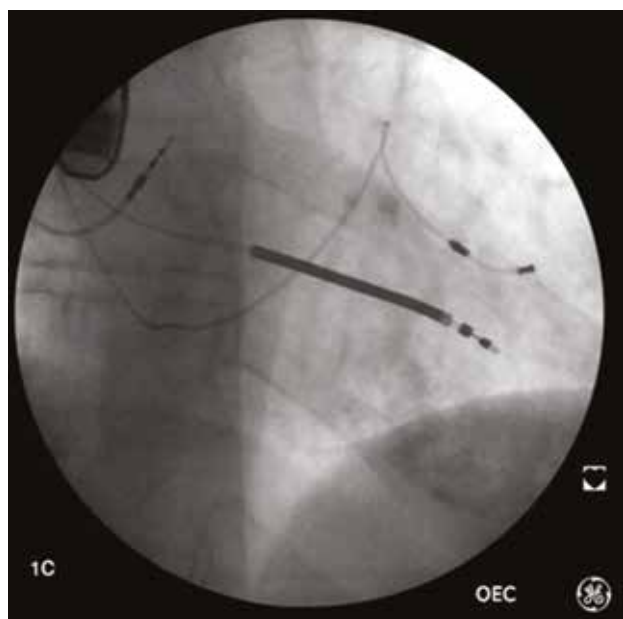


Figure 1. Fluoroscopy before removing the pacing leads and usage of the mechanical telescopic sheaths

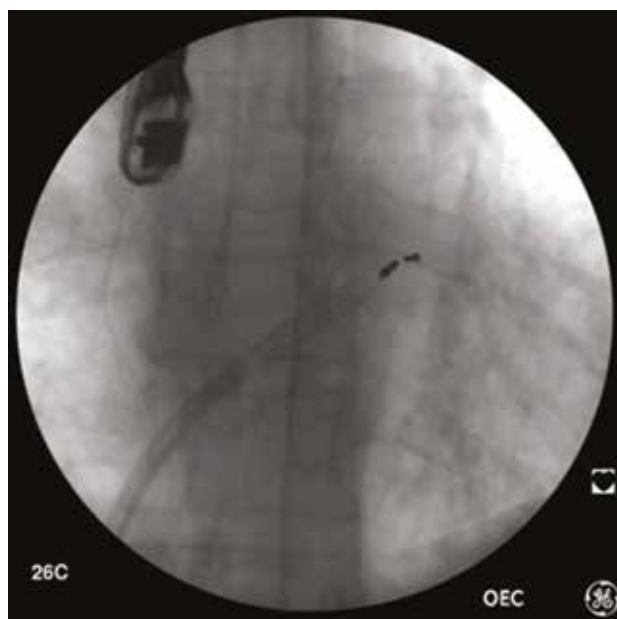


Figure 3. Fluoroscopy showing removal of the last lead from the femoral access

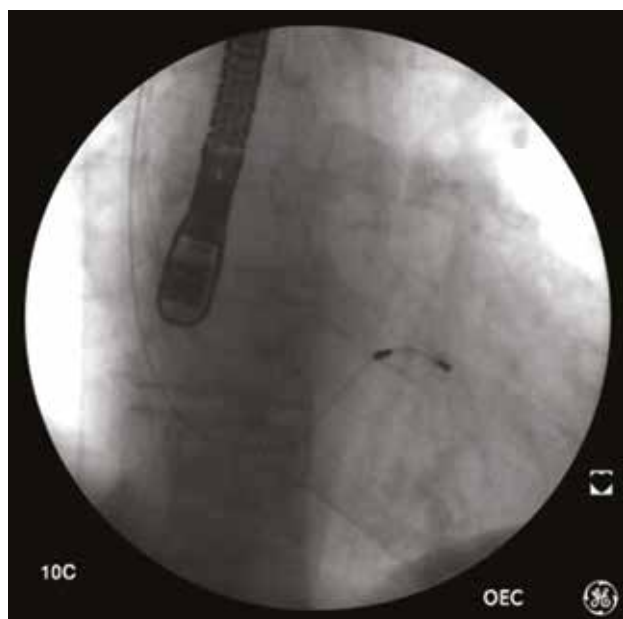

Figure 2. Failed attempt to remove the left ventricular lead via left subclavian vein

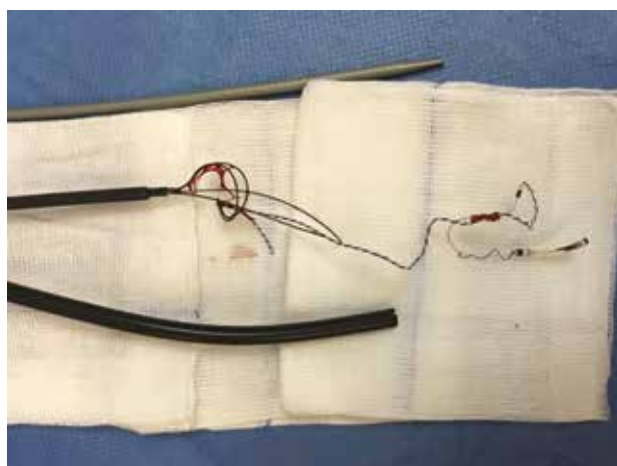


Figure 4. Removed LV lead fragment

over it to the coronary sinus and the tip of the lead have been released (Fig. 3, 4). The procedure was uncomplicated and two days later the patient was transferred to another hospital for further treatment.

Discussion

Infective endocarditis is an uncommon infectious disease with an annual incidence ranging from 3 to 7 per 100 000 person-years in the most contemporary population surveys. Although relatively rare, it continues to be characterized by increased morbidity and mortality and is now the third or fourth most common life-threatening infection syndrome [1]. A population-based study found an incidence of cardiac device-related endocarditis infection of

1.9 per 1000 device-years [2]. Currently, two-thirds of all extractions are due to cardiovascular device-related infection [3].

Considering the inherent risk of an open surgical procedure, transvenous lead extraction has become the preferred method in centres committed to a procedural volume. However, unlike our case, typically it is considered that removal of the CS lead is easier than cardioverter-defibrillator leads and usually it requires only simple manual traction [2].

There are described case reports about the femoral vein approach, for the extraction of the pacemaker lead by using a snare [4, 5]. In the present case, as is rarely in literature, the femoral access was used to remove the coronary sinus lead. However, Bongiorno et al. described the use of a similar technique for dozen patients: in case of free-floating leads with free tips (leads migrated into the venous system) an analogous to our tool was used to grasp the lead.

Once the lead was grabbed, it was pulled back into the workstation and removed; in case of adherences, dilatation was performed using the workstation [6].

References

1. Baddour L, Wilson W, Bayer A, et al. Infective Endocarditis in Adults: Diagnosis, Antimicrobial Therapy, and Management of Complications. *Circulation*. 2015; 132(15): 1435–1486, doi: [10.1161/cir.0000000000000296](https://doi.org/10.1161/cir.0000000000000296).
2. Habib G, Lancellotti P, Antunes MJ, et al. Document Reviewers. 2015 ESC Guidelines for the management of infective endocarditis: The Task Force for the Management of Infective Endocarditis of the European Society of Cardiology (ESC). Endorsed by: European Association for Cardio-Thoracic Surgery (EACTS), the European Association of Nuclear Medicine (EANM). *Eur Heart J*. 2015; 36(44): 3075–3128, doi: [10.1093/eurheartj/ehv319](https://doi.org/10.1093/eurheartj/ehv319), indexed in Pubmed: [26320109](https://pubmed.ncbi.nlm.nih.gov/26320109/).
3. Di Monaco A, Pelargonio G, Narducci ML, et al. Safety of transvenous lead extraction according to centre volume: a systematic review and meta-analysis. *Europace*. 2014; 16(10): 1496–1507, doi: [10.1093/europace/euu137](https://doi.org/10.1093/europace/euu137), indexed in Pubmed: [24965015](https://pubmed.ncbi.nlm.nih.gov/24965015/).
4. Starck CT, Caliskan E, Klein H, et al. Impact of a femoral snare approach as a bailout procedure on success rates in lead extractions. *Interact Cardiovasc Thorac Surg*. 2014; 18(5): 551–555, doi: [10.1093/icvts/ivu005](https://doi.org/10.1093/icvts/ivu005), indexed in Pubmed: [24535091](https://pubmed.ncbi.nlm.nih.gov/24535091/).
5. Zencir C, Selvi M, Elbi H, et al. Removal of the broken part of implantable cardioverter-defibrillator's electrode causing pulmonary embolism via femoral vein. *Indian Heart J*. 2015; 67 Suppl 3: S88.e1–S88.e4, doi: [10.1016/j.ihj.2015.06.004](https://doi.org/10.1016/j.ihj.2015.06.004), indexed in Pubmed: [26995444](https://pubmed.ncbi.nlm.nih.gov/26995444/).
6. Bongiorni MG, Soldati E, Zucchelli G, et al. Transvenous removal of pacing and implantable cardiac defibrillating leads using single sheath mechanical dilatation and multiple venous approaches: high success rate and safety in more than 2000 leads. *Eur Heart J*. 2008; 29(23): 2886–2893, doi: [10.1093/eurheartj/ehn461](https://doi.org/10.1093/eurheartj/ehn461), indexed in Pubmed: [18948356](https://pubmed.ncbi.nlm.nih.gov/18948356/).

Adres do korespondencji:

Lek. Jakub Zawadzki
I Katedra i Klinika Kardiologii, Warszawski Uniwersytet Medyczny
ul. Banacha 1a, 02-097 Warszawa
tel.: 510-358-733
e-mail: zawadzki.jakub@o2.pl