

Cervical molar pregnancy, profuse bleeding and urgent surgical treatment

Predrag Vukomanovic^{1, 2}, Ranko Kutlesic^{1, 2}, Jelena Milosevic Stevanovic^{1, 2}, Ivana Djordjevic^{2, 3}, Milan Stefanovic^{1, 2}

¹Department of Gynecology and Obstetrics, Faculty of Medicine, University of Nis, Serbia

²Clinic of Gynecology and Obstetrics, University Clinical Center Nis, Serbia

³Department of Pathology, Faculty of Medicine, University of Nis, Serbia

INTRODUCTION

Cervical ectopic pregnancy is the implantation of pregnancy in the endocervical canal. Cervical pregnancy is rare, but often associated with significant morbidity. Gestational trophoblastic disease (GTD) is a disorder of accelerated trophoblastic proliferation. The incidence of hydatidiform mole is one per 1.000 pregnancies [1].

The association of cervical pregnancy and GTD is extreme rare, but it is obvious that such combination is associated with devastating effects on future fertility as well as substantial challenges in the treatment.

CASE PRESENTATION

Patient, 35 years, parity 2 (caesarean deliveries), was admitted to our Clinic due to massive uterine bleeding at 7th gestational week. The pregnancy was uneventful till then, except nausea. On admission, she was pale, her blood pressure was 70/30 mm Hg, pulse was 98/min, filiform. On speculum examination, cervix was enlarged, with uterine bleeding. Bimanual examination revealed bulky cervix with small and soft uterine body. Transvaginal ultrasound examination revealed uterus with empty uterine cavity and bulky cervix with complex heteroechogenic formation with prominent peripheral hypervascularity on color Doppler ultrasound examination. Both ovaries appeared with no pathological structures. Her hemoglobin was 6.4 g/dL and beta-HCG was 29655 mIU/mL.

Patient was informed and due to haemodynamic instability and vital endangerment of the patient, a decision was made to perform the surgery. Slightly enlarged uterine corpus, with bulky cervix and normal adnexa were found on laparotomy (Fig. 1A and B). Total abdominal hysterectomy with the conservation of one ovary was performed. Pathohistological examination confirmed cervical molar pregnancy (Fig. 1C).

DISCUSSION

Known risk factors for cervical pregnancy were not present in our patient. She had two caesarean deliveries in her medical history, no dilatation and curettage, no anatomic abnormalities and fibroids. We speculate that inappropriate healing of caesarean scar could change the uterine motility resulting in cervical implantation of an early embryo.

Ectopic GTD is a rare condition, with incidence of approximately 1.5 per 1.000.000 births [2, 3]. Cervical GTD is an extremely rare, but potentially fatal condition. Our own review of the literature (Medline data base, through electronic searches by keywords without language restriction) showed a total of six reported cases of cervical molar pregnancies worldwide during the last 61 years [4–9]. Four of them were treated conservatively (surgery evacuation followed by arterial ligation or haemostatic sutures) [4–7] and in two cases hysterectomy was performed [8, 9].

The management of ectopic molar pregnancies consists of complete removing of the conceptus [10]. In the case of our patient with cervical molar pregnancy, the urgency of the condition didn't allow the use of methotrexate. The decision

Corresponding author:

Jelena Milosevic Stevanovic

Department of Gynecology and Obstetrics, Faculty of Medicine, University of Nis, 81 Dr Zoran Djindjic Blvd, 18000 Nis, Serbia

e-mail: jelamilostev@gmail.com

Received: 12.02.2022 Accepted: 28.03.2022 Early publication date: 22.04.2022

This article is available in open access under Creative Commons Attribution-Non-Commercial-No Derivatives 4.0 International (CC BY-NC-ND 4.0) license, allowing to download articles and share them with others as long as they credit the authors and the publisher, but without permission to change them in any way or use them commercially.

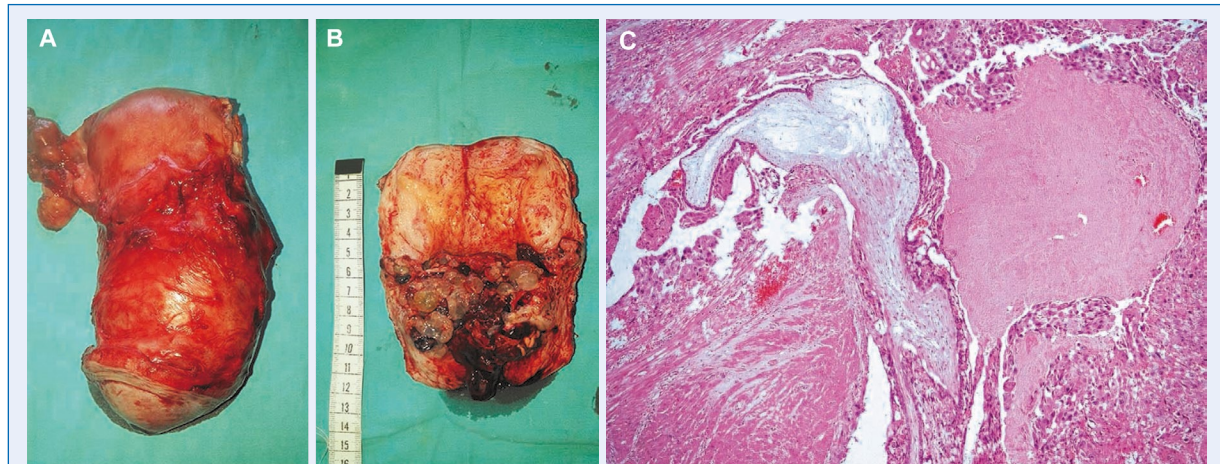


Figure 1. **A.** Uterus and right adnexa after hysterectomy; **B.** Uterus in cross section. Small uterine body with bulky cervix containing molar pregnancy; **C.** Histopathology: hydropically enlarged edematous placental villus with central cistern and circumferential trophoblastic hyperplasia is present within cervical stroma (HE, x 40)

to perform the total abdominal hysterectomy was made as a desperate measure and due to vital indications. Data from available literature, as well as previous experiences in the treatment of cervical-molar pregnancy are very scarce and do not provide a clearly defined algorithm of behavior in such extremely serious situation.

If it is about an ectopic, molar or ectopic molar pregnancy, just an early visit to gynecologist would give the opportunity to plan further treatment, especially the possibilities of conservative treatment to preserve the uterus for further pregnancies.

Conflict of interest

All authors declare no conflict of interest.

REFERENCES

- Lund H, Vyberg M, Eriksen HH, et al. Decreasing incidence of registered hydatidiform moles in Denmark 1999-2014. *Sci Rep.* 2020; 10(1): 17041, doi: [10.1038/s41598-020-73921-4](https://doi.org/10.1038/s41598-020-73921-4), indexed in Pubmed: [33046739](https://pubmed.ncbi.nlm.nih.gov/33046739/).
- Gillespie AM, Lidbury EA, Tidy JA, et al. The clinical presentation, treatment, and outcome of patients diagnosed with possible ectopic molar gestation. *Int J Gynecol Cancer.* 2004; 14(2): 366–369, doi: [10.1111/j.1048-891X.2004.014223.x](https://doi.org/10.1111/j.1048-891X.2004.014223.x), indexed in Pubmed: [15086739](https://pubmed.ncbi.nlm.nih.gov/15086739/).
- Hwang JHa, Lee JK, Lee NW, et al. Molar ectopic pregnancy in the uterine cornus. *J Minim Invasive Gynecol.* 2010; 17(2): 239–241, doi: [10.1016/j.jmig.2009.11.010](https://doi.org/10.1016/j.jmig.2009.11.010), indexed in Pubmed: [20226416](https://pubmed.ncbi.nlm.nih.gov/20226416/).
- Aytan H, Caliskan AC, Demirturk F, et al. Cervical partial hydatidiform molar pregnancy. *Gynecol Obstet Invest.* 2008; 66(2): 142–144, doi: [10.1159/000141647](https://doi.org/10.1159/000141647), indexed in Pubmed: [18583920](https://pubmed.ncbi.nlm.nih.gov/18583920/).
- Winata IS, Kusuardiyanto P, Aryana M, et al. Cervical hydatidiform moles pregnancy: diagnosis and treatment. *Open Access Macedonian Journal of Medical Sciences.* 2021; 9(C): 291–296, doi: [10.3889/oamjms.2021.7562](https://doi.org/10.3889/oamjms.2021.7562).
- Miciński J, Wiczorek M, Mercik R. Zaśniad groniasty we wczesnej ciąży szyjkowej wyleczony zachowawczo [Hydatidiform mole in early cervical pregnancy treated conservatively]. *Wiad Lek.* 1970; 23(8): 673–676, indexed in Pubmed: [5466040](https://pubmed.ncbi.nlm.nih.gov/5466040/).
- Beless DJ. Cervical hydatidiform mole causing severe vaginal hemorrhage: a case report. *J Reprod Med.* 1995; 40(12): 855–858, indexed in Pubmed: [8926616](https://pubmed.ncbi.nlm.nih.gov/8926616/).
- Schwentner L, Schmitt W, Bartusek G, et al. Cervical hydatidiform mole pregnancy after missed abortion presenting with severe vaginal bleeding: case report and review of the literature. *Eur J Obstet Gynecol Reprod Biol.* 2011; 156(1): 9–11, doi: [10.1016/j.ejogrb.2010.12.029](https://doi.org/10.1016/j.ejogrb.2010.12.029), indexed in Pubmed: [21272989](https://pubmed.ncbi.nlm.nih.gov/21272989/).
- Kusovac V. Cerviksna trudnoća, mola i pocetni horionepiteliom [Cervical pregnancy, mole and initial chorioepithelioma]. *Srp Arh Celok Lek.* 1972; 100(3): 429–434, indexed in Pubmed: [5048039](https://pubmed.ncbi.nlm.nih.gov/5048039/).
- Kirk E, Condous G, Haider Z, et al. The conservative management of cervical ectopic pregnancies. *Ultrasound Obstet Gynecol.* 2006; 27(4): 430–437, doi: [10.1002/uog.2693](https://doi.org/10.1002/uog.2693), indexed in Pubmed: [16514619](https://pubmed.ncbi.nlm.nih.gov/16514619/).