

The potential role of preoperative cystoscopy for determining the depth of invasion in the placenta accreta spectrum

Furkan Çetin^{1, 2}, Seyhun Sucu², Hüseyin Çağlayan Özcan², Özge Kömürçü Karuserci², Çağdaş Demiroğlu³, Muhammed Hanifi Bademkiran², Emin Sevinçler²

¹Department of Obstetrics and Gynecology, Dr Ersin Arslan Education and Research Hospital, Gaziantep, Turkey

²Department of Obstetrics and Gynecology, Faculty of Medicine, Gaziantep University, Gaziantep, Turkey

³Department of Obstetrics and Gynecology, Faculty of Medicine, SANKO University, Gaziantep, Turkey

ABSTRACT

Objectives: This study aims to determine the role of preoperative cystoscopy in specifying the degree of placental invasion to the bladder in the placenta accreta spectrum (PAS), especially in percreta.

Material and methods: This prospective observational cohort study included 78 PAS patients. All included patients underwent the preoperative cystoscopy before the cesarean hysterectomy operation. The preoperative cystoscopy procedure identified markers of PAS as neovascularization, arterial pulsatility in neovascularized zones, and posterior bladder wall bulging. Then the patients were divided into subgroups according to the histopathological results of their cesarean hysterectomy specimens. Finally, the histopathological subgroups of PAS were estimated using preoperative cystoscopy signs in the designed logistic regression analysis model.

Results: The preoperative cystoscopic signs such as neovascularization, the posterior bladder wall bulging, and the arterial pulsatility in neovascularized zones were approximately associated with a 17-fold [OR = 16.9 (95% CI, 5.7–49.8)], 26-fold [OR = 26.1 (95% CI, 8.17–83.8)], and 9-fold [OR = 8.94 (95% CI, 2.94–27.1)] increase in the likelihood of placenta percreta, respectively.

Conclusions: Preoperative cystoscopy may significantly contribute to other standard imaging modalities to identify the degree of placental invasion, especially placenta percreta. Experienced obstetricians trained in hysteroscopic visualization may safely perform this preoperative cystoscopy procedure under the guidance of a specialist urologist. Accordingly, it may be possible to estimate the degree of invasion and the course of surgery in patients with PAS using the preoperative cystoscopy procedure.

Key words: cesarean hysterectomy; cystoscopy; placenta accreta; placenta accreta spectrum; placenta increta; placenta percreta

Ginekologia Polska 2023; 94, 3: 242–248

INTRODUCTION

Placenta accreta spectrum (PAS) has emerged as one of the most important causes of massive obstetric hemorrhages in recent years [1, 2]. This spectrum is defined as a pathological placentation state in which villous tissue invades the uterine wall. There are three subtypes of PAS: (a) placenta accreta (chorionic villi in contact with

myometrium), (b) placenta increta (chorionic villi invade the myometrium), and (c) placenta percreta (chorionic villi extend up to the uterine serosa, and sometimes invade the pelvic organs) [3, 4]. The PAS incidence increases in parallel with the increasing cesarean rates worldwide and varies between 1/533 and 1/2500 [5]. There may be potential challenges regarding estimating and diagnosing the degree

Corresponding author:

Furkan Çetin

Department of Obstetrics and Gynecology, Dr Ersin Arslan Education and Research Hospital, Gaziantep, Turkey
e-mail furkan.cetin01@gmail.com

Received: 25.11.2022 Accepted: 6.02.2023 Early publication date: 20.02.2023

This article is available in open access under Creative Commons Attribution-Non-Commercial-No Derivatives 4.0 International (CC BY-NC-ND 4.0) license, allowing to download articles and share them with others as long as they credit the authors and the publisher, but without permission to change them in any way or use them commercially.

of placental invasion preoperatively. The most preferred method for evaluating placental invasion is transvaginal or abdominal ultrasonography (USG) [6]. Magnetic resonance imaging (MRI) for PAS diagnosis may be used as an additional component to increase the diagnostic accuracy of USG, especially for unclear USG signs or the posteriorly located placenta. The disadvantages of MRI in PAS diagnosis are that it requires experience for accurate examination and is not cost-effective compared to USG [7]. On the other hand, placental invasion can usually be diagnosed preoperatively by USG or MRI [8], but the actual depth of placental invasion may be different compared to its preoperative diagnosis, especially by USG.

Considering the structures adjacent to the uterus, placental invasion most commonly affects the urinary organs, less frequently the rectum. The rate of urinary tract damage during surgery can reach up to 30%, and the most damaged urinary organ is the bladder [9]. Specifying the degree of placental invasion and taking appropriate precautions in the prenatal period is very crucial for the intraoperative management of PAS [10, 11]. Although the invasion depth of PAS may be predicted approximately by the preoperative USG, MRI, or cystoscopy [12, 13], the knowledge in terms of cystoscopy is particularly limited in previous studies.

Objectives

The present study aims to determine the role of cystoscopy in specifying the degree of placental invasion of the bladder in PAS, especially in percreta. Since the number of PAS patients is largest and the cystoscopy procedure is designed preoperatively, our study on this issue has a potentially new perspective.

MATERIAL AND METHODS

This prospective interventional cohort study was performed at the Department of Obstetrics and Gynecology of Sahinbey Research and Practice Hospital which belongs to the Faculty of Medicine of Gaziantep University, Gaziantep, Turkey. The study was approved by the Gaziantep University Ethics Committee (Date: 09 January 2019, Ethics committee number: 2018/259) and informed consent was obtained from patients. Informed consent included the information in detail regarding preoperative cystoscopy, cesarean hysterectomy method, and possible complications. This current study was carried out together with the ethical standards of the Declaration of Helsinki guidelines. Patient information has been stored in the hospital's highly secure digital data recording system. The patients' demographic characteristics, pre- and postoperative hemoglobin levels, data on blood loss, amount of blood transfusions, period of operation and hospitalization, complications, and cystoscopy signs were recorded and analyzed.

Patient selection criteria, Pre-operative diagnosis, and Patient classification

Exclusion criteria for the study were an unconfirmed diagnosis of PAS according to pathologic specimens, an emergent admission with massive vaginal or intraabdominal bleeding, and conservative surgery without hysterectomy. Hemodynamically stable patients who consented to the preoperative cystoscopy and had positive parturition USG criteria for diagnosis of PAS were included in the study. We used the same high-resolution ultrasound device (GE Voluson® S10) in our department to diagnose all patients with PAS in the prenatal period. The sonographic criteria for the placental invasion were placental lacunae image, increased vascularity or the vascular bridge between the posterior bladder wall and lower uterine segment, turbulent flow in the doppler, and decreased myometrial thickness at the border of the vesicouterine fold [11].

A total of 123 PAS patients were operated at Gaziantep University Gynecology and Obstetrics Clinic between 2019–2021. Conservative surgical methods such as anterior uterine segment resection, bilateral hypogastric artery ligation, uterine balloon tamponade, and stepwise uterine devascularization were performed on 31 patients. Moreover, 92 patients underwent a cesarean hysterectomy. The ten patients who underwent an emergency cesarean hysterectomy and four who did not consent to preoperative cystoscopy were excluded from the study. Consequently, 78 patients who underwent planned cystoscopy before cesarean hysterectomy were included in the study. All cesarean hysterectomy specimens were histopathologically confirmed for PAS diagnosis and divided into three subgroups accreta, increta, and percreta.

Cystoscopy procedure

The same obstetrician team performed preoperative cystoscopy under the supervision of an expert consultant urologist. All cystoscopy procedures were performed in a low lithotomy position with the same device (Karl Storz®) before general anesthesia induction for patients. In addition, the diameter and angle of the cystoscopic telescope were the same, 22-French size and 30-degree, respectively. The present study was designed using current cystoscopic signs of placental invasion [13], such as neovascularization, arterial pulsatility, and posterior bladder wall bulging, illustrated in Figure 1. Consequently, the correlation between the preoperative cystoscopic signs and histopathological results of the PAS patients was examined in detail.

Statistical data analysis

Initiating the study, the sample size was computed by power analysis using Gpower3.1 software. The minimum possible number of patients found was 56 of the sample

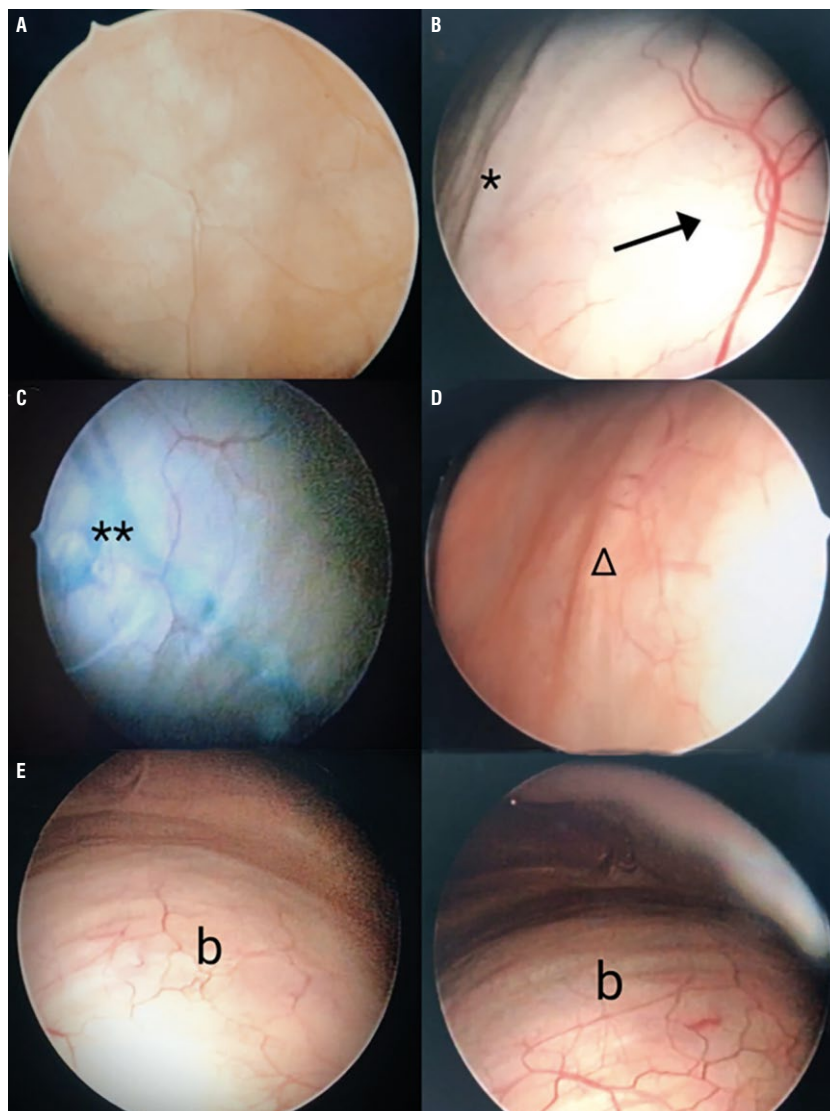


Figure 1. Cystoscopy images; **A.** A normal cystoscopic view of a posterior bladder wall (*); **B.** The “asterisk” indicates an arterial blood vessel on the surface of the lower uterine segment through the bladder wall, “arrow” indicates the neovascularization area in the posterior bladder wall; **C.** The “double asterisk” in the neovascularization area at the posterior bladder wall indicates venous blood vessels of the placental invasion; **D.** The “triangle” indicates pulsatile arterial blood vessels on the surface of the lower uterine segment through the bladder wall; **E.** The “b” signs indicate bulging in the posterior bladder wall; *The image was obtained from a term-pregnant patient with informed consent

size analysis based on the data of the first 20 patients included in the study, considering a 95% confidence interval, medium effect size, and an 80% power. The compatibility of numerical variables to normal distribution was evaluated by the Shapiro Wilk test. ANOVA and LSD tests were used to compare normally distributed numerical measurements in three groups. Kruskal Wallis and All Pairwise tests were used to compare non-normally distributed numerical measurements in three groups. The comparison of categorical variables was done by using the Chi-square test. Logistic regression analysis was performed to the correlation and comparison of categorical variables (histopathologically confirmed subgroups of PAS, and cystoscopic signs). Receiver

operating characteristic (ROC) curves and Bayesian decision theory graphs were drawn for neovascularization, bulging, and arterial pulsatility. Odds ratio, 95% confidence interval (CI), and p values were calculated by SPSS 22.0 Windows version and R version 3.5.1 (R Statistical Software, Institute for statistics and Mathematics, Vienna, Austria). The p value of less than 0.05 was considered statistically significant.

RESULTS

Table 1 shows the demographic, clinical, and perioperative characteristics of the included 78 patients in this study. According to histopathological results, 28% of the cases were accreta, 13% increta, and most of them, 59% percreta.

Table 1. Comparison of the demographic, clinical and perioperative features of the accreta, increta and percreta groups

Variables	Accreta group (n = 22)	Increta group (n = 10)	Percreta group (n = 46)	P
Age [years]†	31.09 ± 7.28	32.2 ± 6.7	32.72 ± 4.41	0.884
Gestational age [weeks]†	34.45 ± 3.94	35.8 ± 1.69	34.61 ± 2.37	0.303
BMI [kg/m ²]†	27.62 ± 3.41	26.09 ± 1.96	27.22 ± 2.79	0.512
Gravida [n]†	3.91 ± 2.99 ^A	4.7 ± 1.64	5.13 ± 1.42 ^B	0.018*
Parity [n]†	1.86 ± 1.81 ^A	3 ± 1.15	3.57 ± 0.98 ^B	0.001*
Number of previous cesarean sections [n]†	0.91 ± 1.15 ^A	2.5 ± 0.85 ^B	2.87 ± 0.96 ^B	0.001*
Duration of operation [min]†	70.91 ± 15.71 ^A	102 ± 19.32 ^B	102.83 ± 20.83 ^B	0.001*
Preoperative Hb [g/dL]†	11.58 ± 1.21	11.33 ± 0.82	11.21 ± 1.21	0.468
Postoperative Hb [g/dL]†	10.43 ± 1.08	10.34 ± 1.03	10.33 ± 1.14	0.713
Transfused pRBC [unit]†	0.5 ± 1.37 ^A	1.6 ± 1.96 ^B	1.63 ± 1.5 ^B	0.001*
Estimated blood loss [mL]†	638.64 ± 463.15 ^A	1000 ± 848.2	866.3 ± 439.58 ^B	0.002*
Duration of hospital stay [day]†	2.5 ± 1.47 ^A	2.9 ± 1.2	3.72 ± 1.71 ^B	0.001*
Bladder injury‡	0 (0%)	1 (10%)	6 (13%)	0.083

BMI — body mass index; Hb — hemoglobin; pRBC — packed red blood cells, †mean ± standard deviation; ‡ N (%); ^Bis significantly higher than ^A; * p < 0.05 value is significant

Table 2. Comparison of preoperative cystoscopic signs in accreta, increta and percreta groups

Groups	Accreta group (n = 22)	Increta group (n = 10)	Percreta group (n = 46)	P
Neovascularization †	3 (13.6%) ^A	7 (70%) ^A	39 (84.8%) ^B	0.001*
Posterior bladder wall bulging †	0 (0%)	6 (60%) ^A	37 (80.4%) ^B	0.001*
Arterial pulsatility †	0 (0%)	5 (50%) ^A	26 (56.5%) ^B	0.001*

†N (%); ^B is significantly higher than ^A; * p < 0.05 value is significant

The mean age was 32.19 ± 5.61 (Mean ± SD) years, the mean BMI was 27.18 ± 2.89 kg/m² (Mean ± SD) and the number of previous cesarean sections was 2.26 ± 1.31 (Mean ± SD) for included patients. The number of gravida and parity were 4.73 ± 2.05 (Mean ± SD) and 3.01 ± 1.47 (Mean ± SD), respectively. The gestational age of the patients at the time of the cesarean hysterectomy was 34.71 ± 2.83 (Mean ± SD) weeks. The mean duration of the cesarean hysterectomy operation was 93.71 ± 23.91 minutes (Mean ± SD), plus the mean duration of the cystoscopy procedure ranged from 2 to 4 minutes was 2.5 ± 0.69 (Mean ± SD). In addition, the mean duration of postoperative hospitalization was 3.26 ± 1.66 days (Mean ± SD). Moreover, the pre- and postoperative hemoglobin levels were 11.32 ± 1.16 g/dL (Mean ± SD) and 10.35 ± 1.09 g/dL (Mean ± SD), respectively. Furthermore, the approximate measured intraoperative blood loss was 819.23 ± 520 mL (Mean ± SD) for each patient, plus the number of intraoperative transfused packed red blood cells (pRBC) was 1.30 ± 1.58 units (Mean ± SD). Although 52 of the 78 patients (66.7%) included had at least one cystoscopic sign of placental invasion, the remaining 26 patients (33.3%) had no identified signs. While the

cystoscopic signs of an invasive placenta were high-rate figured in the percreta group (91.3%), there were the least in the accreta group (13.6%). The most common cystoscopic sign image of PAS was neovascularization (62.8%), while the least common was arterial pulsatility in the neovascularized areas (39.7%). The neovascularization image was positive in cystoscopy for all three histopathological subgroups. On the other hand, the signs of posterior bladder wall bulging and arterial pulsatility in cystoscopy were found positive only in the increta and percreta groups. The comparison of cystoscopic signs according to all histopathological subgroups is presented in Table 2. The preoperative cystoscopic signs such as neovascularization, the posterior bladder wall bulging, and the arterial pulsatility in neovascularized zones were approximately associated with a 17-fold [OR = 16.9 (95% CI, 5.7–49.8)], 26-fold [OR = 26.1 (95% CI, 8.17–83.8)], and 9-fold [OR = 8.94 (95% CI, 2.94–27.1)] increase in the likelihood of placenta percreta, respectively. The sensitivity-specificity-accuracy of preoperative cystoscopic signs regarding histopathologically diagnosed placenta percreta cases were 80–76–78% for the neovascularization, 86–74–81% for the posterior bladder wall bulging, and 57–84–68% for

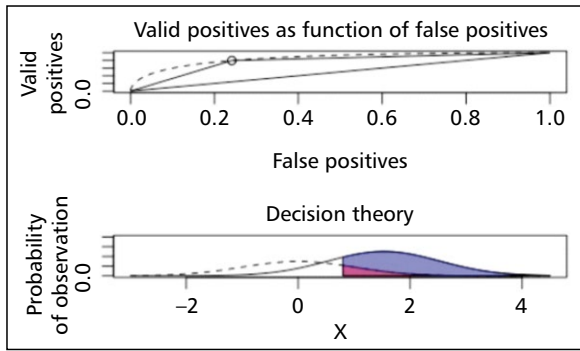


Figure 2. Valid positives receiver operating characteristic (ROC) curve and Bayesian decision theory graph for false positives regarding the sign of neovascularization

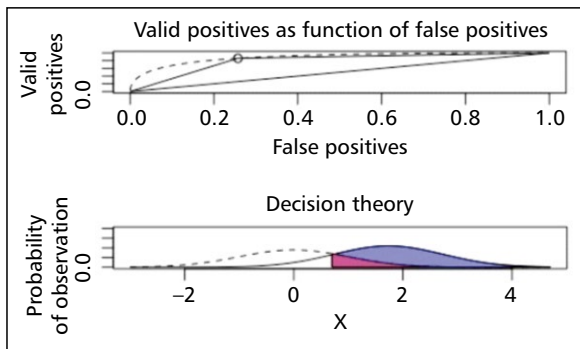


Figure 3. Valid positives receiver operating characteristic (ROC) curve and Bayesian decision theory graph for false positives regarding the sign of posterior bladder wall bulging

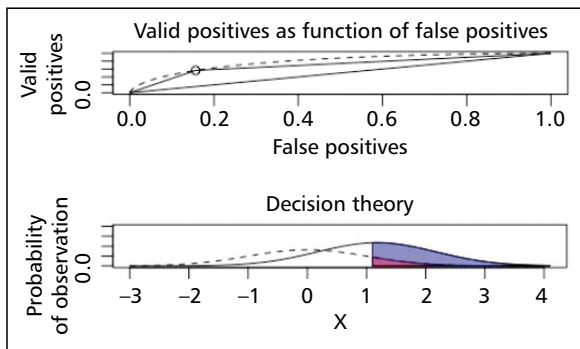


Figure 4. Valid positives receiver operating characteristic (ROC) curve and Bayesian decision theory graph for false positives regarding the sign of arterial pulsatility

the arterial pulsatility, respectively. In addition, their ROC curve and Bayesian decision theory graphs are presented in Figures 2, 3, and 4, in the same order.

Complications and management

A total of seven bladder injuries ranging in size from 2 to 8 cm were mainly repaired with continuous closure with 3/0 synthetic absorbable monofilament sutures for the mucosa plus interrupted closure with 2/0 polyglactin 910 sutures for the muscle and serosa. One of the patients operated on due to placenta percreta underwent re-laparotomy due to an 8 cm hematoma formation detected above the vaginal cuff by ultrasound on the postoperative sixth hour. Upon detection of bleeding at sites of previous placental invasion of the bladder in re-laparotomy of this patient, the bleeding was stopped using sutures plus bipolar coagulation. Two units of packed red blood cells (pRBC) and two units of fresh frozen plasma (FDP) were suitably given to the patient by an anesthesiologist during this re-laparotomy. Besides, the uninfected 5 cm wound dehiscence in the incision line on the seventh postoperative day was detected in a patient with placenta accreta. The un-infected wound opening was closed by interrupted 0 polypropylene sutures under sterile conditions with local anesthesia. In another patient with placenta percreta, a bride ileus complication developed at the end of the first week after surgery. The patient underwent re-laparotomy due to an acute abdomen, and a specialist general surgeon performed a bridectomy. None of the patients included in the study developed complications related to cystoscopy.

DISCUSSION

The current study was designed to determine the potential role of preoperative cystoscopy in indicating placental invasion depth for PAS patients and thus predict the possible surgical outcomes. The results regarding sensitivity, specificity, and accuracy of the three admitted preoperative cystoscopic signs reveal that preoperative cystoscopy may be helpful in the diagnosis of PAS and may have a crucial role in specifying the severity of placental invasion depth. In addition, the results signified that the diagnostic value and power of preoperative cystoscopy increased significantly in parallel with the severity of the depth of placental invasion.

Management of PAS patients is one of the most challenging procedures in obstetrics [14], and it is known that urinary organ injuries and severe hemorrhages are common intraoperatively. For this reason, it is recommended that the surgical procedures planned to be applied to the patients should be evaluated carefully and on a case-by-case basis preoperatively [14]. In recent years, the number of studies involving crucial surgical techniques such as internal iliac artery ligation or embolization [15, 16] on reducing the amount of perioperative bleeding in PAS patients with severe placental invasion has remarkably increased due to

the issue's vital importance. Severe placental invasion in PAS patients is one of the most important causes of intraoperative hemorrhages [17, 18]. Intraoperative hemorrhages are associated with many complications as hysterectomy, disseminated intravascular coagulation, multisystem organ failure, acute respiratory distress syndrome, and even death in these patients [19, 20]. Therefore, it is crucial to determine the severity of the placental invasion in the prenatal period to prevent possible complications [10, 11, 21]. Tikkanen et al. [22] reported that the PAS patients diagnosed in prepartum had less blood loss and required lower blood transfusions than those diagnosed during delivery. Another study presented a decrease in intraoperative hemorrhage risk, adjacent organ damage, and operative complications for PAS patients diagnosed in the prenatal period [18]. Although USG is the first method recommended for antenatal PAS diagnosis, MRI can also be used in selected patients to confirm the diagnosis [23–25]. A recent meta-analysis calculated 83% sensitivity and 95% specificity for USG versus 82% sensitivity and 88% specificity for MRI in PAS patients [26]. Although the rates of antenatal diagnosis of PAS have increased with improved imaging techniques, recent studies have reported that up to two-thirds of PAS patients may not be diagnosed in the prenatal period [27–29]. Increasing prevalence and diagnostic challenges for PAS have led obstetricians to search for new diagnostic techniques to identify PAS subgroups [30]. In addition, there have been significant advances in the prenatal diagnosis of PAS in recent years [22]. USG is still the most commonly used diagnostic method for detecting and sub-grouping PAS patients in the prenatal period; on the other hand, the preoperative cystoscopy procedure may be used innovatively as a primary or supplementary method for identifying the depth of placental invasion as closely as reality. Moreover, preoperative cystoscopy may be a promising, and novel minimally invasive method to specify the severity of placental invasion. As known, prenatal cystoscopy has the beneficial efficacy of assisting the primary diagnosis of PAS in the ultrasound examination of unclear or suspicious [12, 13, 31]. Al-Kahn et al. [13] declared that preoperative cystoscopic signs such as neovascularization and posterior bladder wall bulging could determine the severity of placenta accreta spectrum disorders. They reported that cystoscopic signs such as neovascularization and the posterior bladder wall bulging increased the likelihood of placenta percreta by 17-fold and 12-fold, respectively. In line with the previous study and with a higher association, our calculated ratios regarding cystoscopic signs such as neovascularization and posterior bladder wall bulging were 17-fold and 26-fold in the likelihood of placenta percreta increasing, respectively. Furthermore, we found a 9-fold increase likelihood of placenta percreta in the presence of arterial pulsation signs in the preoperative cystoscopy.

Yan Lui et al. [12] compared USG and cystoscopy in the prenatal diagnosis of PAS subgroups. Researchers noted that the diagnostic power of both methods increases in parallel with the depth of placental invasion and has similar diagnostic values. In addition, they reported that the sensitivity of cystoscopy was highest (100%) in the placenta percreta group, while the specificity was similar (86.4%) for all subgroups. Similarly, our study revealed that abnormal cystoscopic signs increase the depth of invasion. Neovascularization, posterior bladder wall bulging, and arterial pulsatility signs' sensitivity and specificity for placenta percreta prediction were 80–76%, 86–74%, and 57–84%, respectively.

Our study may contribute to the literature on this crucial and current topic. Furthermore, this study was differently designed from the previous studies. The cystoscopic procedure was performed in the preoperative period for PAS patients diagnosed with USG, and surgical specimens were configured histopathological. As far as we know, our prospectively designed study on preoperative cystoscopy has the most extensive number of PAS patients and the subgroup of placenta percreta. This excess in the number of operated PAS patients may be related to our tertiary hospital, which serves the potential approximately 5 million people in the hinterlands in the southeast region of Turkey. The principal limitation of our study may be including patients who underwent only cesarean hysterectomy rather than different surgical techniques such as anterior segmental uterine wall resection in PAS management.

CONCLUSIONS

Our study shows that preoperative cystoscopy may provide helpful and complementary contributions to other imaging methods in specifying the depth of placental invasion. Experienced obstetricians familiar with hysteroscopy operations may perform the preoperative cystoscopic procedure safely under the guidance of a specialist urologist. Abnormal cystoscopic signs may identify high-risk PAS patients who need to be probably transferred to a multidisciplinary and experienced tertiary center. In addition, preoperative cystoscopy can provide beneficial preoperative knowledge to avoid urological complications in patients with severe signs of placental invasion. Further studies are needed to evaluate the success rates of preoperative cystoscopy in determining the degree of placental invasion in patients with PAS.

Authorship contributions

FC designed and carried out the study, performed the surgical procedures, followed up with the patients, contributed to the first draft of the paper, and revised the manuscript critically for important intellectual content. SS contributed to the design of the study and the first draft of the paper, edited the language, and revised the ma-

nuscript critically for important intellectual content. HCO designed the study, performed the surgical procedures, wrote the manuscript, and finalized the paper. OKK performed the surgical procedures, followed up with the patients, and contributed to the first draft of the study. ES and CD revised the manuscript critically for important intellectual content. HB analyzed and interpreted the data. All authors read and approved the final article.

Statement of ethics

The design of the study was approved by the local ethics committee (The Clinical Research Ethics Committee of Gaziantepe University by its decision dated 09 January 2019 and numbered 2018/259) and performed by following the ethical standards described in the current version of the Helsinki Declaration guideline. In addition, informed consent forms were obtained from all participants.

Conflict of interest

The authors declared no conflict of interest.

REFERENCES

- Lasica M, Sparrow RL, Tacey M, et al. members of the Australian and New Zealand Massive Transfusion Registry Steering Committee. Haematological features, transfusion management and outcomes of massive obstetric haemorrhage: findings from the Australian and New Zealand Massive Transfusion Registry. *Br J Haematol.* 2020; 190(4): 618–628, doi: [10.1111/bjh.16524](https://doi.org/10.1111/bjh.16524), indexed in Pubmed: [32064584](https://pubmed.ncbi.nlm.nih.gov/32064584/).
- Cahill AG, Beigi R, Heine RP, et al. Society of Gynecologic Oncology, American College of Obstetricians and Gynecologists and the Society for Maternal–Fetal Medicine. Placenta Accreta Spectrum. *Am J Obstet Gynecol.* 2018; 219(6): B2–BB16, doi: [10.1016/j.ajog.2018.09.042](https://doi.org/10.1016/j.ajog.2018.09.042), indexed in Pubmed: [30471891](https://pubmed.ncbi.nlm.nih.gov/30471891/).
- Silver RM, Branch DW. Placenta Accreta Spectrum. *N Engl J Med.* 2018; 378(16): 1529–1536, doi: [10.1056/NEJMc1709324](https://doi.org/10.1056/NEJMc1709324), indexed in Pubmed: [29669225](https://pubmed.ncbi.nlm.nih.gov/29669225/).
- Jauniaux E, Collins S, Burton GJ. Placenta accreta spectrum: pathophysiology and evidence-based anatomy for prenatal ultrasound imaging. *Am J Obstet Gynecol.* 2018; 218(1): 75–87, doi: [10.1016/j.ajog.2017.05.067](https://doi.org/10.1016/j.ajog.2017.05.067), indexed in Pubmed: [28599899](https://pubmed.ncbi.nlm.nih.gov/28599899/).
- Wu S, Kocherginsky M, Hibbard JU. Abnormal placentation: twenty-year analysis. *Am J Obstet Gynecol.* 2005; 192(5): 1458–1461, doi: [10.1016/j.ajog.2004.12.074](https://doi.org/10.1016/j.ajog.2004.12.074), indexed in Pubmed: [15902137](https://pubmed.ncbi.nlm.nih.gov/15902137/).
- Berkley EM, Abuhamad A. Imaging of Placenta Accreta Spectrum. *Clin Obstet Gynecol.* 2018; 61(4): 755–765, doi: [10.1097/GRF.0000000000000407](https://doi.org/10.1097/GRF.0000000000000407), indexed in Pubmed: [30339609](https://pubmed.ncbi.nlm.nih.gov/30339609/).
- Algebally AM, Yousef RR, Badr SS, et al. The value of ultrasound and magnetic resonance imaging in diagnostics and prediction of morbidity in cases of placenta previa with abnormal placentation. *Pol J Radiol.* 2014; 79: 409–416, doi: [10.12659/PJR.891252](https://doi.org/10.12659/PJR.891252), indexed in Pubmed: [25411586](https://pubmed.ncbi.nlm.nih.gov/25411586/).
- Jauniaux E, Chantraine F, Silver RM, et al. FIGO Placenta Accreta Diagnosis and Management Expert Consensus Panel. FIGO consensus guidelines on placenta accreta spectrum disorders: Epidemiology. *Int J Gynaecol Obstet.* 2018; 140(3): 265–273, doi: [10.1002/ijgo.12407](https://doi.org/10.1002/ijgo.12407), indexed in Pubmed: [29405321](https://pubmed.ncbi.nlm.nih.gov/29405321/).
- Tam Tam KB, Dozier J, Martin JN. Approaches to reduce urinary tract injury during management of placenta accreta, increta, and percreta: a systematic review. *J Matern Fetal Neonatal Med.* 2012; 25(4): 329–334, doi: [10.3109/14767058.2011.576720](https://doi.org/10.3109/14767058.2011.576720), indexed in Pubmed: [23003574](https://pubmed.ncbi.nlm.nih.gov/23003574/).
- Buca D, Liberati M, Cali G, et al. Influence of prenatal diagnosis of abnormally invasive placenta on maternal outcome: systematic review and meta-analysis. *Ultrasound Obstet Gynecol.* 2018; 52(3): 304–309, doi: [10.1002/uog.19070](https://doi.org/10.1002/uog.19070), indexed in Pubmed: [29660186](https://pubmed.ncbi.nlm.nih.gov/29660186/).
- Jauniaux E, Bhide A, Kennedy A, et al. FIGO Placenta Accreta Diagnosis and Management Expert Consensus Panel. FIGO consensus guidelines on placenta accreta spectrum disorders: Prenatal diagnosis and screening. *Int J Gynaecol Obstet.* 2018; 140(3): 274–280, doi: [10.1002/ijgo.12408](https://doi.org/10.1002/ijgo.12408), indexed in Pubmed: [29405319](https://pubmed.ncbi.nlm.nih.gov/29405319/).
- Liu Y, Fan D, Fu Y, et al. Diagnostic accuracy of cystoscopy and ultrasonography in the prenatal diagnosis of abnormally invasive placenta. *Medicine (Baltimore).* 2018; 97(15): e0438, doi: [10.1097/MD.00000000000010438](https://doi.org/10.1097/MD.00000000000010438), indexed in Pubmed: [29642216](https://pubmed.ncbi.nlm.nih.gov/29642216/).
- Al-Khan A, Guirguis G, Zamudio S, et al. Preoperative cystoscopy could determine the severity of placenta accreta spectrum disorders: An observational study. *J Obstet Gynaecol Res.* 2019; 45(1): 126–132, doi: [10.1111/jog.13794](https://doi.org/10.1111/jog.13794), indexed in Pubmed: [30136333](https://pubmed.ncbi.nlm.nih.gov/30136333/).
- Cnota W, Banas E, Dziechcinska-Poletek D, et al. “The Killer Placenta” - a threat to the lives of young women giving birth by cesarean section. *Ginekol Pol.* 2022 [Epub ahead of print], doi: [10.5603/GPa2021.0235](https://doi.org/10.5603/GPa2021.0235), indexed in Pubmed: [35156697](https://pubmed.ncbi.nlm.nih.gov/35156697/).
- Sucu S, Özcan HÇ, Karuserci ÖK, et al. Is there a role of prophylactic bilateral internal iliac artery ligation on reducing the bleeding during cesarean hysterectomy in patients with placenta percreta? A retrospective cohort study. *Ginekol Pol.* 2021; 92(2): 137–142, doi: [10.5603/GPa2020.0145](https://doi.org/10.5603/GPa2020.0145), indexed in Pubmed: [33448009](https://pubmed.ncbi.nlm.nih.gov/33448009/).
- Pyra K, Szymgyn M, Dymara-Konopka W, et al. Maternal and perinatal outcomes in placenta accreta spectrum disorders with prophylactic internal iliac artery balloon catheterization and embolization. *Ginekol Pol.* 2022; 93(12): 980–986, doi: [10.5603/GPa2021.0221](https://doi.org/10.5603/GPa2021.0221), indexed in Pubmed: [35315022](https://pubmed.ncbi.nlm.nih.gov/35315022/).
- Gulucu S, Uzun KE. Evaluation of blood transfusion rate in obstetric patients. *Ginekol Pol.* 2022; 93(8): 637–642, doi: [10.5603/GPa2021.0261](https://doi.org/10.5603/GPa2021.0261), indexed in Pubmed: [35419797](https://pubmed.ncbi.nlm.nih.gov/35419797/).
- Eller AG, Porter TF, Soisson P, et al. Optimal management strategies for placenta accreta. *BJOG.* 2009; 116(5): 648–654, doi: [10.1111/j.1471-0528.2008.02037.x](https://doi.org/10.1111/j.1471-0528.2008.02037.x), indexed in Pubmed: [19191778](https://pubmed.ncbi.nlm.nih.gov/19191778/).
- Silver RM, Barbour KD. Placenta accreta spectrum: accreta, increta, and percreta. *Obstet Gynecol Clin North Am.* 2015; 42(2): 381–402, doi: [10.1016/j.ogc.2015.01.014](https://doi.org/10.1016/j.ogc.2015.01.014), indexed in Pubmed: [26002174](https://pubmed.ncbi.nlm.nih.gov/26002174/).
- Belfort MA. Publications Committee, Society for Maternal-Fetal Medicine. Placenta accreta. *Am J Obstet Gynecol.* 2010; 203(5): 430–439, doi: [10.1016/j.ajog.2010.09.013](https://doi.org/10.1016/j.ajog.2010.09.013), indexed in Pubmed: [21055510](https://pubmed.ncbi.nlm.nih.gov/21055510/).
- Konijeti R, Rajfer J, Askari A. Placenta percreta and the urologist. *Rev Urol.* 2009; 11(3): 173–176, doi: [10.3909/riu0440](https://doi.org/10.3909/riu0440), indexed in Pubmed: [19918343](https://pubmed.ncbi.nlm.nih.gov/19918343/).
- Tikkanen M, Paavonen J, Loukovaara M, et al. Antenatal diagnosis of placenta accreta leads to reduced blood loss. *Acta Obstet Gynecol Scand.* 2011; 90(10): 1140–1146, doi: [10.1111/j.1600-0412.2011.01147.x](https://doi.org/10.1111/j.1600-0412.2011.01147.x), indexed in Pubmed: [21488840](https://pubmed.ncbi.nlm.nih.gov/21488840/).
- Rezk MAA, Shawky M. Grey-scale and colour Doppler ultrasound versus magnetic resonance imaging for the prenatal diagnosis of placenta accreta. *J Matern Fetal Neonatal Med.* 2016; 29(2): 218–223, doi: [10.3109/14767058.2014.993604](https://doi.org/10.3109/14767058.2014.993604), indexed in Pubmed: [25434644](https://pubmed.ncbi.nlm.nih.gov/25434644/).
- Baughman WC, Corteville JE, Shah RR. Placenta accreta: spectrum of US and MR imaging findings. *Radiographics.* 2008; 28(7): 1905–1916, doi: [10.1148/rg.287085060](https://doi.org/10.1148/rg.287085060), indexed in Pubmed: [19001647](https://pubmed.ncbi.nlm.nih.gov/19001647/).
- Warshak CR, Eskander R, Hull AD, et al. Accuracy of ultrasonography and magnetic resonance imaging in the diagnosis of placenta accreta. *Obstet Gynecol.* 2006; 108(3 Pt 1): 573–581, doi: [10.1097/01.AOG.0000233155.62906.6d](https://doi.org/10.1097/01.AOG.0000233155.62906.6d), indexed in Pubmed: [16946217](https://pubmed.ncbi.nlm.nih.gov/16946217/).
- Familiari A, Liberati M, Lim P, et al. Diagnostic accuracy of magnetic resonance imaging in detecting the severity of abnormal invasive placenta: a systematic review and meta-analysis. *Acta Obstet Gynecol Scand.* 2018; 97(5): 507–520, doi: [10.1111/aogs.13258](https://doi.org/10.1111/aogs.13258), indexed in Pubmed: [29136274](https://pubmed.ncbi.nlm.nih.gov/29136274/).
- Thurn L, Lindqvist PG, Jakobsson M, et al. Abnormally invasive placenta-prevalence, risk factors and antenatal suspicion: results from a large population-based pregnancy cohort study in the Nordic countries. *BJOG.* 2016; 123(8): 1348–1355, doi: [10.1111/1471-0528.13547](https://doi.org/10.1111/1471-0528.13547), indexed in Pubmed: [26227006](https://pubmed.ncbi.nlm.nih.gov/26227006/).
- Fitzpatrick KE, Sellers S, Spark P, et al. The management and outcomes of placenta accreta, increta, and percreta in the UK: a population-based descriptive study. *BJOG.* 2014; 121(1): 62–70; discussion 70, doi: [10.1111/1471-0528.12405](https://doi.org/10.1111/1471-0528.12405), indexed in Pubmed: [23924326](https://pubmed.ncbi.nlm.nih.gov/23924326/).
- Baillit JL, Grobman WA, Rice MM, et al. Eunice Kennedy Shriver National Institute of Child Health and Human Development (NICHD) Maternal-Fetal Medicine Units (MFMU) Network. Morbidly adherent placenta treatments and outcomes. *Obstet Gynecol.* 2015; 125(3): 683–689, doi: [10.1097/AOG.0000000000000680](https://doi.org/10.1097/AOG.0000000000000680), indexed in Pubmed: [25730233](https://pubmed.ncbi.nlm.nih.gov/25730233/).
- Fan D, Wu S, Wang W, et al. Prevalence of placenta previa among deliveries in Mainland China: A PRISMA-compliant systematic review and meta-analysis. *Medicine (Baltimore).* 2016; 95(40): e5107, doi: [10.1097/MD.00000000000005107](https://doi.org/10.1097/MD.00000000000005107), indexed in Pubmed: [27749592](https://pubmed.ncbi.nlm.nih.gov/27749592/).
- Norris BL, Everaerts W, Posma E, et al. The urologist's role in multidisciplinary management of placenta percreta. *BJU Int.* 2016; 117(6): 961–965, doi: [10.1111/bju.13332](https://doi.org/10.1111/bju.13332), indexed in Pubmed: [26389985](https://pubmed.ncbi.nlm.nih.gov/26389985/).