

Brenner tumor of the ovary — ultrasound features and clinical management of a rare ovarian tumor mimicking ovarian cancer

Vit Weinberger¹, Luboš Minář¹, Michal Felsinger¹, Petra Ovesná², Marketa Bednaříková³, Marta Číhalová⁴, Eva Jandáková⁴, Jitka Hausnerová⁴, Barbora Chaloupková⁵, Michal Zikán⁶

¹Department of Gynecology and Obstetrics, University Hospital in Brno and Masaryk University, Brno, Czech Republic

²Institute of Biostatistics and Analyses, Faculty of Medicine, Masaryk University, Brno, Czech Republic

³Clinic of Internal Medicine — Hematology and Oncology,

University Hospital in Brno and Masaryk University, Brno, Czech Republic

⁴Institute of Pathology, University Hospital in Brno and Masaryk University, Brno, Czech Republic

⁵Department of Gynecology and Obstetrics, Regional Hospital T. Bata Zlin, Czech Republic

⁶Department of Gynecology and Obstetrics, Charles University in Prague

— First Faculty of Medicine and Hospital Na Bulovce, Czech Republic

ABSTRACT

Objectives: To describe the ultrasound features of benign Brenner tumor in the background of complex clinical and histopathological pictures.

Material and methods: We retrospectively identified patients with histologically confirmed benign Brenner tumor of the ovary who were treated in our institution in 2003–2016, and for whom complete imaging, clinical, perioperative and histopathological data were available in the database. Ultrasound findings were drawn from images and reports using terms and definitions of the International Ovarian Tumor Analysis group and pattern recognition description was applied.

Results: Twenty-three patients were identified, most postmenopausal and asymptomatic. On ultrasound, 19/23 tumors were found unilaterally, 4/23 bilaterally, and 82% of tumors were detected in the left ovary. Most Brenner tumors (16/23) contained solid components and revealed no or minimal blood flow by subjective color score upon Doppler examination (19/23, 83%). Calcifications with shadowing were observed in 57% of all Brenner tumors and in 81% of tumors containing solid components. The complex appearance of the tumor misled the sonographers to describe the mass as malignant in 9 cases (39%), and frozen section was performed perioperatively. Surgery was performed via laparoscopy in 11 (48%) and via laparotomy in 12 (52%) cases.

Conclusions: The complexity of the ultrasound picture, consisting of features like calcifications with acoustic shadowing, a poorly vascularized solid mass, and a left-sided localization could be signs of a benign Brenner tumor and could preoperatively help to differentiate between benign and malignant tumor.

Key words: Brenner tumor, ovarian neoplasms, diagnosis, surgery, ultrasonography

Ginekologia Polska 2018; 89, 7: 357–363

INTRODUCTION

A Brenner tumor is an epithelial surface tumor of the ovary that was first described by Fritz Brenner in 1907 [1]. It is a mostly benign transitional cell tumor and represents about 3% of ovarian epithelial tumors [2]. Microscopically, the tumor

consists of sharply demarcated uniform islands of epithelial cells in a dense fibromatous stroma. The epithelial cells have a characteristic coffee bean nucleus with longitudinal grooves and pale cytoplasm [3, 4] (Fig. 1). Tumor can contain extensive calcifications. Careful histological examination should be

Corresponding author:

Vit Weinberger

Department of Gynecology and Obstetrics, University Hospital Brno and Masaryk University

Jihlavská 20, Brno, 625 000, Czech Republic

tel.: + 420 532233843

e-mail: vit.weinberger@gmail.com

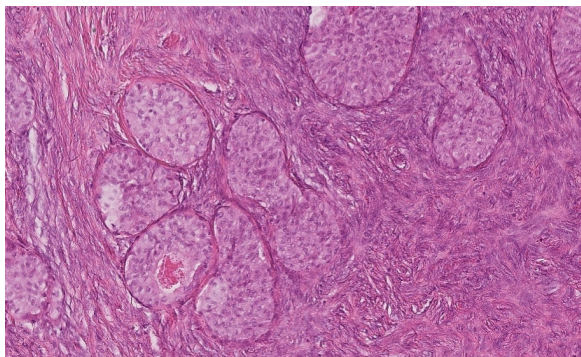


Figure 1. Brenner tumor: Microscopically, the tumor consists of sharply demarcated uniform islands of epithelial cells in a dense fibromatous stroma. The epithelial cells have a characteristic coffee bean nucleus with longitudinal grooves and pale cytoplasm

performed in order to exclude even small foci of malignancy which may arise from the benign Brenner tumor [5, 6]. Most patients are asymptomatic and the tumor is discovered incidentally as a part of routine physical examination and/or ultrasound scan performed by a radiologist or gynecologist in women of any age but predominantly between 50–70 years old [7]. Benign tumors are commonly 5–6 cm in diameter, occasionally exceeding 10 cm [8]. Borderline and malignant Brenner tumors may measure up to 30 cm [9]. Most women are asymptomatic but they can manifest abdominal pain, vaginal bleeding due to estrogenic activity, urinary retention, ascites or pseudo Meigs' syndrome [10].

Appropriate preoperative ultrasound examination is crucial for distinguishing between benign and malignant adnexal tumors and for further management of ovarian masses. However, despite well-established International Ovarian Tumor Analysis (IOTA) imaging criteria for ovarian cancer recognition, ultrasound findings in Brenner tumors overlap with those typical of ovarian cancer which contributes to serious difficulties in image interpretation [11, 12]. Currently, there are no recent studies published on this topic in the literature. Therefore, we reviewed sonographic and clinical data, including the surgical management, on histologically confirmed cases of benign Brenner tumors in our institution. In this study, we aim to indicate the ultrasound features (morphological and vascular ultrasound patterns) of a Brenner tumor and to encourage sonographers dealing with ovarian mass findings to improve their knowledge and awareness of this rare tumor. The correct preoperative diagnosis of a Brenner tumor as a benign pelvic mass enables the choice of a less radical surgical procedure and minimizes fear in patients who may anticipate ovarian cancer diagnosis.

MATERIAL AND METHODS

Study design and patient population

We conducted a retrospective study of ovarian tumors — Brenner tumors that were diagnosed and treated in our

institution between January 2003 and December 2016. The indications for referral for transvaginal and transabdominal sonography were inconclusive examination with suspicion of gynecological cancer due to a palpable adnexal mass, abnormal sonographic findings assessed by a general gynecologist or general practitioner with or without elevated CA 125 tumor marker, and non-specific abdominal symptoms (abdominal/pelvic pain). Most clinical information was retrieved retrospectively from the patient records, such as age at diagnosis, pre- or postmenopausal status, level of CA 125 in blood, risk of malignancy index (RMI), symptoms, presence of ascites according to the IOTA consensus described by Timmerman et al. [12], and detailed histological evaluation results. Only patients with histologically proven benign Brenner tumors were included in the final analysis. All patients underwent surgery and the tumor was removed. Type of surgery (laparoscopy or laparotomy) and the extension ranging from unilateral salpingo-oophorectomy to more extensive as total hysterectomy, bilateral salpingo-oophorectomy were reviewed. Frozen section requests were carefully recorded and analyzed. All clinical and ultrasound data were put into a dedicated Excel file and then analyzed (Microsoft Office Excel 2010). This study was approved by the local ethics committee and all patients gave their informed consent.

Ultrasound examination

Each patient underwent a pre-operative ultrasound examination according to the methodology and protocol of our institution that consisted of both transabdominal and transvaginal examinations performed within 21 days prior surgery by a gynecologist experienced in the field of ultrasound diagnostics in gynecologic oncology. These were expert sonographers with gynecology and oncology experience who were certified by the Czech Gynecologic Ultrasound Society as high-level experts in oncogynecologic sonography. Sonographers VW, BCH, and MZ are holders of IOTA certificate. The ultrasound examinations were performed in B-mode and color and power Doppler mode with both a transvaginal (5–8 MHz) and a transabdominal probe (3.5–5 MHz) on a variety of equipment. Each ultrasound examination was immediately described in the written report and images were stored; both were used in the study analysis. Descriptions and examination reports were performed according to the standards in our center, that include the terms and definitions published by the IOTA group [12]. The reports also included the final assessment of the sonographer whether the mass was suspicious for malignancy or not. Results of Doppler examinations were reported in terms of a subjective color score [12].

Data analysis and methodology

All clinical and ultrasound parameters were summarized using absolute and relative frequencies or median and range

in case of continuous data. All tables were stratified according to the clinical, surgical, and ultrasound characteristics of the patients. No statistical comparisons were done because of the study's descriptive character.

RESULTS

We retrospectively included 23 patients into the study who had histologically proven benign Brenner tumor of the ovary in the 14-year time frame. There were no cases of malignant Brenner tumors in the analysed period of time. The patients' median age was 58 (range 38–71); only 3 (13%) were fertile; no personal or family history of ovarian cancer was reported. Eighteen (78%) patients were asymptomatic while five (22%) presented with abdominal/pelvic pain. Results of serum CA 125 measurements were available for all 23 women; the median level was 19 IU/L (range 9–240 IU/L); only 2 patients manifested raised CA 125 level. In 9 cases, the RMI result was over 200 and those patients were considered at significant risk of ovarian malignancy. The clinical characteristics together with surgical management of all studied patients are described in detail in Table 1. The sonographic characteristics (B-mode and Doppler findings), including the sonographer's suggestion if the tumor was benign/uncertain or malignant are described and summarized in Table 2.

The majority of the tumors (19/23; 82%) were found unilaterally; in 4 cases a Brenner tumor was diagnosed

Table 1. Clinical characteristics and surgical management of patients with Brenner tumor

	Benign Brenner tumor (n = 23)
Age at surgery [years]	58 (38–71)
Serum CA 125 level [IU/L]	19 (9–240)
RMI	81 (36–2430)
Menstruation	
Premenopausal	3 (13%)
Postmenopausal	20 (87%)
Symptomatology	
Asymptomatic	18 (78%)
Pelvic pain	5 (22%)
Surgery	
Frozen section	9 (39%)
Cystectomy Laparoscopy	0 (0%)
Salpingo-oophorectomy Laparoscopy	6 (26%)
Salpingo-oophorectomy Laparotomy	1 (4%)
Total laparoscopic hysterectomy + BSO	5 (22%)
Total abdominal hysterectomy + BSO	11 (48%)

Values are median (range) or n (%); RMI — risk malignancy index; BSO — bilateral salpingo-oophorectomy

Table 2. Ultrasound characteristics of Brenner tumor

	Brenner tumor (n = 23)
Largest diameter [mm]	62 (15–270)
Largest solid component [mm]	40 (0–85)
Laterality	
Unilateral	19 (82%)
Bilateral	4 (18%)
Left	19 (82%)
Right	8 (35%)
Type of tumor	
Unilocular	4 (17%)
Unilocular-solid	0 (0%)
Multilocular	3 (13%)
Multilocular-solid	8 (35%)
Solid	8 (35%)
Calcifications and acoustic shadowing	13 (57%)
Ascites	1 (4%)
Echogenicity of cyst fluid	
Anechogenic	14 (61%)
Ground glass	0 (0%)
Low level	1 (4%)
Doppler results: Color score	
None	8 (35%)
Minimal	11 (48%)
Moderate	4 (17%)
Abundant	0 (0%)
Ultrasound diagnosis	
Benign	13 (57%)
Uncertain	1 (4%)
Malignant	9 (39%)

Values are median (range) or n (%)

simultaneously in both ovaries. Looking closer at lateralization of the masses, 15 tumors were detected in the left ovary only and another 4 were in the left as a part of their bilateral presence (overall, the left ovary was affected by tumor in 82%). The median diameter of the tumor was 62 mm (range 15–270 mm) and the diameter of the largest solid component was 40 mm (range 0–85 mm). The majority, or 16/23 tumors (70%), contained solid components (Fig. 2, Fig. 3) while pure cystic content was present in 7 masses (30%) only. The cystic fluid was anechogenic in 14 tumors (61%) (Fig. 4) while 1 (4%) had low-level echogenicity. Ascites with simultaneously elevated CA 125 level in blood (240 IU/L) were present in 1 patient and no pleural effusion was diagnosed. The color score varied between none and moderate at Doppler examination; no abundantly vascularized tumor was noted. Most tumors were minimally perfused (11/23, 48%); no blood

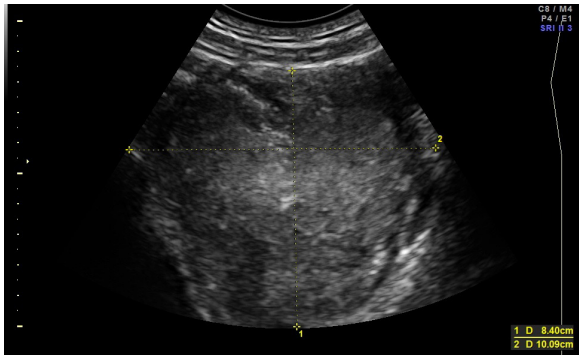


Figure 2. Transabdominal ultrasound image of 10 cm purely solid benign Brenner tumor

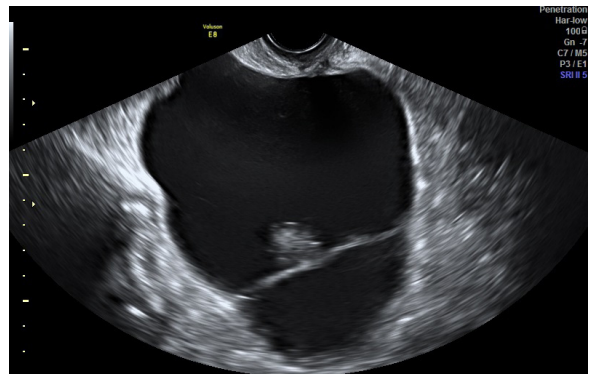


Figure 4. Transvaginal ultrasound image of a multilocular–solid Brenner tumor. There is a septum in the anechoic cystic component. The internal cyst walls are regular with some calcifications foci in the wall

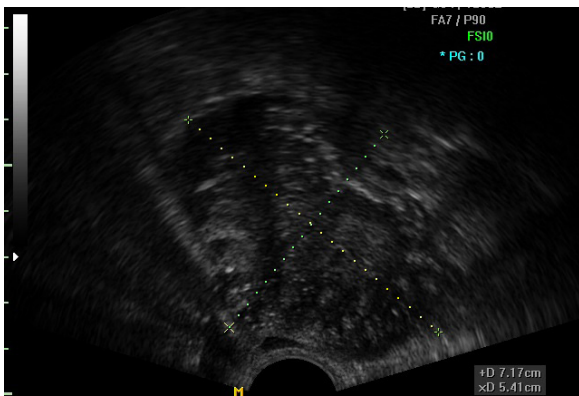


Figure 3. Transvaginal ultrasound image of a purely solid benign Brenner tumor with multiple scattered calcifications and acoustic shadowing behind the tumor

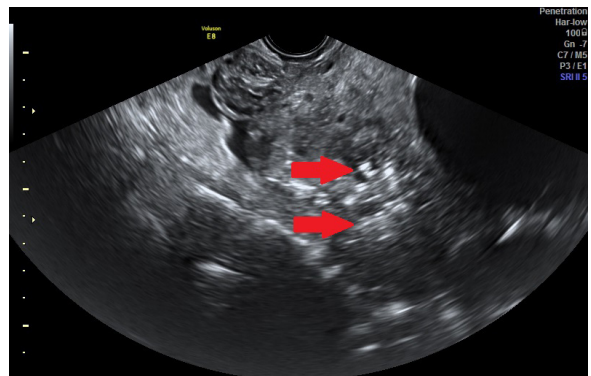


Figure 5. Transvaginal ultrasound image of a solid benign Brenner tumor containing an anechoic cystic component, calcifications (arrows) and acoustic shadowing behind the tumor

flow was detected in 8/23 (35%). Shadowing of the acoustic signal behind the cyst was observed in 13 tumors which represents 57% of all Brenner tumors (Fig. 3, Fig. 5). Applying pattern recognition description (Tab. 3), a Brenner tumor could be described as follows: 7 masses were unilocular or multilocular with no specific characteristics. All these masses were correctly classified as benign. Eight tumors were described as multilocular solid with calcifications and shadowing behind the mass while solid structures were minimally to moderately vascularized at Doppler. Eight masses were purely solid with calcifications causing acoustic shadowing

behind the tumor; the solid part was minimally or moderately vascularized at Doppler. The complex appearance of the Brenner tumor misled the sonographers in 9 cases (39%) to describe the mass as malignant and frozen section was performed perioperatively (Fig. 5, Fig. 6). The features of the misclassified benign Brenner tumors were different to the others suggested as benign. They were generally larger than the median (62 mm) of all Brenner tumors, reaching a diameter of 130 mm (range 70–270 mm) and the solid component was 70 mm (range 40–85 mm) in comparison to the 40 mm median of all Brenner tumors in the study.

Table 3. Classification of Brenner tumors according to characteristics on pattern recognition

	Brenner tumor (n = 23)	N of tumors misdiagnosed as malignant in each category
Unilocular or multilocular tumor with no specific characteristics †	7	0
Multilocular solid tumor with calcifications causing shadowing behind the tumor, solid structure minimal to moderate vascularized at Doppler	8	6
Solid tumor with calcifications causing shadowing behind the tumor, solid structure minimal to moderate vascularized at Doppler	8	3

† solid structure, shadowing, calcifications; N — number

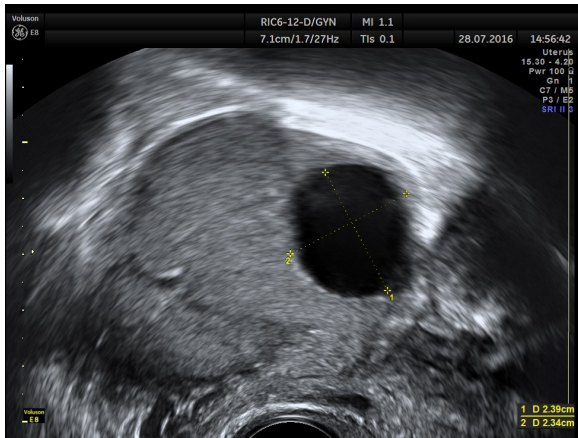


Figure 6. Transvaginal ultrasound image of a solid benign Brenner tumor containing an anechoic cystic component described as malignant by sonographer

All bilateral Brenner tumors were preoperatively classified as malignant and all 9 misclassified tumors contained a solid portion, of these, 3 were purely solid with minimal or moderate vascularization of the solid structures.

All 23 patients in our series underwent surgery and the ovarian mass was removed. Among these, no patient underwent cystectomy only, 7 patients were treated with salpingo-oophorectomy and 16 with total hysterectomy and bilateral salpingo-oophorectomy. Surgery was performed via laparoscopy in 11 (48%) cases, via laparotomy in 12 (52%) cases. Nine patients underwent surgical staging for ovarian cancer, consisting of peritoneal washing, a macroscopic assessment of intra-abdominal organs and perioperative frozen section. These cases were described as suspicious adnexal masses according to the preoperative ultrasound examination.

DISCUSSION

We present a series of 23 patients with benign Brenner tumors of the ovary diagnosed and treated in our institution. Clinical characteristics of the cohort are in concordance with those previously published [8, 10, 13]. Typically, Brenner tumors occur in postmenopausal women. Most patients were asymptomatic and the pelvic mass was an incidental finding with negative tumor markers. Although tumor estrogenic activity could be manifested as vaginal bleeding, in our study 5 patients presented with abdominal pain and others were asymptomatic. An ovarian mass and an elevated serum CA125 level generally suggest a malignant process in a postmenopausal woman. There are studies evaluating the predictive value of CA 125 level and malignancy, showing that tumor marker CA 125 alone is not suitable for distinguishing between benign and malignant adnexal mass [14]. Only 2 patients manifested elevated CA 125 level in blood and 1 of them ascites. Nine patients had RMI scores

above 200 and were evaluated by an experienced sonographer. In 5 patients with positive RMI, frozen section was performed perioperatively; 4 patients were considered as benign according to the sonographer suggestion. About 1% of Brenner tumors are reported to be malignant in the literature [8, 15]. All Brenner tumors in our study were benign; therefore, we are unable to comment on the clinical status and further management of malignant Brenner tumors.

Transvaginal and transabdominal ultrasound performed by an experienced sonographer is a standard preoperative imaging method in our center for patients with adnexal masses. There are studies on rare ovarian tumors published which describe unique ultrasound features that may help to postulate a correct specific diagnosis before surgery. This is true in cases of struma ovarii (the “struma pearl”), granulosa cell tumors (“Swiss cheese appearance”), and Sertoli–Leydig cell tumors [16–18], but there are no unique features described in Brenner tumors so far. In Dierickx’s 2012 report, experienced sonographers failed to describe unique ultrasound feature in 14 images of Brenner tumor and no other study has found specific characteristics either [11]. Many benign Brenner tumors manifest as entirely solid structure on ultrasound examination but some can appear as cystic with or without solid structures [7]. In our study, we described the sonographic features of 23 Brenner tumors of the ovary; seven tumors (30%) were cystic and 16 (70%) with complex appearance. Solid components were poorly vascularized on color Doppler. In the literature, calcifications have been reported of 50% of Brenner tumors on sonography and 83% on CT [7]. Dierickx described calcifications on ultrasound scans in 13 (87%) of 15 benign Brenner tumors [11]. We reported 81% of Brenner tumors containing solid component revealed acoustic shadowing caused by visible calcifications. Therefore, we conclude that ultrasound signs of multiple calcifications could be a key feature for the diagnosis. Data on the laterality of Brenner tumor (whether right or left ovary) vary in the literature [3, 10, 19], but in our series, 82% of the Brenner tumors were detected in the left ovary. This is in concordance with the study published by Dierickx which reported unilateral lesions to be present more common in the left ovary [4, 11]. In our series, 4/23 (18%) Brenner tumors were bilateral. This is slightly above the range of 5–14% that is reported in the literature [10, 20]. There is an association of Brenner tumors with a second ovarian neoplasm noted and the rate of 30% is reported in the literature [8, 10, 15]. In our study, 26% of patients presented with an associated benign tumor: 2 were serous and 4 mucinous cystadenomas. Using subjective assessment, the sonographers correctly classified the ovarian tumor as benign in 57% (13/23) of the tumors (in 1 tumor, the sonographer was uncertain) which represent real clinical difficulties to differentiate benign Brenner tumor from

ovarian malignancy. Preoperatively, ultrasound findings were discussed with the patients and each gave informed consent for a staging and radical debulking procedure in case of malignancy.

In our study, almost half (48%) of the patients underwent laparoscopy. There may be a general objection that the laparoscopic removal of a potentially malignant adnexal tumor increases the possibility of tumor spillage and port site metastasis development. Based on our experience, laparoscopic approach can be easily adopted not only for young, fertile-age patients but also for most patients — even postmenopausal — who require total hysterectomy with bilateral salpingo-oophorectomy for adnexal mass. In our series, the tumor was inserted safely into the endobag which enabled extraction from the abdomen without spilling potentially malignant cells into the abdominal cavity. Conservative surgery is strongly advised for women with the potential and desire for fertility [9, 14].

We admit several limitations of our study. Firstly, this is a single institution retrospective study. The Brenner tumor is a rare tumor; therefore, it was necessary to collect cases over a long-time frame. Ultrasound data and examinations were retrieved by using several ultrasound devices. Although our series seems to be one of the largest, dealing with complex clinical, surgical data, ultrasound reports and descriptions; the number of cases ($n = 23$) remains small. Therefore, ultrasound features and characteristics of benign Brenner tumor may be biased. The strength of our study is based on a comprehensive unique database of clinical, surgical, and pathological data connected with highly experienced preoperative ultrasound performance. Our data demonstrates real clinical difficulties arising from the ultrasound findings of such a strange adnexal mass. Due to the rareness of the Brenner tumor, more ultrasound and clinical data are needed, and our study may contribute to better insights into the proper and adequate management of this rare ovarian tumor.

CONCLUSIONS

The variable sonographic picture of the ovarian Brenner tumor and its rare occurrence make ultrasound diagnosis very challenging. In the benign Brenner tumors, we failed to find one specific ultrasound feature that could easily characterize this tumor. More probably, the complexity itself of the ultrasound picture, consisting of features such as calcifications with shadowing, poorly vascularized solid component, and a left-sided localization of the mass could be signs of a benign Brenner tumor and could help even an experienced sonographer in deciding whether the lesion is benign or malignant. In surgical management of the Brenner tumor,

laparoscopy should be considered and preferred. We believe our study may contribute to the awareness of the Brenner tumor and thus minimize patients' fear of an ovarian cancer diagnosis while also reducing the number of unnecessary laparotomies and extensive surgical procedures.

Acknowledgments

This work was supported by the Ministry of Health of the Czech Republic under projects CZ-DRO FNBr 65269705 and AZV 17-32030A. MZ is a senior author of this work. No assistance was used in the writing of this article.

Conflicts of interest

The authors declare no conflicts of interest.

REFERENCES

- Brenner F. Das Oophoroma folliculare. *Frankf Z Path.* 1907; 1: 150–171.
- Seidman JD, Russell P, Kurman RJ. Surface epithelial cells of the ovary. In: Kurman RJ. ed. *Blaustein's Pathology of the Female genital tract.* Springer-Verlag, New York 2002: 791–904.
- Ordóñez NG, Mackay B. Brenner tumor of the ovary: a comparative immunohistochemical and ultrastructural study with transitional cell carcinoma of the bladder. *Ultrastruct Pathol.* 2000; 24(3): 157–167, indexed in Pubmed: [10914427](#).
- Blaustein A. Brenner tumors. In: *Pathology of the female genital tract.* Springer-Verlag, New York 1982: 547–553.
- Roth LM, Dallenbach-Hellweg G, Czernobilsky B. Ovarian Brenner tumors. I. Metaplastic, proliferating, and of low malignant potential. *Cancer.* 1985; 56(3): 582–591, indexed in Pubmed: [4005815](#).
- Roth LM, Sternberg WH. Proliferating Brenner tumors. *Cancer.* 1971; 27(3): 687–693, indexed in Pubmed: [5549500](#).
- Green G, Mortelet K, Glickman J, et al. Brenner Tumors of the Ovary. *Journal of Ultrasound in Medicine.* 2006; 25(10): 1245–1251, doi: [10.7863/jum.2006.25.10.1245](#).
- Silverberg SG. Brenner tumor of the ovary. A clinicopathologic study of 60 tumors in 54 women. *Cancer.* 1971; 28(3): 588–596, indexed in Pubmed: [5096924](#).
- Roth LM, Czernobilsky B. Ovarian Brenner tumors. II. Malignant. *Cancer.* 1985; 56(3): 592–601, indexed in Pubmed: [4005816](#).
- Yoonessi M, Abell MR. Brenner tumors of the ovary. *Obstet Gynecol.* 1979; 54(1): 90–96, indexed in Pubmed: [450368](#).
- Dierickx I, Valentin L, Van Holsbeke C, et al. Imaging in gynecological disease (7): clinical and ultrasound features of Brenner tumors of the ovary. *Ultrasound Obstet Gynecol.* 2012; 40(6): 706–713, doi: [10.1002/uog.11149](#), indexed in Pubmed: [22407678](#).
- Timmerman D, Valentin L, Bourne TH, et al. International Ovarian Tumor Analysis (IOTA) Group. Terms, definitions and measurements to describe the sonographic features of adnexal tumors: a consensus opinion from the International Ovarian Tumor Analysis (IOTA) Group. *Ultrasound Obstet Gynecol.* 2000; 16(5): 500–505, doi: [10.1046/j.1469-0705.2000.00287.x](#), indexed in Pubmed: [11169340](#).
- Turgay B, Koyuncu K, Taşkın S, et al. Features of ovarian Brenner tumors: Experience of a single tertiary center. *Turk J Obstet Gynecol.* 2017; 14(2): 133–137, doi: [10.4274/tjod.98216](#), indexed in Pubmed: [28913150](#).
- Valentin L, Jurkovic D, Van Calster B, et al. Adding a single CA 125 measurement to ultrasound imaging performed by an experienced examiner does not improve preoperative discrimination between benign and malignant adnexal masses. *Ultrasound Obstet Gynecol.* 2009; 34(3): 345–354, doi: [10.1002/uog.6415](#), indexed in Pubmed: [19585547](#).
- van der Westhuizen NG, Tiltman AJ. Brenner tumours — a clinicopathological study. *S Afr Med J.* 1988; 73(2): 98–101, indexed in Pubmed: [3340932](#).
- Savelli L, Testa AC, Timmerman D, et al. Imaging of gynecological disease (4): clinical and ultrasound characteristics of struma ovarii. *Ultrasound Obstet Gynecol.* 2008; 32(2): 210–219, doi: [10.1002/uog.5396](#), indexed in Pubmed: [18636616](#).

17. Van Holsbeke C, Domali E, Holland TK, et al. Imaging of gynecological disease (3): clinical and ultrasound characteristics of granulosa cell tumors of the ovary. *Ultrasound Obstet Gynecol.* 2008; 31(4): 450–456, doi: [10.1002/uog.5279](https://doi.org/10.1002/uog.5279), indexed in Pubmed: [18338427](https://pubmed.ncbi.nlm.nih.gov/18338427/).
18. Demidov VN, Lipatenkova J, Vikhareva O, et al. Imaging of gynecological disease (2): clinical and ultrasound characteristics of Sertoli cell tumors, Sertoli-Leydig cell tumors and Leydig cell tumors. *Ultrasound Obstet Gynecol.* 2008; 31(1): 85–91, doi: [10.1002/uog.5227](https://doi.org/10.1002/uog.5227), indexed in Pubmed: [18098335](https://pubmed.ncbi.nlm.nih.gov/18098335/).
19. Hermanns B, Faridi A, Rath W, et al. Differential diagnosis, prognostic factors, and clinical treatment of proliferative Brenner tumor of the ovary. *Ultrastruct Pathol.* 2000; 24(3): 191–196, indexed in Pubmed: [10914431](https://pubmed.ncbi.nlm.nih.gov/10914431/).
20. Farrar HK, Greene RR. Bilateral Brenner tumors of the ovary. *Am J Obstet Gynecol.* 1960; 80: 1089–1095, indexed in Pubmed: [13698264](https://pubmed.ncbi.nlm.nih.gov/13698264/).