

Clear cell carcinoma derived from an endometriosis focus in a scar after a caesarean section – a case report and literature review

Rak jasnokomórkowy wywodzący się z ogniska endometriozy w bliźnie po cięciu cesarskim – opis przypadku i przegląd literatury

Zuzanna Dobrosz¹, Piotr Paleń¹, Rafał Stojko², Paweł Właszczuk¹, Anna Niesłuchowska-Hoxha², Ilona Piechuta-Kośmider²

¹ Department of Histopathology, Medical University of Silesia, Katowice, Poland

² Department of Obstetrics and Gynecology, Merczi Brother's Hospital, Katowice Poland

Abstract

Endometriosis is defined as the occurrence of endometrial glands and endometrial stromal cells outside their typical localization within the uterus. Malignant transformation of endometriosis foci in a scar after a caesarean section (cc) is very rare – until 2013 (in a span of 40 years), about 40 such cases have been described. In our article, we describe a case of a 42-year-old woman with a tumour localized in a scar after a caesarean section. The tumour was diagnosed as clear cell carcinoma derived from an endometriosis focus. The long time interval – 17 years in average (from 3 to 39 years) between the surgery (cesarean section in most cases) and the tumor diagnosis is characteristic. In the case we describe, the patient was diagnosed 16 years after the endometriosis focus in the scar had arisen. even though endometriosis is a benign lesion, it has many features distinctive for invasive carcinoma; it may itself undergo a malignant transformation as well as increase the risk of endometrial carcinoma or clear cell ovarian carcinoma. Maybe in future, more exhaustive studies will allow establishing a therapeutic protocol in patients with extra-ovarian malignant transformation of endometriosis foci.

Key words: **endometriosis / scar after a caesarean section / malignant transformation / clear cell carcinoma /**

Corresponding author:

Zuzanna Dobrosz
Department of Histopathology, Medical University of Silesia, Katowice
ul. Medyków 14, 40-754 Katowice, Poland
Phone: +48 32 25 25 080; Fax: +48 32 25 25 080
e-mail: katpat2@slam.katowice.pl, dobrosz.zuza@vp.pl

Otrzymano: 30.10.2013
Zaakceptowano do druku: 25.04.2014

Zuzanna Dobrosz et al. Clear cell carcinoma derived from an endometriosis focus in a scar after a caesarean section – a case report and literature review.

Streszczenie

Endometrioza jest definiowana jako obecność gruczołów endometrialnych oraz komórek podścieliska poza typową lokalizacją w macicy. Złośliwa przemiana ognisk endometriozy w bliznie po cięciu cesarskim jest bardzo rzadka – do roku 2013 (na przestrzeni ponad 40 lat) opisano około 20 takich przypadków. W naszej pracy opisujemy przypadek 42-letniej kobiety z guzem zlokalizowanym w bliznie po cięciu cesarskim, który został zdiagnozowany jako rak jasnokomórkowy wywodzący się z ogniska endometriozy. Zwraca uwagę długi interwał czasowy – średnio 17 lat (od 3-39 lat) pomiędzy zabiegiem chirurgicznym (w większości cięciem cesarskim), a diagnozą zmiany nowotworowej. W opisywanym przez nas przypadku pacjentka została zdiagnozowana 16 lat po zaobserwowaniu ogniska endometriozy w bliznie po cięciu. Pomimo iż endometrioza jest zmianą łagodną, posiada wiele charakterystycznych cech typowych dla raka inwazyjnego, może również sama przejść złośliwą transformację, jak i zwiększać ryzyko zachorowania na raka endometrioidalnego oraz jasnokomórkowego jajnika. Być może w przyszłości przeprowadzenie dokładnych badań pozwoli na ustalenie protokołu terapeutycznego u pacjentek, u których doszło do pozajajnikowej transformacji złośliwej ognisk endometriozy.

Słowa kluczowe: **endometrioza / blizna po cięciu cesarskim / złośliwa transformacja / rak jasnokomórkowy**

Introduction

Endometriosis is defined as the occurrence of endometrial glands and endometrial stromal cells outside their typical localization within the uterus [1]. These changes are most often seen in ovaries and the Pouch of Douglas. Endometriosis may be classified with regard to its anatomical site (surgical staging by the revised American Fertility Society score) or on the basis of histological criteria – atypical and non-atypical endometriosis [2, 3]. In about 0.7% – 1.0% of patients, malignant transformation occurs. In 79% of cases, it occurs in ovaries, in 21% – in foci outside ovaries [4]. Malignant transformation of endometriosis foci in a scar after a caesarean section (cc) is very rare – until 2013 (in a span of 40 years), about 28 such cases have been described. In our article, we describe a case of a 42-year-old woman with a tumour localized in a scar after a caesarean section. The tumour was diagnosed as clear cell carcinoma derived from an endometriosis focus.

Case report

42-years old woman, was admitted to Gynecology and Obstetrics Ward in Merci Brother's in Katowice, due to two growing tumors in a scar after a cesarean section that she had 17 years before; and due to chronic pain during the menstruation. A surgical excision of the lesions was planned. On the physical examination the tumors measured 2x4 cm (the tumor on the right side of the scar (in ultrasound examination: 2x4cm), the tumor on the left side of the scar measured 2x5cm (in ultrasound examination: 2x6cm). The transvaginal ultrasound examination showed uterus of homogenous echogenicity, measuring 37.9 mm in AP dimension. The endometrium was slightly heterohomogenous 18.8mm thick, left ovary measured 39x18.7 mm, right ovary measured 34.4x24.4 mm, there was insignificant amount of fluid in the Douglas cavity.

The surgery was performed with Phannenstiell incision. The old scar was excised, an endometrial tumor measuring 8x6cm was dissected from the subcutaneous tissue. Then, a similar lesion was dissected from the fascia, abdominal recti muscles, parietal peritoneum and the area of pubic symphysis. The peritoneum cavity was opened, any endometrial lesion were not found. The peritoneum was closed, the recti muscles were approximated, the

fascia was repaired with a prolene mesh. A suction drainage was inserted. The skin was closed with continuous suture. The urine in the bladder catheter was clear. The suction drain was held in the wound two days.

The antibiotic prophylaxis was used. The wound healing was normal. The patient was discharged on the fifth day after the surgery.

The material obtained during the surgery – more than ten irregular tissue fragments of total diameter of 10 cm – on the cross-section revealed fat tissue and grey, solid tissue with small, brown spots. The material was referred for histological examination.

Microscopic examination: the tumour consisted of pleomorphic cells with clear cytoplasm, with foci of glands and nests. The tumour infiltrated the adjacent fat tissue. The nuclei varied from follicular to hyperchromatic; necrosis and atypical mitosis figures were found. In the staining against cytokeratin 7 (CK7) the positive reaction was obtained in the carcinoma cells, in the staining against cytokeratin 20 (CK 20), the reaction in the carcinoma cells was negative. The Ki 67 antigen was found focally in 20% of malignant cells.

In the peripheral parts of the tumour, foci of endometriosis with focal cellular atypia were found. To confirm that the observed foci are true endometriosis, ER and CD-10 stainings were performed, giving a positive reaction.

After the surgery, in April 2013, performed in the Cancer Centre and Institute of Oncology in Gliwice, an MR was carried out. The MR examination revealed small hypointensive foci under the uterine mucosa, the foci were enhanced after an injection of contrast medium. Two new foci were found on the border of the cervix and body of the uterus and in the fat tissue in the proximity of the cervix. The picture of endometrium in the MR examination was unequivocal, its contour was uneven and faded. The abrasion of the uterine cavity was carried out; in the abrasion material, endometrial polyps were found.

In June 2013, the radicalized surgery was performed: a fragment of skin, subcutaneous tissue and fascia were excised. In an histological examination, no neoplastic foci were found, only resorption was seen. At present, the patient is prescribed Visane. The PET examination did not reveal any neoplastic foci.

Discussion

Endometriosis is a problem of about 7-15% of women at the child-bearing age [1]. Endometriosis in a caesarean section scar, known as iatrogenic one, was first described in 1942 [5]. In theory, it can arise in every location after any surgical intervention, its incidence in a cc scar is estimated at 1% [6].

In 1925, Sampson first described the theory of retrograde menstruations requisite for the pathogenesis of endometriosis and its malignant transformation into ovarian cancer [7,8]. The endometriosis is correlated with increased risk of ovarian cancer. The research of Brinton et al. revealed increased incidence of ovarian cancer in patients with endometriosis in comparison to the general population [9]. This correlation was found for two histological types of cancer: endometrial and clear cell carcinoma.

Rossing et al. reached a similar conclusion: after investigating a group of 812 women with ovary tumours, they found that the risk of endometrial or clear cell carcinoma is increased 3 times in women with endometriosis [10]. Modesit, investigating a group of 115 cases of endometriosis coexisting with intra-peritoneal carcinomas, found that the most frequent were endometrial and clear cell carcinomas [11]. Obviously, an ovarian carcinoma may arise directly from endometriosis foci, nonetheless the risk of ovarian carcinoma increases also when the endometriosis arises outside the ovary. In a population of women with ovarian carcinoma, endometriosis incidence reaches 8-30% (two times more than in the healthy women population) [1].

A strong correlation between endometriosis and ovarian carcinoma may be explained by two hypotheses: endometriosis implants may undergo malignant transformation – through malignant endometriosis to cancer or/and both cancer and endometriosis have common antecedent mechanisms or predisposing factors. In a study presented by Worley Jr. et al., the role of expression of some transcriptional factors (like HNF-1 β), oxidative stress, some cytokines (TNF- α , IL-1 β , IL-6) and hyperestrogenism in the development of endometriosis as well as ovarian cancer are demonstrated [12].

Obviously, both these hypotheses do not exclude each other.

A histological picture of clear cell carcinoma in our study consists of cuboidal and polygonal cells, containing abundant cytoplasm; the cytoplasm may be granular or eosinophilic. A distinguishing feature is “stab nail” cells, which may create solid fields or cyst-like spaces, and sometimes they build tubular or verrucous structures.

The differential diagnosis should encompass: soft tissue tumours like desmoid, possible metastases to skin and subcutaneous tissue derived from clear cell kidney carcinoma, adrenal cortex carcinoma, melanoma, clear cell carcinoma of pancreas or epithelioid variant of leiomyosarcoma.

Tumours derived from the genital tract are CK7(+), p53(+) and CK20(-), clear cell kidney carcinoma is PAX-8, HNF-1 β , RCC, EMA and CD-10 positive. Melanoma shows positive response with S-100 and HMB-45, adrenal cortex carcinoma is positive in staining against S-100 and inhibin. Clear cell carcinoma derived from pancreas shows positive reaction against CK7, CK18, CEA, HNF-1 β , and, in 50% of cases, against CK20. The epithelioid variant of leiomyosarcoma is SMA positive [12].

Up till now, there have been about 20 cases of malignant transformation of endometriosis into clear cell carcinoma in a cc scar described in the literature. In most cases, after a radical

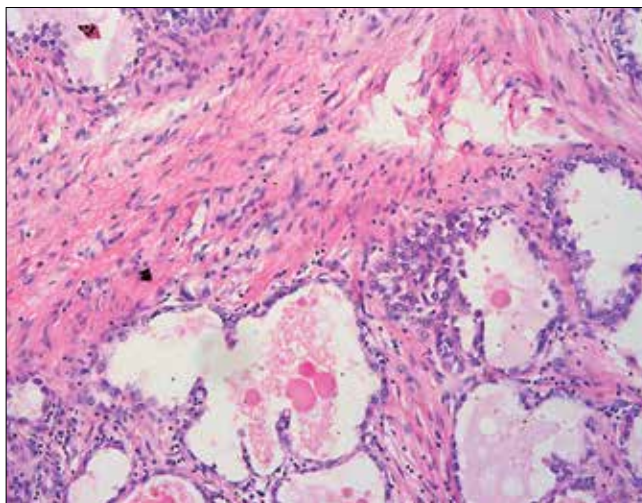


Figure 1. Foci of the clear cell carcinoma (hematoxylin-eosin staining).

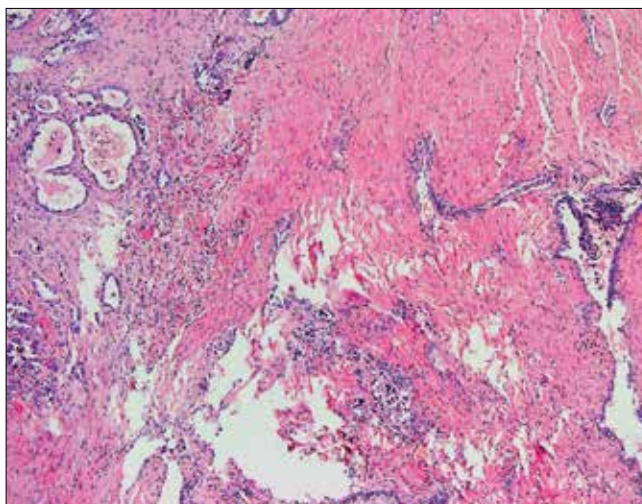


Figure 2. Foci of the clear cell carcinoma- left side and atypical endometriosis- right side (hematoxylin-eosin staining).

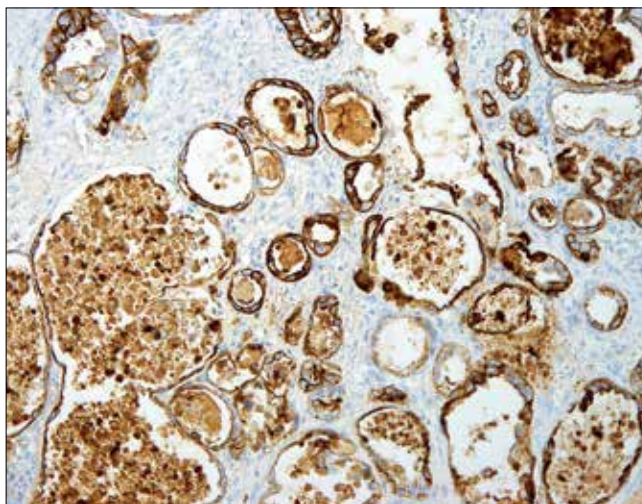


Figure 3. Foci of the clear cell carcinoma (CK-7 staining).

Zuzanna Dobrosz et al. Clear cell carcinoma derived from an endometriosis focus in a scar after a caesarean section – a case report and literature review.

resection of the tumour, adjuvant chemotherapy or adjuvant radiotherapy were applied. Only in few cases, a resection of the tumour, followed by hysterectomy were carried out [13]. Our patient did not have any symptoms for 30 months. Among the remaining patients, of whom the follow-up was available (11 women), 6 died during 20 months, which makes as much as 40% [13-20]. Because of the rarity of these tumours, the optimal therapeutic options have not been established [21].

Summarising, even though endometriosis is a benign lesion, it has many features distinctive for invasive carcinoma; it may itself undergo a malignant transformation as well as increase the risk of endometrial carcinoma or clear cell ovarian carcinoma. Obviously, preventing endometriosis is impossible and pharmacotherapy is often ineffective, nonetheless, with regard to its high incidence (endometriosis occurs in more than 10% of women at the child-bearing age and in about 3% of post-menopausal women), in the group of patients in whom endometriosis is diagnosed, hormonal replacement therapy should not be implemented because of increased risk of ovarian carcinoma and malignant transformation.

Maybe in future, more exhaustive studies will allow establishing a therapeutic protocol in patients with extra-ovarian malignant transformation of endometriosis foci.

Oświadczenie autorów:

1. Zuzanna Dobrosz - autor koncepcji i założeń pracy, przygotowanie manuskryptu – autor zgłaszający i odpowiedzialny za manuskrypt.
2. Piotr Paleń – opis histopatologiczny przypadku.
3. Małgorzata Florczak - zebranie materiału, przeprowadzenie badań.
4. Rafał Stojko – korekta i aktualizacja literatury.
5. Paweł Właszczuk – korekta manuskryptu.
6. Anna Niestuchowska-Hoxha – opracowanie przypadku ;pod względem klinicznym.
7. Ilona Piechuta-Kośmider – opracowanie wyników badań, przechowywanie dokumentacji.

Źródło finansowania:

Praca nie była finansowana przez żadną instytucję naukowo-badawczą, stowarzyszenie ani inny podmiot, autorzy nie otrzymali żadnego grantu.

Konflikt interesów:

Autorzy nie zgłaszają konfliktu interesów oraz nie otrzymali żadnego wynagrodzenia związanego z powstawaniem pracy.

References:

1. Varma R, Rollason T, Gupta JK, Maher ER. Endometriosis and the neoplastic process. *Reproduction*. 2004, 127, 293-304.
2. Corner GW, Hu CY, Hertig AT. Ovarian carcinoma arising in endometriosis. *Am J Obstet Gynecol*. 1950, 59, 760-774.
3. Lauslahti K. Malignant external endometriosis: a case of adenocarcinoma of umbilical endometriosis. *Acta Pathol Microbiol Scand Suppl*. 1972, 233,98-102.
4. Jung-Yun L, Eun Seon I, Sang-Wook K, [et al.]. A case of clear cell carcinoma arising from the endometriosis of the paraovarian cyst. *J Gynecol Oncol*, 2009, 20 (1), 60-62.
5. Greenhill J. Scar endometriosis. *Am J Obstet Gynecol*. 1942, 44 177.
6. Victory R, Diamond MP, Johns DA. Villar's nodule: a case report and systematic literature review of endometriosis externa of the umbilicus. *J Minim Invas Gynecol*. 2007, 14, 23.
7. Sampson JA. Endometrial carcinoma of ovary, arising endometrial tissue in that organ. *Arch Surg*. 1925, 10, 1-72.
8. Brucka A, Szytlo K. Immunoekspresja białka PTEN i metaloproteinazy-2 w torbielach endometrialnych, raku endometrioidalnym i jasnokomórkowym jajnika. *Ginekol Pol*. 2013, 84, 344-351.
9. Brinton LA, Sakoda LC, Sherman ME, [et al.]. Relationship of benign gynecologic diseases to subsequent risk of ovarian et uterine tumours. *Cancer Epidemiol Biomarkers Prev*. 2005, 14, 2929-2935.
10. Rossing MA, Cushing-Haugen KL, Wicklund KG, [et al.]. Risk of epithelial ovarian cancer in relation to benign ovarian conditions and ovarian surgery. *Cancer Causes Control*. 2008, 19, 1357-1364.
11. Modesitt SC, Tortolero-Luna G, Robinson JB, [et al.]. Ovarian and extraovarian endometriosis-associated cancer. *Obstet Gynecol*. 2002, 100, 788.
12. Worley MJ, Welch WR, Berkowitz RS, Ng SW. Endometriosis-associated ovarian cancer: a review of pathogenesis. *Int J Mol Sci*. 2013, 14 (3), 5367-5379. doi: 10.3390/ijms14035367
13. Shalin SC, Haws AL, Carter DG, Zarrin-Khameh NJ. Clear cell adenocarcinoma arising from endometriosis in abdominal wall caesarean section scar: a case report and review of the literature. *J Cutan Pathol*. 2012, 39 (11), 1035-1041.
14. Hitti IF, Glasberg SS, Lubicz S. Clear cell carcinoma arising in extraovarian endometriosis: report of three cases and review of the literature. *Gynecol Oncol*. 1990, 39, 314-320.
15. Schnieber D, Wagner-Kolb D. Malignant transformation of extragenital endometriosis. *Geburtshilfe Frauenheilkd*. 1986, 46 (9), 658-659. [German].
16. Ishida GM, Motoyama T, Watanabe T, Emura I. Clear cell carcinoma arising in a caesarean section scar. Report of a case with fine needle aspiration cytology. *Acta Cytol*. 2003, 47, 1095-1098.
17. Sergeant F, Baron M, Le Cornec JB, [et al.]. Malignant transformation of abdominal wall endometriosis: a new case report. *J Gynecol Obstet Biol Reprod (Paris)*. 2006, 35, 186-190.
18. Razzouk K, Roman H, Chanavaz-Lacheray I, [et al.]. Mixed clear cell and endometrioid carcinoma arising in parietal endometriosis. *Gynecol Obstet Invest*. 2007, 63, 140-142.
19. Williams C, Petignat P, Belisle A, Drouin P. Primary abdominal wall clear cell carcinoma: case report and review of literature. *Anticancer Res*. 2009, 29, 1591-1593.
20. Bourdel N, Durand M, Gimbergues P, [et al.]. Exclusive nodal recurrence after treatment of degenerative parietal endometriosis. *Fertil Steril*. 2010, 93, 2074.
21. Mert I, Semaan A, Kim S, [et al.]. Clear cell carcinoma arising in the abdominal wall: two case reports and literature review. *Am J Obstet Gynecol*. 2012, 207 (2),e7-9. doi: 10.1016/j.ajog.2012.05.029.