

Distal Femoral Epiphyses Ossification Center Diameter and Third Trimester Gestational Age in Iranian Population

Wymiar dystalnego jądra kostnienia w kości udowej w III trymestrze ciąży w populacji Iranu

Shirin Birang¹, Ali Akbar Ameri², Zahra Najmi^{3,4}

¹ Department of Radiology, Shahid Beheshti University of Medical Sciences, Tehran, Iran.

² Department of Radiology, Shahid Beheshti University of Medical Sciences, Tehran, Iran.

³ Department of Obstetrics and Gynecology, Tehran University of Medical Sciences, Tehran, Iran.

⁴ Farzan Clinical Research Institute, Tehran, Iran.

Abstract

Objective: The epiphyses ossification centers appear late in gestation, when traditional biometric measurements are the least accurate, and they can be useful in determining third trimester's gestational age. To evaluate fetal distal femoral epiphysis (DFE) size in various ages of gestation and establish a reference chart for Iranian population.

Materials & Methods: DFE diameter was measured in 1300 normal singleton pregnancies, between 28 and 40 weeks. Mean diameter in each week of gestation was evaluated.

Results: The DFE is not visualized in 28 weeks' gestation. It appeared in a small proportion of the fetuses (5%) as early as the 29th week. DFE was detectable by ultrasonography increased dramatically to 56% at 33 weeks' reaching 94% at 36 weeks and 100% at 37 weeks gestation.

Conclusion: Ultrasonographic visualization of the distal femoral epiphyses ossification center is a useful marker of fetal third trimester's gestational age.

Key words: **distal femoral epiphyses ossification center / DFE /**
/ epiphyses ossification center / fetal bone development /
/ gestational age / ultrasound /

Correspondence author:

Shirin Birang

Department of Radiology, Shahid Beheshti University of Medical Sciences, Tehran, Iran

P.O.Box: 13185-1678, Tehran, Iran

Tel: +9821 66439463, Fax: +9821 66423304

e-mail: swt_f@yahoo.com

Otrzymano: 12.03.2012

Zaakceptowano do druku: 30.11.2013

Shirin Birang et al. *Distal Femoral Epiphyses Ossification Center Diameter and Third Trimester Gestational Age in Iranian Population.*

Streszczenie

Jądra kostnienia pojawiają się późno w ciąży i mogą być przydatne w określaniu wieku ciążowego w trzecim trymestrze ciąży, kiedy tradycyjna biometria płodu jest najmniej dokładna.

Cel pracy: Ocenę wielkości jądra kostnienia kości udowej (DFE) w różnych tygodniach ciąży wykonano w celu ustalenia wartości referencyjnych dla populacji Iranu.

Materiał i metoda: Zmierzono DFE w 1300 pojedynczych ciążach w wieku od 28 do 40 tygodni. Określono średni wymiar dla każdego tygodnia ciąży.

Wyniki: Nie uwidocznilo DFE w 28 tyg. ciąży. Najwcześniej uwidocznilo DFE w 29 tyg. ciąży u niewielkiego odsetka płodów (5%). DFE był mierzalny w ultrasonografii w 56% w 33 tyg. ciąży, w 94% w 36 tyg. ciąży i w 100% w 37 tyg. ciąży.

Wnioski: Uwidocznienie w ultrasonografii jąder kostnienia kości udowej jest przydatnym markerem wieku ciążowego w III trymestrze ciąży.

Słowa kluczowe: **dystalne jądro kostnienia kości udowej / jądro kostnienia /
/ rozwój kości płodu / wiek ciążowy / ultrasonografia /**

Introduction

Various obstetrical management strategies are dependent on knowing accurate gestational age. Crown-rump length (CRL) measured in first trimester, is the most accurate way to gestational dating. Initially all fetuses grow at the same rate, where, as a result of different environmental and genetic factors, the divergence in fetal weight increases as gestation progresses [1].

More recently, Donne and coworkers sought to verify the predictive value of the epiphyses ossification center measurements in estimating gestational age [2]. They confirmed that the presence of the distal femoral epiphysis (DFE) had a positive predictive value of 96% for indicating a pregnancy of at least 32 weeks or greater.

DFE is identified by locating the echogenic epiphyseal structure near the distal end of femur; and its measurement is obtained in an axial plane along the medio-lateral surfaces of the epiphyses from the outer-to-outer margins [3].

The mean age at DFE appearance is 32 to 33 weeks' gestation, and it is not visualized before 28 weeks' gestation [4]. In 94% of fetuses the DFE is observed at 34 weeks' gestation. So if a DFE is not visualized, the fetus is most likely less than 34 menstrual weeks' gestation [4, 5].

Epiphyseal ossification centers appear in late gestational ages, when traditional biometric measurements are not accurate enough. So they can be a useful adjunct in determining gestational age in a pregnancy with unknown dates especially in third trimester.

Reference charts for gestational age according to DFE have been published and are now used widely in some countries [3,6]. As such a reference chart has not been reported in Iranian population yet and considering ethnic differences in fetal growth indexes, present study was conducted to evaluate fetal DFE size in various ages of gestation and establish a reference chart for Iranian population.

Materials and methods

This descriptive study was conducted on 1300 pregnant women undergoing routine ultrasonography during the last trimester of pregnancy in university hospitals related to Shahid Beheshti University of Medical Sciences. The study was reviewed and approved by the ethics committee of the University and written informed consent was obtained from all participants.

Participants were selected among women with normal singleton pregnancies, with gestational age of 28 to 40 weeks, who had no fetal abnormalities on first and second trimesters' ultrasound examination. To be included in the study, women also had to be sure of the date of their last menstrual period and to have had this date confirmed by ultrasonography during the first trimester of pregnancy. Patients with any underlying chronic diseases such as diabetes, renal failure and hypertension were excluded from study.

All ultrasound examinations were performed by two expert radiologists with ultrasound diagnostic scanner model EZU MT19 - S1- made in Japan- with a 5 MHZ convex array transducer. One hundred samples were examined for each of the 13 gestational ages from 28 to 40 weeks, and only one observation was included for each fetus.

Distal femoral epiphyseal ossification center (DFE) was identified as a slit like ovoid or globular echogenic structure centrally placed within the hypoechogenic epiphyseal cartilage of the femur at its distal extremity. Measurements were obtained from the outer-to-outer margins in an axial plane along the medio-lateral surfaces of the epiphyses (Figures 1, 2). Once the DFE was identified, the measurement was repeated 3 times, and the largest diameter obtained was recorded.

The data were collected at the end of each examination on a form specially designed for this study. For each week of gestational age, the mean diameter of the DFE was measured. A normogram with the values of mean DFE was constructed for each week of gestational age by adjusting the data using multiple linear regression and controlling for gestational age. The significance level set at 0.05.

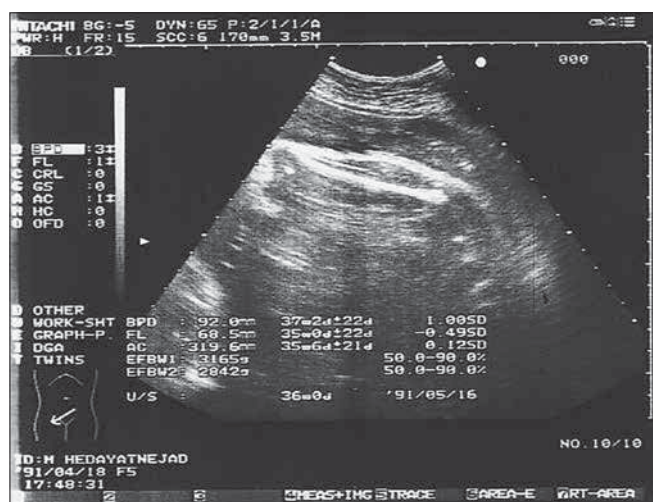


Figure 1. Fetal distal femoral epiphysis size measurement from the outer-to-outer margins in an axial plane of epiphyses.

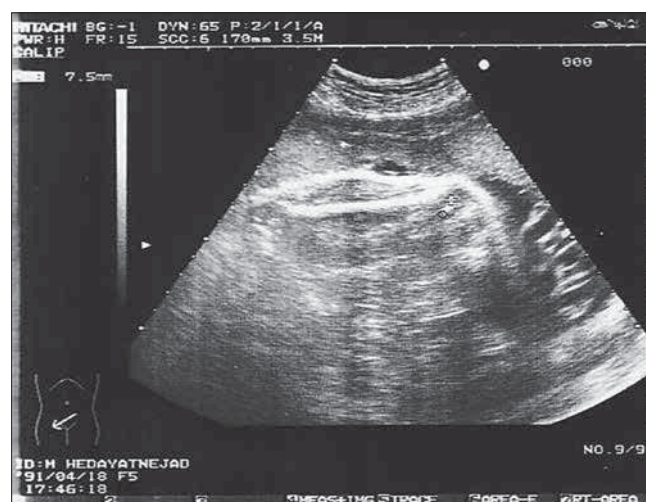


Figure 2. Fetal distal femoral epiphysis size measurement in an axial plane from the medio-lateral surfaces of the epiphyses.

Results

Analysis was performed on the date of 1300 fetus between 28 to 40 weeks of gestation, 100 for each week, with mean maternal age of 23.5 ± 5.1 years (Table 1).

The distal femoral epiphysis (DFE) is not visualized in 28 weeks' gestation. It appeared in a small proportion of the fetuses (5 of 100, 5%) as early as the 29th week. The proportion of fetuses in which the DFE was detectable by ultrasonography increased dramatically to 56% at 33 weeks' reaching 94% at 36 weeks, and 100% at 37 weeks gestation (Table 1).

Reference chart for gestational age according to DFE is summarized in Table 2. Mean DFE diameter in 29 th week was 0.08 ± 0.37 mm. The diameter increases with increment of gestational age in a way, that fetus with $DFE \geq 3$ are almost always ≥ 33 weeks of gestation and fetuses with $DFE \geq 7$ are almost always ≥ 36 weeks of gestation. Mean DFE diameter in 33 th and 37 th weeks were 1.26 ± 1.25 and 4.20 ± 1.51 mm, respectively.

According to our chart third trimester's gestational age can be estimated by DFE diameter, table 3 (correlation coefficient= 0.8). With DFE diameter of 0, 5 and 9 mm estimated gestational age would be 30.42 ± 1.94 , 37.25 ± 1.71 and 39.75 ± 0.44 , respectively.

Table 1. Distribution of gestational age according to DFE diameter.

DFE(mm) GA(w)	0	1	2	3	4	5	6	7	8	9	
28	100										100
29	95	2	3								100
30	85		15								100
31	81	4	15								100
32	72		28								100
33	44		50		4	2					100
34	15		65	3	7	7	3				100
35	12		68		12	8					100
36	6		30	22	17	11	5	9			100
37			16	18	27	16	15	8			100
38			3	4	12	30	34	10	7		100
39				6	9	16	20	29	13	7	100
40						6	18	32	23	21	100

DFE: distal femoral epiphyseal ossification center, GA: gestational age.

Table II. Mean DFE diameter in various gestational ages.

Gestational age (w)	DFE Diameter (mean±2SD)
28	0
29	0.08±0.37
30	0.30±0.72
31	0.34±0.73
32	0.56±0.91
33	1.26±1.25
34	2.20±1.45
35	2.42±1.28
36	3.42±1.78
37	4.20±1.51
38	5.46±1.31
39	6.24±1.57
40	7.35±1.17

DFE: distal femoral epiphyseal ossification center, GA: gestational age.

Table III. Mean gestational age according to DFE diameter.

DFE Diameter (mm)	Gestational age (mean±2SD)
0	30.42±1.94
1	30.33±1.03
2	33.87±1.83
3	36.71±1.18
4	36.45±1.56
5	37.25±1.71
6	38.20±1.34
7	38.76±1.31
8	39.37±0.75
9	39.75±0.44

DFE: distal femoral epiphyseal ossification center, GA: gestational age.

Discussion

We could define a reference chart for estimating of third trimester's gestational age according to DFE diameter, for the first time in Iranian population.

The results of this study indicate that the DFE ossification center diameter varies greatly, as is seen in the case of other anthropometric indicators. But their presence or absence can be useful in drawing some specific and critical assumptions with regard to gestational age.

In 28th week of gestation DFE would not be visualized in ultrasound examination, when DFE ≥3 fetus is almost always ≥33 weeks of gestation and fetus with DFE ≥7 is almost always ≥36 weeks of gestation.

Donne [2] in a study on 3 ossification centers in Brazil showed that, Ultrasonographic visualization of the epiphyses ossification centers may be a useful marker of fetal gestational age. In their population the DFE appeared in a small proportion of the fetuses (6 of 36, 17%) as early as the 30th week compared with 29 week in our population.

DFE was detectable by ultrasonography in 71% at 32 week. Where in 72% of our 32 week study population DFE was not visible by ultrasound, yet. In their population DFE was detectable in 100% of fetuses at 37 weeks gestation, just as ours.

In line with our results, it has previously shown that the DFE is not visualized before 28 weeks' gestation in American population and the mean age at DFE appearance is 32 to 33 weeks' gestation [4]. If a DFE is not visualized, the fetus is most likely less than 34 menstrual weeks' gestation as the DFE is observed in 94% of fetuses at 34 weeks' gestation [4, 5].

Moreover, a DFE of 3 mm or more is associated with a gestational age of greater than 37 weeks in 84% of fetuses [5]. It is comparable with the mean gestational age 36.71 in our population.

WU [6] has also reported that, 29 weeks gestation for first appearance of DFE in Chinese. However the DFE was detectable in 100% of fetuses at the end of 34 week, compared with 37 week in our population.

The measurement of epiphyses ossification centers of long bones as markers of gestational age using radiography was first described 50 years ago. These studies were based on the findings of maternal abdominal x-rays carried out during pregnancy [1–4] and on x-rays of neonatal extremities [2]. However, the fear of exposing the fetus to radiation, the technical problems involved in visualizing the epiphyses ossification centers, and the large variability in the figures obtained led to the discontinuation of this method for determination of gestational age. The advent of ultrasonography, however, solved most of the technical problems encountered with radiography and eliminated the fear of fetal radiation [2]. Ultrasound is able to identify each epiphyses ossification center at a much earlier stage, as long as the diameter is at least 1 mm [7].

Crown–rump length (CRL) measured in first trimester, is the most accurate way to gestational dating. Initially all fetuses grow at the same rate, where, as a result of different environmental and genetic factors, the divergence in fetal weight increases as gestation progresses [1].

As the epiphyseal ossification centers appear late in gestation, when traditional biometric measurements are the least accurate, they are a useful adjunct in determining gestational age and evaluating for IUGR in a pregnancy with unknown dates. Correlations have been also observed between ossification of the fetal long bones, as detected sonographically, and fetal lung maturity [8].

It is possible to postulate that the identification and measurements of the ossification centers may be less influenced by fetal growth restriction or excessive growth than other

anthropometric measurements, whereas a deficit in calcium metabolism may occasionally delay the appearance of the ossification centers.

There is ample space for further research into the possible usefulness of the ultrasonographic visualization of the DFE as markers of fetal development and gestational age, not only during normal pregnancy but also in the presence of a number of conditions known to affect fetal growth and development. Future studies may also focus on validation of this chart with report of its positive and negative predictive values in various populations.

Acknowledgment

The authors would like to thank Farzan Institute for Research and Technology for technical assistance.

References

1. Gottlieb AG, Galan HL. Nontraditional sonographic pearls in estimating gestational age. *Semin Perinatol.* 2008, 32 (3), 154-160.
2. Donne HD Jr, Faúndes A, Tristão EG, [et al.]. Sonographic identification and measurement of the epiphyseal ossification centers as markers of fetal gestational age. *J Clin Ultrasound.* 2005, 33 (8), 394-400.
3. Reece EA, Goldstein I, Hobbins JC. *Fundamentals of Obstetric and Gynecologic Ultrasound.* Norwalk, CT, Appleton and Lange, 1994.
4. Mahony BS, Callen PW, Filly RA. The distal femoral epiphyseal ossification center in the assessment of third-trimester menstrual age: sonographic identification and measurement. *Radiology.* 1985, 155 (1), 201-204.
5. Goldstein I, Lockwood C, Belanger K, Hobbins J. Ultrasonographic assessment of gestational age with the distal femoral and proximal tibial ossification centers in the third trimester. *Am J Obstet Gynecol.* 1988, 158 (1), 127-130.
6. WU X, Sun Z, Yang T. The secondary ossification centers of fetus. *Hua Xi Yi Ke Da Xue Xue Bao.* 1996, 27 (2), 160-162.
7. Mahony BS, Callen PW, Filly RA. The distal femoral epiphyseal ossification center in the assessment of third-trimester menstrual age: sonographic identification and measurement. *Radiology.* 1985, 155 (1), 201-204.
8. Gentili P, Trasimeni A, Giorlandino C. Fetal ossification centers as predictors of gestational age in normal and abnormal pregnancies. *J Ultrasound Med.* 1984, 3 (5), 193-197.

Authors' Contribution:

1. Shirin Birang – assumption, acquisition of data, statistics, drafting article, approving final version, corresponding author.
2. Ali Akbar Ameri – acquisition of data, analysis of data, drafting article.
3. Zahra Najmi – study design, acquisition of data, drafting article.

Authors' statement:

- This is to certify, that the publication will not violate the copyrights of a third party, as understood according to the Act in the matter of copyright and related rights of 14 February 1994, Official Journal 2006, No. 90, Clause 63, with respect to the text, data, tables and illustrations (graphs, figures, photographs);
- there is no 'conflict of interests' which occurs when the author remains in a financial or personal relationship which unjustly affects his/her actions associated with the publication of the manuscript;
- any possible relationship(s) of the author(s) with the party/parties interested in the publication of the manuscript are revealed in the text of the article;
- the manuscript has not been published in or submitted to any other journal.

Source of financing:

None.