

Usefulness of three dimensional transvaginal ultrasonography and hysterosalpingography in diagnosing uterine anomalies

Przydatność trójwymiarowej ultrasonografii dopochwowej oraz histerosalpingografii w diagnostyce wad macicy

Piotr Szkodziak¹, Sławomir Woźniak¹, Piotr Czuczwar¹, Tomasz Paszkowski¹, Paweł Milart¹, Ewa Woźniakowska¹, Wojciech Szlichtyng²

¹ 3rd Chair and Department of Gynecology, Medical University of Lublin, Lublin, Poland

² Department of Obstetrics and Gynecology, Hospital in Świdnik, Świdnik, Poland

Abstract

Introduction: Uterine anomalies may lead to infertility, recurrent miscarriage, preterm labour, intrauterine growth restriction and post-partum haemorrhage. Infertility and recurrent miscarriage are relatively common problems in the female population. Diagnostic algorithms in such cases include the evaluation of uterine anatomy.

Magnetic resonance imaging (MRI) is the most accurate technique for visualizing the female genitourinary tract anatomy, but as it is expensive and not readily available, it is not useful in everyday practice.

Hysterosalpingography (HSG) is a frequently performed procedure that plays an important role in evaluating the uterus and fallopian tubes. The most typical indication for HSG is infertility and recurrent miscarriage, which are common problems in the female population. However, this procedure is invasive, exposes the patient to ionizing radiation, carries a risk of complications and does not show the external contour of the uterus, which is essential for differentiating uterine anomalies. Three dimensional transvaginal ultrasound (3D TV USG) is a noninvasive and quick, imaging method that may be used in diagnosing uterine anomalies. This method allows evaluate the external contours of the uterus, making it comparable to MRI.

Objective and methods: In this study we discuss the advantages and disadvantages of HSG and 3D TV USG in diagnosing uterine anomalies. Additionally we present the results of HSG and 3D TV USG of 155 patients referred to our Department because of infertility and/or suspected uterine anomalies.

Results: After performing HSG, in the studied group 118 patients were diagnosed with a normal uterus, 4 with unicornuate (including 1 patient with an unicornuate uterus, with rudimentary horn), and 6 with didelphys uterus. In 22 cases, due to the lack of evaluation of external contour of the uterus, we could not differentiate arcuate, septate and bicornuate uterus. After performing 3D TV USG we confirmed the HSG diagnosis and precise differentiated 22 disputable cases: 8 with arcuate, 11 with septate (2 complete and 9 partial) and 3 with complete bicornuate uterus. In 5 patients, severe pain and lack of cooperation during HSG made the acquisition of diagnostic X-ray images impossible. In these cases 3D TV USG allowed the anatomic assessment of the uterus, a normal uterus was found in all of them. All uterine anomalies were then confirmed by hysteroscopy and/or laparoscopy.

Corresponding author:

Piotr Szkodziak
Medical University of Lublin, 3rd Chair and Department of Gynecology
20-954 Lublin, ul. Jaczewskiego 8, Poland
phone: +48817244848; mobile phone: +48605585788
e-mail: piotr.szkodziak@gmail.com;

Otrzymano: 26.09.2013
Zaakceptowano do druku: 15.12.2013

Piotr Szkodziak et al. Usefulness of three dimensional transvaginal ultrasonography and hysterosalpingography in diagnosing uterine anomalies.

Conclusions: *Basing on a review of the literature and our results, we conclude that HSG is not the optimal method for diagnosing uterine anomalies, while 3D TV USG can accurately show the uterus anomalies and may become an alternative method to MRI.*

Key words: **three dimensional transvaginal ultrasound / hysterosalpingography / uterine anomalies /**

Streszczenie

Wstęp: *Wady macicy mogą prowadzić do niepłodności, poronień nawykowych, porodu przedwczesnego, wewnątrzmacicznego ograniczenia wzrostu płodu oraz krwotoków poporodowych. Niepłodność i poronienia nawykowe są stosunkowo częstym problemem w populacji kobiet. Algorytmy diagnostyczne w takich przypadkach obejmują ocenę budowy anatomicznej macicy.*

Obrazowanie metodą rezonansu magnetycznego (MRI) jest najbardziej dokładną techniką wizualizacji anatomii żeńskich narządów moczowo-płciowych, ale jest kosztowne i niełatwo dostępne. Nie jest więc przydatna w codziennej praktyce lekarskiej.

Histerosalpingografia (HSG) jest często wykonywaną procedurą, która odgrywa ważną rolę w ocenie jamy macicy oraz jajowodów. Najbardziej typowym wskazaniem do HSG to jest niepłodność i poronienia nawykowe, które stanowią częsty problem w populacji kobiet. Jednak jest to procedura inwazyjna, naraża pacjentki na promieniowanie jonizujące, także niesie ze sobą ryzyko powikłań. Metoda ta nie obrazuje zewnętrznego konturu macicy, co jest niezbędne do różnicowania wad macicy. Trójwymiarowa ultrasonografia dopochwowa (3D TV USG) jest szybkim i nieinwazyjnym sposobem obrazowania, który może być stosowany w diagnostyce wad macicy. Metoda ta pozwala także na ocenę zewnętrznych obrysów macicy, porównywalnie do MRI.

Cel pracy, materiał i metody: *W publikowanym badaniu omówiono zalety i wady HSG oraz 3D TV USG w diagnostyce wad macicy. Dodatkowo zaprezentowano wyniki HSG i 3D TV USG u 155 pacjentek, hospitalizowanych z powodu niepłodności i/lub podejrzenia wady macicy.*

Wyniki: *Po wykonaniu HSG, w badanej grupie u 118 pacjentek potwierdzono prawidłową budowę jamy macicy, u 4 macicę jednorożną (w tym u 1 pacjentki z rogiem szczątkowym), a 6 macicę podwójną. W 22 przypadkach, ze względu na brak możliwości oceny zewnętrznego konturu macicy, nie można było różnicować macicy łukowatej, macicy z przegrodą oraz dwurożnej. Po wykonaniu 3D TV USG potwierdzono diagnozę postawioną po badaniu HSG i precyzyjnie różnicowano 22 przypadki wątpliwe: 8 pacjentek z macicą łukowatą, 11 z przegrodą w macicy (2 całkowite i 9 częściowych) oraz 3 z macicą dwurożną. U 5 pacjentek, silny ból oraz brak współpracy w trakcie wykonania HSG uniemożliwiły uzyskanie czytelnych, nadających się do postawienia diagnostyki obrazów rentgenowskich. W tych przypadkach 3D TV USG umożliwiło ocenę anatomiczną macicy, jako prawidłową w każdym z nich. Wszystkie rozpoznane wady potwierdzono następnie wykonując zabieg histeroskopii i/lub laparoskopii.*

Wnioski: *Na podstawie przeglądu piśmiennictwa oraz uzyskanych przez nas wyników, możemy stwierdzić, że HSG nie jest optymalną metodą diagnozowania wad macicy, natomiast korzystając z 3D TV USG można dokładnie je rozpoznać. Także 3D TV USG może stać się alternatywną metodą dla MRI.*

Słowa kluczowe: **trójwymiarowa ultrasonografia / histerosalpingografia / wady macicy /**

Introduction

Uterine anomalies may lead to infertility, recurrent miscarriage, preterm labour, intrauterine growth restriction and post-partum haemorrhage. Infertility and recurrent miscarriage are relatively common problems in the female population. Diagnostic algorithms in such cases include the evaluation of uterine anatomy. This is usually achieved by hysterosalpingography (HSG). If HSG leads to the suspicion of uterine anomaly, then laparoscopy and/or hysteroscopy may be indicated. As endoscopic procedures are invasive, expensive, and carry a risk of complications, they should be performed only in carefully selected cases.

Other imaging modalities include ultrasonography and magnetic resonance imaging (MRI). Although these techniques are not useful in assessing fallopian tubes patency, they provide exceptionally good quality images of the uterus. Due to its costs, MRI is not useful as a routine examination. 3D TV USG seems to be a promising tool in diagnosing uterine anomalies, as it is non-invasive, and its availability is increasing. Moreover, exposure to ionizing radiation may be avoided. The major disadvantage of this technique is the inability to assess fallopian tubes patency. However, in some cases such assessment is not necessary (recurrent miscarriage, postoperative evaluation of the uterus).

Aim of the study

The aim of the study was to assess the usefulness 3D TV USG and HSG in diagnosing uterine anomalies, based on a review of the literature and our results.

Materials and methods

Patients

One hundred and fifty five patients referred to 3rd Chair and Department of Gynecology, Medical University of Lublin, Poland (Teaching Hospital No. 4) because of infertility and/or suspected uterine anomalies were included in the study. The patients were admitted in the first 3 days after completions of their menses. HSG and 3D TV USG were performed by experienced physicians. Uterine anomalies were classified on the basis of the American Fertility Society Classification (I-VII) [18, 24]. Diagnoses obtained using HSG and 3D TV USG were subsequently compared.

The study protocol has received a positive opinion of the Bioethics Committee (No. KE-0254/147/2010) and we have received informed consent from each patients to participate in our study.

Hysterosalpingography

During HSG an iodinated contrast agent (76% Urografin, Bayer) was administered through a catheter into the uterine cavity and fallopian tubes, while a series of X-Ray images were performed by experience gynecologist.

As HSG is poorly effective in differentiating bicornuate, septate and arcuate uterus [1,16], we have decided to classify the obtained images into the following groups:

- Group 1: Normal uterine cavity
- Group 2: Unicornuate uterus (AFS category II)
- Group 3: Didelphys uterus (AFS category III)
- Group 4: Bicornuate uterus, septate uterus and arcuate uterus (AFS categories IV, V and VI)
- Group 5: Other (AFS categories I and VII)

Three dimensional transvaginal ultrasonography (3D TV USG).

All ultrasound examination were performed on Medison V20 Prestige equipped with a 3D volume transvaginal transducer, by experience sonographers.

In 3D TV USG a two dimensional sagittal image of the uterus was first obtained. Then the transvaginal transducer performed a sweep of sections acquiring a volume. From this volume three dimensional images of the uterus could be created from practically any angle. In diagnosing uterine anomalies the coronal view of the uterus is the most valuable. To obtain the coronal view, we used the ultrasound scanner software 3DXI-Oblique View in Contour Mode. After manually drawing a line through the middle of the endometrium the software automatically rendered the coronal view of the uterus. 3D TV USG coronal images of the uterus obtained in this study were similar to HSG X-ray scans, also made possible to evaluate the external contour of the uterus, and allowed the use of American Fertility Society Classification (I-VII).

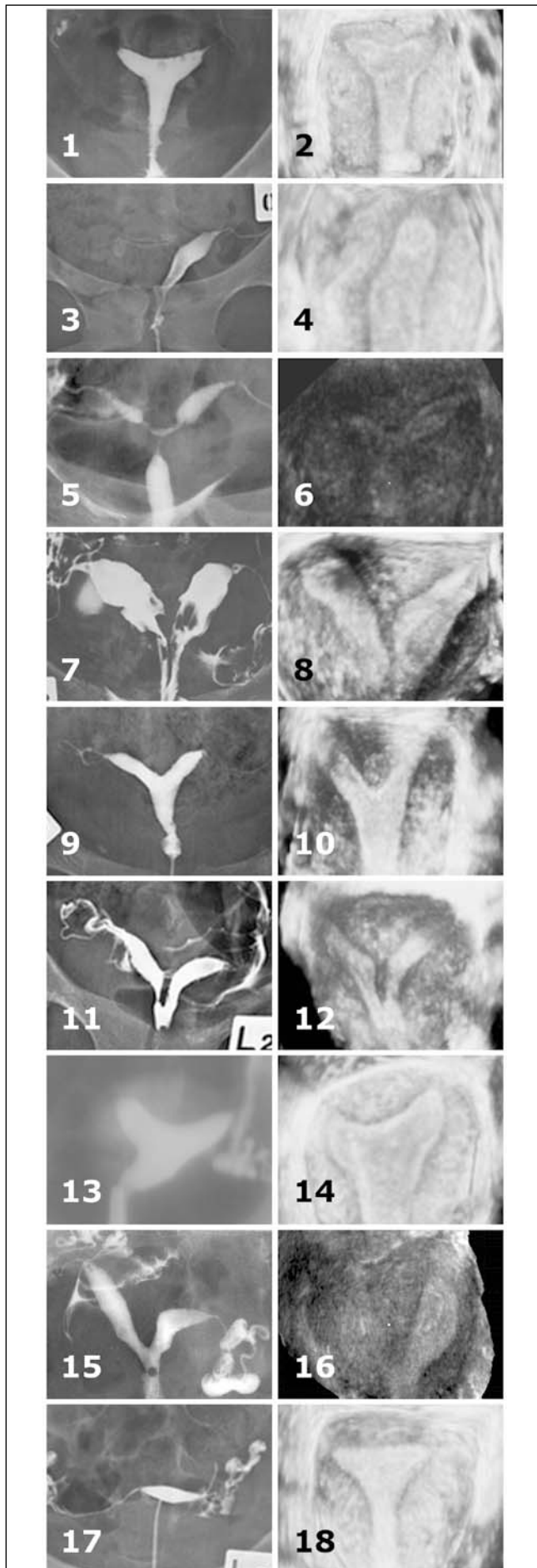
The uterus is best visualized during the secretory phase of the menstrual cycle, when the endometrium is well developed. However, due to the technical aspects of this study (3D TV USG concurrent with HSG), we performed 3D TV USG in the proliferative phase of the cycle, obtaining good quality images.

Results

After HSG 118 patients were diagnosed to have a normal uterus (Group 1) (Figure 1/1 and 2), 4 with unicornuate uterus (including 1 patient with an unicornuate uterus, with rudimentary horn) (Group 2) (Figure 1/3-6), 6 with didelphys uterus (Group 3) (Fig. 1/7 and 8), and 22 patients were classified into Group 4 (AFS categories IV, V and VI). In all cases, HSG diagnoses were consistent with 3D TV USG findings. In contrast to HSG, 3D TV USG allowed precise differentiation of Group 4 anomalies: 9 patients were diagnosed with partial septate uterus (Figure 1/9 and 10), 2 patients with complete septate uterus (Figure 1/11 and 12), 8 with arcuate uterus (Figure 1/13 and 14) and 3 patients with complete bicornuate uterus (Figure 1/15 and 16).

Table I. Results of HSG and 3D TV USG present the anomaly of the uterus.

RESULTS	HSG		3D TV USG		
	N	%	N	%	
NORMAL UTERUS	118	78,7	123	79,3	
AFS II (IIa)	4 (1)	2,7 (0,6)	4 (1)	2,6 (0,6)	
AFS III	6	4,0	6	3,9	
AFS IV a	22	14,7	3	1,9	
AFS V			AFS V a	2	1,3
			AFS V b	9	5,8
AFS VI			8	5,2	
NON DIAGNOSTIC IMAGES	5	3,2	0	0,0	
TOTAL DIAGNOSTIC IMAGES	150	96,8	155	100,0	
TOTAL UTERUS ANOMALIES	32	21,3	32	20,6	
TOTAL	155	100,0	155	100,0	

**Figure 1.**

- Fig. 1/1. HSG image of a normal uterus.
 Fig. 1/2. 3D TV USG image of a normal uterus.
 Fig. 1/3. HSG image of an unicornuate uterus.
 Fig. 1/4. 3D TV USG image of an unicornuate uterus.
 Fig. 1/5. HSG image of an unicornuate uterus with rudimentary horn.
 Fig. 1/6. 3D TV USG image of an unicornuate uterus with rudimentary horn.
 Fig. 1/7. HSG image of didelphys uterus.
 Fig. 1/8. 3D TV USG image of didelphys uterus.
 Fig. 1/9. HSG image of partial septate uterus.
 Fig. 1/10. 3D TV USG image of partial septate uterus.
 Fig. 1/11. HSG image of complete septate uterus.
 Fig. 1/12. 3D TV USG image of complete septate uterus.
 Fig. 1/13. HSG image of arcuate uterus.
 Fig. 1/14. 3D TV USG image of arcuate uterus.
 Fig. 1/15. HSG image of complete bicornuate uterus.
 Fig. 1/16. 3D TV USG image of complete bicornuate uterus.
 Fig. 1/17. Non-diagnostic HSG image.
 Fig. 1/18. 3D TV USG showed a normal uterus in patient presented in Fig. 1/17.

Finally, all anomalies were confirmed by hysteroscopy and/or laparoscopy. In five patients, severe pain and lack of cooperation during HSG made the acquisition of diagnostic X-ray images impossible (Figure 1/17). In these patients 3D TV USG allowed the anatomic assessment of the uterus, a normal uterus was found in all of them (Figure 1/18). The results of HSG and 3D TV USG are summarized in Table I.

Discussion

Infertility, recurrent miscarriage, preterm labour, intrauterine growth restriction and post-partum haemorrhage may result from congenital uterine anomalies [2]. Many various classifications have been proposed to describe Mullerian Duct Anomalies. The AFS classification, originally proposed by Buttram and Gibbons in 1979 [3], is the most widely used. Reported prevalence of uterine anomalies varies from 0.16% to 10% [6, 26]. In a recent critical review [6, 21], the prevalence of congenital uterine anomalies was evaluated to be 6.7% in the general population, 7.3% in the infertile population, and 16.7% in the recurrent miscarriage population. Interestingly, the most common anomaly in the infertile population was the septate uterus, while in the general and recurrent miscarriage population – arcuate uterus.

In our study, uterus anomalies were diagnosed in 20.6% of patients: unicornuate uterus in 2.6% (0.6% unicornuate uterus, with rudimentary horn), didelphys uterus in 3.9%, complete bicornuate uterus in 1.9%, septate uterus in 7.1% (complete 1.3%, partial 5.8%) and arcuate uterus in 5.2% (Table I).

HSG is a widely accepted and available diagnostic procedure that was first performed almost one hundred years ago [5].

Among many indications for HSG the most typical is the assessment of infertility. HSG is also performed in women with a history of recurrent abortions. Sometimes HSG is used in postoperative evaluation of patients who underwent surgery of the uterus or the fallopian tubes. Preoperative assessment of leiomyomas constitutes another indication for HSG. Some authors claim that HSG may have a therapeutic value [9, 23], although this remains a matter of controversy.

HSG, as an invasive procedure, carries a risk of complications, such as bleeding, spotting, peritoneal irritation and infection. To

Piotr Szkodziak et al. Usefulness of three dimensional transvaginal ultrasonography and hysterosalpingography in diagnosing uterine anomalies.

minimize the risk of infection sterile or disposable instruments should be used, which increases the cost of the procedure. Another disadvantage of HSG is the fact that the procedure is painful in more than half of the patients [8]. The pain is usually described as cramping, and typically is minor and transient. Patients are advised to take a nonsteroidal anti-inflammatory drug 1-hour before the procedure to decrease the pain. Perforation of the uterus may also occur, but this complication is extremely rare [22]. Allergic reactions to the contrast agent should also be considered [15], however use of modern low-osmolar non-ionic contrast agents made them very infrequent. Exposure to ionizing radiation has to be noted, especially in the context of infertility in young females. The risk of irradiating early pregnancy is minimized by executing the examination immediately after menses and performing pregnancy tests in case of doubts.

At the moment HSG remains the best imaging modality for assessing the fallopian tubes, even though other methods were introduced. Although hysterosalpingo-contrast sonography [10,19] allows the assessment of tubal patency by using ultrasound contrast agents, this technique is not widely used, since it does not show the entire tube and has no significant advantage over HSG. MRI hystero-graphy with a heavily T2-weighted sequence has also been proposed to evaluate the fallopian tubes [20]. Unfortunately, MR equipment does not usually provide sufficient image resolution to visualize normal fallopian tubes [7]. In cases where the tubes can be visualized, the assessment of tubal patency still requires the administration of saline solution through a catheter positioned in the cervix.

HSG allows the assessment of the uterine cavity, but not the external contour of the uterus. According to a recent review [21], the weighted mean of sensitivity and specificity of HSG in diagnosing congenital uterine anomalies is respectively 78% and 90%. Moreover, this procedure does not allow accurate differentiation of congenital anomalies [1,16].

MRI is an excellent, non-invasive technique of imaging various pelvic anomalies. Both the internal and the external contour of the uterus may be assessed. Accuracies of up to 100% have been reported [14]. Unfortunately, the examination is expensive, not readily available and long lasting. Moreover, it is not suitable for overweight, claustrophobic or pacemaker implanted patients [14]. Due to these disadvantages, MRI is not useful for routine practice.

TV USG is a non-invasive, widely available diagnostic technique. Even classical 2D TV USG shows specificity above 90%, and sensitivity below 60% in detecting uterine anomalies [21]. Unfortunately, there are no universally accepted of ultrasound criteria in differentiating uterine anomalies, with various authors proposing their own ones [4, 11, 25, 26, 27]. Introduction of 3D ultrasonography created new possibilities in imaging uterine anomalies.

3D TV USG allows the assessment of not only the uterine cavity, but also its external contour, which is essential for differentiating uterine anomalies. 100% sensitivity, specificity, PPV and NPV have been reported [12, 13, 17, 27]. In our study, all anomalies diagnosed by 3D TV USG were also confirmed by hysteroscopy and/or laparoscopy. Additionally, 3D TV USG allowed the acquisition of diagnostic images in cases where HSG was not possible to perform.

Our results show, that 3D TV USG is much more effective than HSG in diagnosing uterine anomalies. Moreover, 3D TV USG allows precise differentiation of these anomalies, as a result of the external contour of the uterus assessment. 3D TV USG is non-invasive, and does not require radiation exposure. Needless to say that HSG remains the procedure of choice, in cases, where the evaluation of tubal patency is necessary.

Our experience shows, that 3D TV USG may replace HSG in diagnosing uterine anomalies in cases that do not require concurrent assessment of the fallopian tubes.

Oświadczenie autorów

1. Piotr Szkodziak – autor koncepcji i założeń pracy, przygotowanie manuskryptu, rycin i piśmiennictwa, zebranie materiału, analiza statystyczna wyników – autor zgłaszający i odpowiedzialny za manuskrypt.
2. Sławomir Woźniak – zebranie materiału, analiza statystyczna wyników, przygotowanie manuskryptu.
3. Piotr Czuczwar – współautor tekstu pracy, współautor protokołu, korekta i aktualizacja literatury.
4. Tomasz Paszkowski – autor założeń pracy, analizy i interpretacji wyników, korekta i akceptacja ostatecznego kształtu manuskryptu.
5. Paweł Milart – ostateczna weryfikacja i akceptacja manuskryptu.
6. Ewa Woźniakowska – zebranie materiału.
7. Wojciech Szlichtyng – zebranie materiału.

Źródło finansowania:

Praca nie była finansowana przez żadną instytucję naukowo-badawczą, stowarzyszenie ani inny podmiot, autorzy nie otrzymali żadnego grantu.

Konflikt interesów:

Autorzy nie zgłaszają konfliktu interesów oraz nie otrzymali żadnego wynagrodzenia związanego z powstawaniem pracy.

References

1. Alborzi S, Dehbashi S, Khodaei R. Sonohysterosalpingographic screening for infertile patients. *Int J Gynaecol Obstet.* 2003, 82, 57–62.
2. Braun P, Grau FV, Pons RM, Enquix DP. Is hysterosalpingography able to diagnose all uterine malformations correctly? A retrospective study. *Eur J Radiol.* 2005, 53 (2), 274–279.
3. Buttram VC Jr, Gibbons WE. Mullerian anomalies: a proposed classification. (An analysis of 144 cases). *Fertil Steril.* 1979, 32, 40–46.
4. Fedele L, Dorta M, Brioschi D, [et al.]. Magnetic resonance evaluation of double uteri. *Obstet Gynecol.* 1989, 74, 844–847.
5. Golan A, Langer R, Bukovsky I, Caspi E. Congenital anomalies of the Mullerian system. *Fertil Steril.* 1989, 51, 747–755.
6. Gruszka M, Wilczyński J, Nowakowska D. Prevalence of uterine malformations and their impact on fertility. *Ginekol Pol.* 2012, 83, 517–521.
7. Hagspiel KD, Altas TA, Mugler JP, Brookeman JR. Magnetic resonance hystero-graphy and hysterosalpingography using hyperpolarized (3)He: demonstration of feasibility in an animal model. *J Magn Reson Imaging.* 2000, 12 (6), 1009–1013.
8. Homer HA, Li TC, Cooke ID. The septate uterus: a review of management and reproductive outcome. *Fertil Steril.* 2000, 73, 1–14.
9. Johnson NP, Hadden WE, Chamley LW. Fertility enhancement by hysterosalpingography with oil-soluble contrast media: Reality not myth. (letters) *AJR.* 2005, 185, 1654–1657.
10. Killick SR. Hysterosalpingo contrast sonography as a screening test for tubal patency in infertile women. *J R Soc Med.* 1999, 92 (12), 628–631.

Piotr Szkodziak et al. *Usefulness of three dimensional transvaginal ultrasonography and hysterosalpingography in diagnosing uterine anomalies.*

11. Letterie GS. Structural abnormalities and reproductive failure: Effective techniques of diagnosis and management. New York: *Blackwell Science*, 1998.
12. Makris N, Kalmantis K, Skartados N, Papadimitriou A, [et al.]. Three-dimensional hysterosonography versus hysteroscopy for the detection of intracavitary uterine abnormalities. *Int J Gynaecol Obstet*. 2007a, 97, 6-9.
13. Makris N, Skartados N, Kalmantis K, [et al.]. Evaluation of abnormal uterine bleeding by transvaginal 3-D hysterosonography and diagnostic hysteroscopy. *Eur J Gynaecol Oncol*. 2007b, 28, 39-42.
14. Olpin JD, Heilbrun M. Imaging of Müllerian duct anomalies. *Clin Obstet Gynecol*. 2009, 52 (1), 40-56.
15. Ott DJ, Favez JA, Chen MYM. Techniques of hysterosalpingography. In: *Hysterosalpingography: a text and atlas*. 2nd ed. Baltimore, Md: *Williams & Wilkins*, 1998, 11-27.
16. Pellerito JS, McCarthy SM, Doyle MB, [et al.]. Diagnosis of uterine anomalies: relative accuracy of MR imaging, endovaginal ultrasound, and hysterosalpingography. *Radiology*. 1992, 183, 795-800.
17. Radoncic E, Funduk-Kurjak B. Three-dimensional ultrasound for routine check-up in in vitro fertilization patients. *Croat Med J*. 2000, 41, 262.
18. Rechberger T, Kulik-Rechberger B. Congenital anomalies of the female reproductive tract - diagnosis and management. *Ginekol Pol*. 2011, 82, 137-145.
19. Reis MM, Soares SR, Cancado ML, Camargos AF. Hysterosalpingo contrast sonography (Hy-CoSy) with SH U 454 (Echovist) for the assessment of tubal patency. *Hum Reprod*. 1998, 13 (11), 3049-3052.
20. Rouanet De Lavit JP, Maubon AJ, Thurmond AS. MR hystero-graphy performed with saline injection and fluid attenuation inversion recovery sequences: initial experience. *Am J Roentgenol*. 2000, 175 (3), 774-776.
21. Saravelos SH, Cocksedge KA, Li TC. Prevalence and diagnosis of congenital uterine anomalies in women with reproductive failure: a critical appraisal. *Hum Reprod Update*. 2008, 14 (5), 415-29.
22. Simpson WL Jr, Beitia LG, Mester J. Hysterosalpingography: a reemerging study. *Radiographics* 2006 Mar-Apr;26(2):419-31.
23. Spring DB, Barkan HE. Enhanced fertility after diagnostic hysterosalpingography may be a myth. (commentary) *AJR*. 2004, 183, 1728.
24. The American Fertility Society classifications of adnexal adhesions, distal tubal occlusion, tubal occlusion secondary to tubal ligation, tubal pregnancies, mullerian anomalies and intrauterine adhesions. *Fertil Steril*. 1988, 49, 944-955.
25. Troiano RN, McCarthy SM. Mullerian duct anomalies: imaging and clinical issues. *Radiology*. 2004, 233, 19-34.
26. Woelfer B, Salim R, Banerjee S, Elson J, [et al.]. Reproductive outcomes in women with congenital uterine anomalies detected by threedimensional ultrasound screening. *Obstet Gynecol*. 2001, 98:1099-1103.
27. Wu MH, Hsu CC, Huang KE. Detection of congenital Mullerian duct anomalies using three-dimensional ultrasound. *J Clin Ultrasound*. 1997, 25, 487-492.

KOMUNIKAT



KONFERENCJA "STANY NAGLE W POŁOŻNICTWIE"

POZNAŃ 27 CZERWCA 2014

SYMPOSIUM "EMERGENCY OBSTETRICAL ANAESTHESIA"
POZNAN POLAND 27TH JUNE 2014

HOTEL POZNAŃSKI, KRAJĄCOWA 4, 62-030 LUBOŃ K. POZNAŃ

Drogie Koleżanki! Drodzy Koledzy!

Mamy radość i zaszczyt zaprosić Państwa do Poznania na jednodniowe sympozjum poświęcone postępowaniu w stanach krytycznych w położnictwie.

Współpomysłodawcą i współorganizatorem naszego sympozjum jest powszechnie znany i lubiany Pan Profesor emerytowany Gabriel Gurman z uniwersytetu w Beersheva, założyciel międzynarodowej szkoły dla młodych nauczycieli anestezjologii (ISIA – International School of Instructors in Anesthesiology, działającej przy wsparciu ESA i WFSA). Wykładowcami w tym pierwszym polsko-izraelskim sympozjum są naukowcy-praktycy o bogatym doświadczeniu.

P R O G R A M

10.00 Otwarcie Konferencji

10.30 – 12.00 Pierwsza sesja

Masywny krwotok położniczy – przedmiot do dyskusji

Dr Alexander Ioscovich, Head of Gynecological and High Risk Obstetric Anesthesia Unit, Sharej Zedek Medical Center, Jerusałem,
Dr med. Agnieszka Koziołek, Klinika Anestezjologii w Położnictwie i Ginekologii, Uniwersytet Medyczny w Poznaniu

12.30 – 14.00 Druga sesja

Znieczulenie do pilnego cięcia cesarskiego

Prof. Nathan Weksler, Chief Department of Anesthesia, Mayney Hayeshuah Medical Center, Bnai Brak
Dr hab. Hanna Billert Kierownik Zakładu Anestezjologii Doświadczalnej, Uniwersytet Medyczny w Poznaniu

14.00 – 15.00 Lunch

15.00 – 17.45 Trzecia sesja

Jeśli sprawy toczą się niezgodnie z planem. Przypadek cięcia cesarskiego na ławie sądowej

Prof. Gabriel M. Gurman, Chairman, Division of Anesthesia-Critical Care, Mayney Hayeshuah Medical Center, Bnai Brak
Prof. Krzysztof Szymanowski Kierownik Pracowni Endoskopii Ginekologicznej i Chirurgii Małoinwazyjnej, Ordynator Oddziału Porodowego, Uniwersytet Medyczny w Poznaniu
Mecenas Arkadiusz Kurkiewicz, Kancelaria Prawna Kurkiewicz, Siejak, Tritt sp.k. Poznań

18.00 – 19.30 Czwarta sesja

Jak pilne jest „nagle” cięcie cesarskie?

Dr. Michael Lottan, chief Obstetrical Anesthesia Unit, Ychilov Medical Center, Tel Aviv
Dr med. Rakesh Jalali, Katedra Medycyny Ratunkowej, Uniwersytet Warmińsko-Mazurski w Olsztynie

prof. dr hab. n. med. Leon Drobniak

*Katedra Anestezjologii i Intensywnej Terapii
Uniwersytet Medyczny w Poznaniu*

dr hab. med. Michał Gaca

*Klinika Anestezjologii w Położnictwie i Ginekologii
Uniwersytet Medyczny w Poznaniu*

Profile Poznań, ul. Zgoda 14/9, 60-128 Poznań, tel. 61 661 60 08
mail: biuro@profile.poznan.pl

Szczegółowy program i rejestracja:

www.anestezjologia2014.pl