

# Hypocomplementemic urticarial vasculitis syndrome — a case report

## Pokrzywkowe zapalenie naczyń z hipokomplementemią — opis przypadku

Dominik Samotij<sup>1</sup>, Marta Wojciechowska-Zdrojowy<sup>1</sup>, Adrian Pona<sup>2</sup>, Adam Reich<sup>1</sup>

<sup>1</sup>Department of Dermatology, Venereology and Allergology, Wrocław Medical University, Poland

<sup>2</sup>Students' Scientific Circle of Experimental Dermatology, Department of Dermatology, Venereology and Allergology, Wrocław Medical University, Poland

### ABSTRACT

Hypocomplementemic urticarial vasculitis syndrome (HUVS) is an uncommon small-vessel vasculitis presenting as a chronic urticaria with hypocomplementemia and the presence of anti-C1q autoantibodies. In most patients it is accompanied by a wide variety of extracutaneous manifestations such as arthritis, glomerulonephritis, ocular inflammation and pulmonary disease. We present a case of 49-year-old male with a 3-year history of recurrent urticaria accompanied by arthralgia, myalgia and gastrointestinal symptoms. The additional laboratory assessments revealed the presence of circulating anti-C1q autoantibodies in high titer. Histology of the lesional skin biopsy was consistent with leukocytoclastic vasculitis. The diagnosis of HUVS was confirmed in accordance to the currently adopted criteria. The described case emphasizes the necessity of high clinical suspicion when caring for patients with chronic urticaria and concomitant systemic symptoms.

**Forum Derm. 2017; 3: 1, 8–11**

**Key words:** hypocomplementemic urticarial vasculitis syndrome, urticaria, vasculitis, autoinflammatory disease, hypocomplementemia

### STRESZCZENIE

Pokrzywkowe zapalenie naczyń z hipokomplementemią (HUVS, *hypocomplementemic urticarial vasculitis syndrome*) to rzadko występujące zapalenie drobnych naczyń krwionośnych, którego objawami są przewlekła pokrzywka z hipokomplementemią oraz obecność przeciwciał anti-C1q. U większości chorych występuje również wiele objawów pozaskórnych, takich jak zapalenie stawów, kłębuszkowe zapalenie nerek, zmiany zapalne w obrębie oka i choroby płuc. W pracy przedstawiono przypadek 49-letniego pacjenta, u którego od 3 lat występowały nawracające epizody pokrzywki, którym towarzyszyły bóle stawów i mięśni oraz objawy żołądkowo-jelitowe. W badaniach laboratoryjnych wykazano wysokie miano krążących przeciwciał anti-C1q. Obraz histologiczny biopsatu skóry pobranego w obrębie zmian odpowiadał leukocytoklastycznemu zapaleniu naczyń. Rozpoznanie HUVS potwierdzono na podstawie obowiązujących obecnie kryteriów. Opisany przypadek zwraca uwagę, że przewlekła pokrzywka z objawami ogólnoustrojowymi powinna się wiązać z istotnym podejrzeniem klinicznym.

**Forum Derm. 2017; 3: 1, 8–11**

**Słowa kluczowe:** zespół pokrzywkowego zapalenia naczyń z hipokomplementemią, pokrzywka, zapalenie naczyń, choroba autozapalna, hipokomplementemia

### PATIENT HISTORY

A 49-year-old white male presented to the dermatology unit with a 3-year history of arthralgia, myalgia and chronic urticaria. Accompanying symptoms included a 4-week history of vomiting and diarrhea, a thirty-kilogram weight loss and significant pain and swelling of the interphalangeal joints of both hands and both knee joints.

The patient's past medical history is noticeable for recurrent admissions to the internal medicine ward, where he was diagnosed with chronic gastritis, colitis and emphysema.

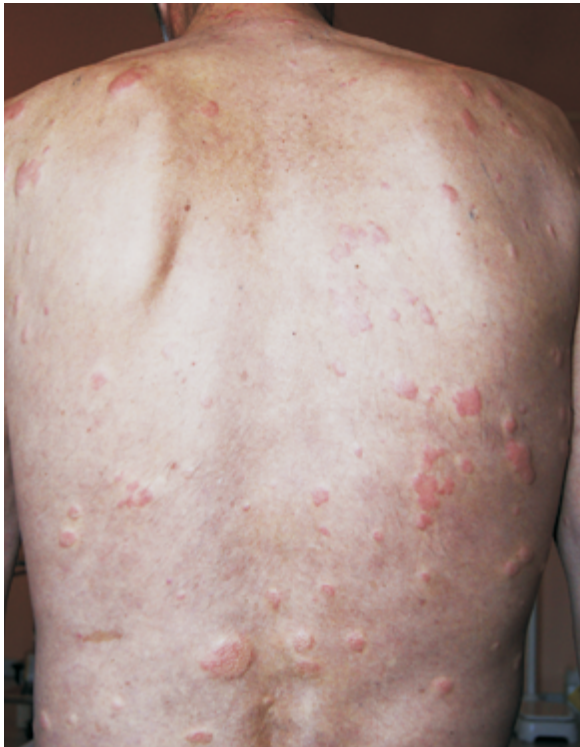Skin examination revealed disseminated urticarial rash involving the trunk and the extremities (Fig. 1). The individual lesions persisted for longer than 24 hours and were widely variable in size (Fig. 2). Physical examination was negative for any abnormalities except for the skin lesions described above and a decreased range of motion in the knee joints.

### DIAGNOSTICS

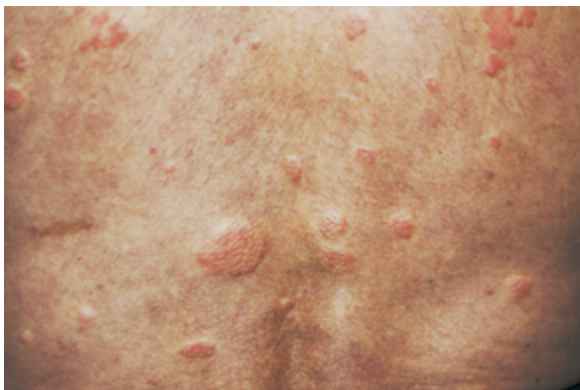Laboratory testing for systemic inflammation was positive with a markedly elevated C-reactive protein level of

### Corresponding author:

dr hab., prof. nadzw. Adam Reich, Department of Dermatology, Venereology and Allergology, Wrocław Medical University, Poland, ul. Chalubińskiego 1, 50–368 Wrocław, Poland, e-mail: adam.reich@umed.wroc.pl




**Figure 1.** Widespread urticarial rash on the upper body



**Figure 2.** Urticarial efflorescences in the lumbar region widely variable in size

49.9 mg/L (normal range: < 5.0 mg/L). Complete blood count was evident for a microcytic anemia with decreased serum iron concentration and low total iron binding capacity. Immunological analysis of serum was highly positive for anti-C1q autoantibodies at 193.9 U/mL (normal range: < 10 U/mL) and negative for p-ANCA (perinuclear anti-neutrophil cytoplasmic antibodies), c-ANCA (cytoplasmic ANCA), ANA (antinuclear antibodies) and cryoglobulins. C3 complement concentration was found to be decreased at 0.8 g/L (normal range: 0.9–1.8 g/L). Computed tomography of the lungs was evident for emphysema. Direct immunofluorescence examination of the lesional skin



**Figure 3.** Histologic features demonstrating dispersed eosinophilic and neutrophilic infiltrate in the dermis showing a tendency to accumulate around blood vessels; the pattern is consistent with leukocytoclastic vasculitis (H&E stain at 20 × magnification)

**Table 1.** Criteria for diagnosis of HUVS (McDuffie's criteria)\* [3]

	Symptoms/Abnormalities
Major Criteria	Chronic urticaria > 6 months
	Hypocomplementemia
Minor Criteria	Leukocytoclastic vasculitis on skin biopsy
	Arthralgia or arthritis
	Glomerulonephritis
	Abdominal pain
	Ocular inflammation
	Positive anti-C1q autoantibodies with low C1q complement concentration in the serum

\*The criteria fulfilled by the presented patient are in bold letters

sample reflected significant findings for IgA, IgM and IgG deposition in the walls of medium-caliber blood vessels, and C3c and C1q complement deposition in small- and medium-caliber blood vessels. In addition, C3c complement deposits were present along the epidermal basement membrane.

### **PATHOLOGY**

Histological examination of the lesional skin biopsy revealed weakly pronounced hyperkeratosis and acanthosis in the epidermis. The dermal layer showed dispersed epidermotropic neutrophilic and eosinophilic infiltrate with a tendency to accumulate around the blood vessels (Fig. 3). The above-described histological picture was consistent with urticarial vasculitis.

### **DIAGNOSIS AND TREATMENT**

The diagnosis of HUVS was confirmed by fulfilling McDuffie's criteria. Table 1 highlights the symptoms and

laboratory abnormalities that were present in our patient in order to meet the diagnostic criteria. The treatment with 150 mg of dapsone daily in combination with 8 mg of methylprednisolone daily was initiated leading to marked clinical improvement.

## DISCUSSION

HUVS, or McDuffie syndrome, is defined as a small-vessel vasculitis characterized by recurrent urticarial lesions and hypocomplementemia with the frequent association of anti-C1q autoantibodies. The prevalence of HUVS is unknown due to a relatively small number of only two hundred cases documented [1]. HUVS is eight times more prevalent in women than in men [1]. The disease onset may occur in childhood but majority of the patients seek medical attention during the fourth decade of life [1].

HUVS can be categorized into primary, or idiopathic, and secondary. The etiology of primary HUVS has not been yet established but there is evidence that both environmental and genetic factors are involved [1]; the contribution of genetic factors to the pathogenesis of HUVS may be hypothesized by the documented incidence of HUVS in siblings [1]. Secondary HUVS is most likely associated with a chronic disorder, frequently associated with systemic inflammation [2].

The classic presentation of HUVS includes episodic widespread urticarial eruption on the face, trunk and proximal extremities that persists longer than 24 hours and usually resolves with hyperpigmentation. Histology of the lesional biopsy is consistent with leukocytoclastic vasculitis [3]. Systemic manifestations of the disease include fever, arthralgia, ocular inflammation and varied disturbances related to gastrointestinal, renal and pulmonary affection. Cutaneous lesions and arthralgia are the most frequent manifestations of HUVS (Tab. 2) [3]. Pulmonary symptoms include cough, dyspnea, pleural effusion and emphysema; chronic obstructive pulmonary disease is diagnosed in as many as 20–50% of patients presenting with HUVS [3]. About half of the patients present with renal disease commonly manifested by proteinuria and hematuria [3]. Ocular chan-

ges include conjunctivitis, uveitis and episcleritis [3]. Of note, HUVS may be associated with both Hodgkin's and non-Hodgkin's lymphomas, possibly due to the prolonged B-cell stimulation [2].

Typical laboratory abnormalities seen in HUVS individuals include an elevated erythrocyte sedimentation rate and low levels of C4, C1q, and sometimes also C3, complement components [3]. Leukocytoclastic vasculitis on histology is a frequent and helpful finding, however, not obligatory to establish the diagnosis [3].

The diagnostic criteria for HUVS, sometimes called McDuffie's criteria, are divided into major and minor. The major criteria consist of urticaria persisting for longer than six months and hypocomplementemia. The minor criteria include positive histopathology, glomerulonephritis, arthralgia/arthritis, abdominal pain, ocular inflammation and positive anti-C1q autoantibody. Diagnosis requires the presence of both major criteria together with at least two minor criteria [3].

Treatment of HUVS is dependent on the disease severity, in particular on the presence of concomitant systemic symptoms. If the disease is limited to the skin, with no systemic involvement present, management with antihistamines is recommended [3]. HUVS with concomitant joint affection should be treated with low-dose prednisone in combination with immunosuppressive or immunomodulatory agents such as mycophenolate mofetil, methotrexate, azathioprine, cyclophosphamide, dapsone or hydroxychloroquine [3, 4]. If HUVS is associated with glomerulonephritis or other potentially life-threatening systemic manifestations, immediate treatment with high-dose glucocorticosteroids in combination with cytotoxic agent is required [4]. Future management with new monoclonal antibodies, such as canakinumab targeted at interleukin-1 $\beta$ , may change the treatment regimen for patients suffering from HUVS [5].

A relatively small number of HUVS cases has been documented so far. Kervarrec et al. [6] reported a 63-year-old female presenting with a chronic bullous urticaria, 10-kilogram weight loss, abdominal pain, pericardial effusion, hypocomplementemia, and the presence of anti-C1q auto-

**Table 2.** Frequency and pattern of organ involvement in HUVS [3]

Involved organ	Frequency of occurrence	Symptoms
Skin	100%	Urticaria, angioedema, purpura, leukocytoclastic vasculitis
Joints	70%	Arthralgia, arthritis
Kidneys	50%	Proteinuria, hematuria, glomerulonephritis
Gastrointestinal tract	30%	Abdominal pain, nausea, vomiting, diarrhea
Respiratory system	20%	Decreased performance, cough, hemoptysis, chronic obstructive pulmonary disease
Eye	10%	Conjunctivitis, episcleritis
Heart, Nervous system	Rare	Pericarditis, pseudotumor cerebri, meningitis

antibodies. This patient seemed to demonstrate some similarities to our case report, such as unexplained weight loss, chronic urticaria and some laboratory abnormalities, but the contrast between the sex and pericardial involvement indicates the possibility of distinct systemic presentations of HUVS. Jachiet et al. [4] performed a retrospective study on efficacy of treatment in HUVS by measuring the time-to-treatment failure (TTF). Hydroxychloroquine, colchicine and glucocorticosteroids were established as a first-line therapy. Azathioprine, mycophenolate mofetil and cyclophosphamide should be used in refractory cases. It is worth to point out that dapsone was not considered a first-line treatment modality due to lack of studies on the drug's TTF. In contrast, Héroult et al. [7], Eiser et al. [8] and Nürnberg et al. [9] demonstrated considerable improvement of HUVS symptoms after dapsone treatment. Provided a favorable safety profile of dapsone, further research on this agent in the treatment of HUVS should be considered.

Multiple case reports confirm the tendency for occurrence of HUVS in the fourth decade of life [10, 11]. However, Al Mosawi et al. [12] and DeAmicis et al. [13] presented case reports of an 8-year-old boy and a 12-year-old girl with HUVS respectively, which exemplified the possible variability in the age of onset of the disease.

## CONCLUSION

Since multiple systemic presentations of this rare condition exist, the presence of chronic urticaria and unexplained extracutaneous manifestations should prompt the suspicion of HUVS. In addition, due to its many similarities to systemic lupus erythematosus, the diagnosis of the latter should always be excluded.

## REFERENCES

1. Gasim A.H., Jennette C. Hypocomplementemic urticarial vasculitis. Orphanet: [http://www.orpha.net/consor/cgi-bin/OC\\_Exp.php?lng=EN&Expert=36412](http://www.orpha.net/consor/cgi-bin/OC_Exp.php?lng=EN&Expert=36412) (Last update: May 2013).
2. Buck A, Christensen J, McCarty M. Hypocomplementemic urticarial vasculitis syndrome: a case report and literature review. *J Clin Aesthet Dermatol.* 2012; 5(1): 36–46, indexed in Pubmed: [22328958](#).
3. Grotz W, Baba HA, Becker JU, et al. Hypocomplementemic urticarial vasculitis syndrome: an interdisciplinary challenge. *Dtsch Arztebl Int.* 2009; 106(46): 756–763, doi: [10.3238/arztebl.2009.0756](#), indexed in Pubmed: [20019864](#).
4. Jachiet M, Flageul B, Deroux A, et al. French Vasculitis Study Group. The clinical spectrum and therapeutic management of hypocomplementemic urticarial vasculitis: data from a French nationwide study of fifty-seven patients. *Arthritis Rheumatol.* 2015; 67(2): 527–534, doi: [10.1002/art.38956](#), indexed in Pubmed: [25385679](#).
5. Krause K, Mahamed A, Weller K, et al. Efficacy and safety of canakinumab in urticarial vasculitis: an open-label study. *J Allergy Clin Immunol.* 2013; 132(3): 751–754.e5, doi: [10.1016/j.jaci.2013.04.008](#), indexed in Pubmed: [23711544](#).
6. Kervarrec T, Binois R, Bléchet C, et al. [Hypocomplementemic urticarial vasculitis with bullous lesions and pericardial involvement]. *Ann Dermatol Venereol.* 2015; 142(10): 557–562, doi: [10.1016/j.annder.2014.11.016](#), indexed in Pubmed: [25613197](#).
7. Héroult M, Mazet J, Beurey P, et al. [Hypocomplementemic vasculitis treated with dapsone]. *Ann Dermatol Venereol.* 2010; 137(8-9): 541–545, doi: [10.1016/j.annder.2010.04.015](#), indexed in Pubmed: [20804899](#).
8. Eiser AR, Singh P, Shanies HM. Sustained dapsone-induced remission of hypocomplementemic urticarial vasculitis—a case report. *Angiology.* 1997; 48(11): 1019–1022, doi: [10.1177/000331979704801114](#), indexed in Pubmed: [9373057](#).
9. Nürnberg W, Grabbe J, Czarnetzki BM. Urticarial vasculitis syndrome effectively treated with dapsone and pentoxifylline. *Acta Derm Venereol.* 1995; 75(1): 54–56, indexed in Pubmed: [7747536](#).
10. el Maghraoui A, Abouzahir A, Mahassine F, et al. [McDuffie hypocomplementemic urticarial vasculitis. Two cases and review of the literature]. *Rev Med Interne.* 2001; 22(1): 70–74, indexed in Pubmed: [11218302](#).
11. Sessler R, Hasche G, Olbricht CJ. [Hypocomplementemic urticarial vasculitis syndrome]. *Dtsch Med Wochenschr.* 2000; 125(34-35): 1003–1006, doi: [10.1055/s-2000-7067](#), indexed in Pubmed: [11004912](#).
12. Al Mosawi ZS, Al Hermi BE. Hypocomplementemic Urticarial Vasculitis Syndrome in an 8-year-old Boy: A Case Report and Review of Literature. *Oman Med J.* 2013; 28(4): 275–277, doi: [10.5001/omj.2013.76](#), indexed in Pubmed: [23904922](#).
13. DeAmicis T, Mofid MZ, Cohen B, et al. Hypocomplementemic urticarial vasculitis: report of a 12-year-old girl with systemic lupus erythematosus. *J Am Acad Dermatol.* 2002; 47(5 Suppl): S273–S274, indexed in Pubmed: [12399749](#).