

Accessory head of the flexor pollicis longus muscle: anatomical study and clinical significance

D.R. Ballesteros¹, P.L. Forero², L.E. Ballesteros¹

¹Department of Basic Sciences, Industrial University of Santander. Bucaramanga, Colombia

²Department of Pathology, Industrial University of Santander. Bucaramanga, Colombia

[Received: 6 May 2018; Accepted: 24 June 2018]

Background: The accessory head of the flexor pollicis longus (AHFPL) has an oblique trajectory from medial to lateral aspect of the forearm below the flexor digitorum superficialis muscle and then joins the flexor pollicis longus muscle. When the anterior interosseous nerve (AIN) courses underneath the muscle belly of the AHFPL an entrapment neuropathy may occur, known as anterior interosseous nerve syndrome (AINS).

Materials and methods: This descriptive cross-sectional study evaluated 106 fresh upper extremities. When the AHFPL was present, its fascicle was traced up to evaluate the origin site. The morphometric variables were measured using a digital micrometre (Mitutoyo, Japan). The relationship between the AHFPL and the AIN was evaluated.

Results: The AHFPL was found in 34 (32.1%) of the 106 forearms. The AHFPL arose from the flexor digitorum superficialis muscle in 16 (47.1%) forearms, the medial epicondyle of the humerus in 10 (29.4%) forearms and the coronoid process of ulna in 8 (23.5%) forearms. The average total length of the AHFPL was 94.11 ± 10.33 mm. The AIN was located lateral to the AHFPL in 3 (8.8%) forearms, posterolateral in 7 (20.6%) forearms and posterior in 24 (70.6%) forearms.

Conclusions: This study performed in a South American population sample revealed a prevalence of the AHFPL in a lower range compared to previous studies in North Americans and Asians. The AIN coursed more frequently underneath the muscle belly of AHFPL. This finding has clinical significance in the onset of the AINS and the subsequent surgical procedure for the AIN decompression. (Folia Morphol 2019; 78, 2: 394–400)

Key words: flexor pollicis longus, anterior interosseous nerve, nerve compression syndromes, anatomic variation, orthopaedic procedures

INTRODUCTION

The accessory head of the flexor pollicis longus (AHFPL) was first described in 1813 by Karl Friedrich Gantzer, a German anatomist [8]. This muscular structure may originate from the medial epicondyle of the humerus, the coronoid process of the ulna or the flexor digitorum superficialis muscle (FDS) [7, 10, 14, 24, 27]. The AHFPL has an oblique trajectory from

medial to lateral aspect of the forearm below the FDS and then joins the flexor pollicis longus muscle (FPL) [10, 21, 27]. Moreover, the AHFPL may also give rise to a second tendinous contribution to the flexor digitorum profundus muscle (FDP) [3, 11, 16, 22].

The AHFPL has been reported in different population groups with frequencies ranging between 25% and 73.6%. Traditionally it has been considered as an

anatomical variation, but in some population groups it could be considered a normal pattern. Studies in Americans and Asians have reported frequencies of the AHFPL greater than 50% [10, 13, 14, 22]. When this accessory muscular belly is present, it is more likely to be bilateral than unilateral [9, 11, 13, 14, 16].

The occurrence of AHFPL could be explained during the embryological development of the common flexor mass, which differentiates into two layers: superficial and deep [13, 17]. The deep layer in turn differentiates into the FDP, the flexor pollicis longus and the pronator quadratus muscle [4, 24]. An incomplete cleavage of the deep layer gives origin to the AHFPL [11]. During the evolution, the Human acquired the FPL. It is primitive or absent in primates, in which the inclusion of the FPL into the muscle mass of the flexors is responsible for the loss of the functional independence of the thumb flexor [7, 14].

The AHFPL may lead to an entrapment neuropathy of the anterior interosseous nerve (AIN), known as Kiloh-Nevin syndrome or anterior interosseous nerve syndrome (AINS) [5, 15, 25]. This syndrome is manifested clinically as a weakness in flexion of the interphalangeal joint of the thumb and the distal interphalangeal joints of the index and middle finger [18, 23, 26]. The present study was conducted to evaluate the prevalence of this accessory muscle in a South American population sample, its morphometry and relationship with the AIN, constituting valuable information for clinical diagnosis and surgical approaches to the forearm.

MATERIALS AND METHODS

This descriptive cross-sectional study evaluated 106 fresh upper extremities of 53 individuals who were undergoing necropsy at the National Institute of Forensic Medicine in Bucaramanga, Colombia. The sample met the following inclusion criteria: male individuals over 18 years of age. Subjects with evidence of direct trauma or scars in upper extremities were excluded. The research protocol was developed in strict accordance with the Ethical Guidelines for Medical and Health Research Involving Human Subjects and was approved by the Ethics Committee of the Industrial University of Santander.

A longitudinal incision along the midaxillary line was made extending from the antecubital fossa to the wrist, which involved skin, subcutaneous tissue and antebrachial fascia. Subsequently, the muscular structures of the anterior compartment of the fore-

arm, the median and interosseous nerves were dissected. When the AHFPL was present, its fibres were traced up doing a meticulous dissection to evaluate the site of origin. Tendons of the flexor carpi radialis and palmaris longus muscles were identified and reflected to expose the FPL and locate the insertion level of the AHFPL.

The morphology was evaluated according to Pai et al. [17] classification in three groups: strap-like (slender), fusiform and voluminous. The length of the muscle belly, the length of the tendon and the width of the widest segment of the muscle belly were measured using a digital micrometre (Mitutoyo, Japan). The relationship between the AHFPL and the AIN was evaluated. The statistical analysis was performed using IBM® SPSS®. Continuous quantitative variables were described with their averages and standard deviations. A Student's t test was carried out accepting an alpha error of up to 5%.

RESULTS

The accessory head of the flexor pollicis longus was found in 34 (32.1%) of the 106 forearms. Of the 53 cadaveric specimens, 23 (43.4%) presented AHFPL. In 11 (47.8%) individuals the AHFPL was found bilaterally and in 12 (52.2%) individuals was found unilaterally. The AHFPL was distributed in 18 (53%) right forearms and in 16 (47%) left forearms. No statistical significant differences were found in relation to the sides and the presence of the AHFPL ($p > 0.05$).

The origin of the AHFPL varied greatly. It arose from the flexor digitorum superficialis muscle in 16 (47.1%) forearms, the medial epicondyle of the humerus in 10 (29.4%) forearms and the coronoid process of ulna in 8 (23.5%) forearms. No cases of dual origin between the coronoid process and the medial epicondyle of the humerus were found. In all the specimens, the insertion was on the ulnar border of the FPL. In 82.1% of the cases the AHFPL inserted into the proximal third of the FPL, 14.2% into middle third, and 3.8% into the distal third. No cases of second tendon to the FDP were found.

The AHFPL was classified in three different morphological groups: slender, fusiform and voluminous. The most common type was fusiform in 17 (50%) forearms (Fig. 1), then slender in 11 (32.4%) forearms (Figs. 2, 3) and voluminous in 6 (17.6%) forearms (Fig. 4). The average total length of the AHFPL was 94.11 ± 10.33 mm. The average length of the muscle belly was 84.42 ± 9.27 mm and the tendon 9.68 ± 1.86 mm.

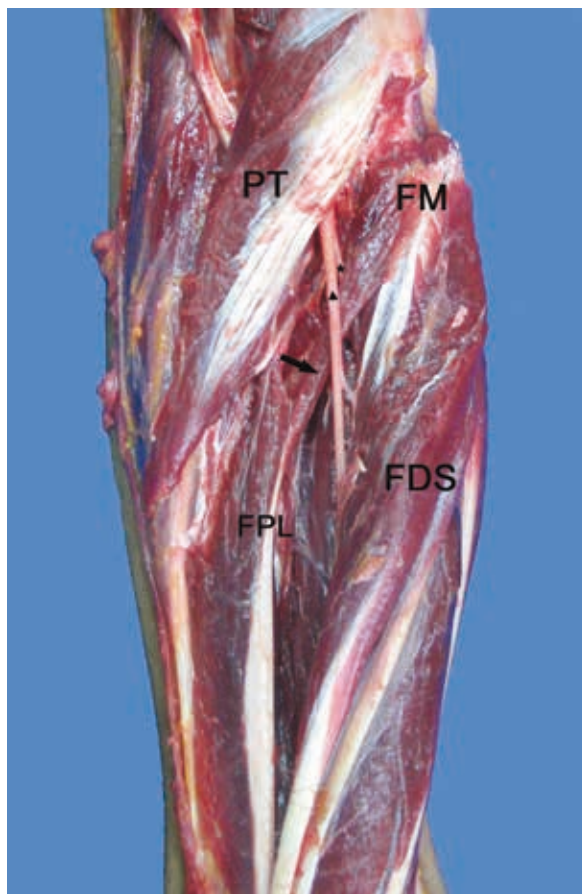


Figure 1. Anterior compartment of the right forearm. Fusiform morphology of the accessory head of the flexor pollicis longus (AHFPL) (arrow). The anterior interosseous nerve is located posterior to the muscle belly of the AHFPL (asterisk); PT — pronator teres muscle; FM — flexor mass; FPL — flexor pollicis longus muscle; FDS — flexor digitorum superficialis muscle; ▲ — median nerve.

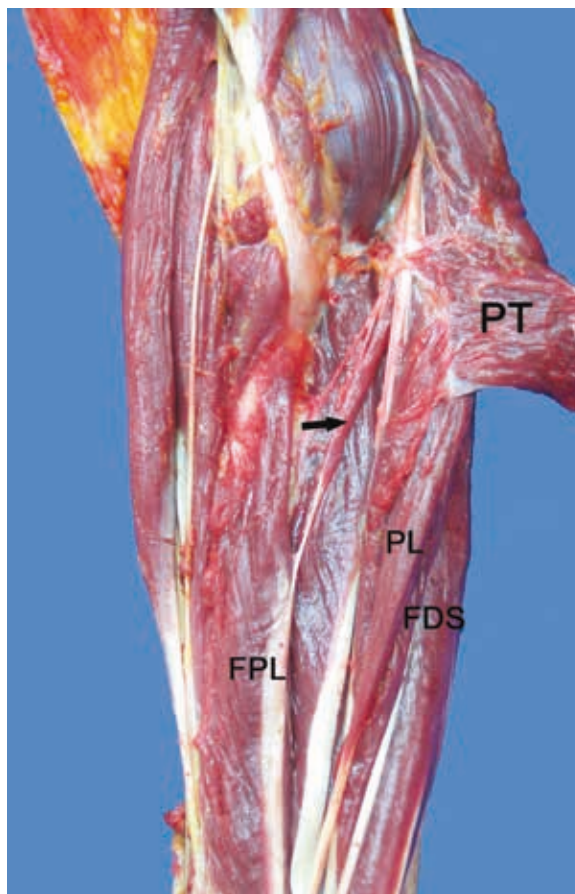


Figure 2. Anterior compartment of the right forearm. Slender morphology of the accessory head of the flexor pollicis longus (AHFPL) (arrow); PT — pronator teres muscle; PL — palmaris longus muscle; FPL — flexor pollicis longus muscle; FDS — flexor digitorum superficialis muscle.

The average width in the widest segment was 7.62 ± 1.11 mm. The AIN was crossed by the belly of the AHFPL in 63.2% of the cases and by the tendon of the muscle in 36.8%. The AIN was located lateral to the AHFPL in 3 (8.8%) forearms (Fig. 3), posterolateral in 7 (20.6%) forearms (Fig. 2) and posterior in 24 (70.6%) forearms (Figs. 1, 4). No statistical significant differences were found between the sides and the morphometric variables ($p > 0.05$).

DISCUSSION

The frequencies of the AHFPL vary in different population groups (Table 1), with frequencies ranging between 25% and 73.6%. The frequency of the AHFPL observed in the present study is in a low range compared to previous studies. In North-American population, previous studies reveal a consolidated frequency of 53.82% and in Asians 52.12%. Accord-

ing to that, in North-Americans and Asians the AHFPL could be considered as a normal pattern and not as an anatomical variation.

In South American population, earlier reports are contradictory. Studies by Caetano et al. [3] reveal a frequency of 67.5% and studies by Riveros et al. [20] reveal a frequency of 10%. Including the present study, the consolidated prevalence of this group is 42.1%. In African population, studies by El Domiaty et al. [7] reveal a higher frequency (61.9%) but further studies in this population group are needed to be representative. We found that the AHFPL occurred more frequently bilaterally, agreeing with the findings of Mangini [14], Uyaroglu et al. [27], Mahakkanukrauh et al. [13], Oh et al. [16], Jones et al. [11], and Gunnal et al. [9].

Regarding the origin of the AHFPL muscle, some authors have reported the medial epicondyle of the

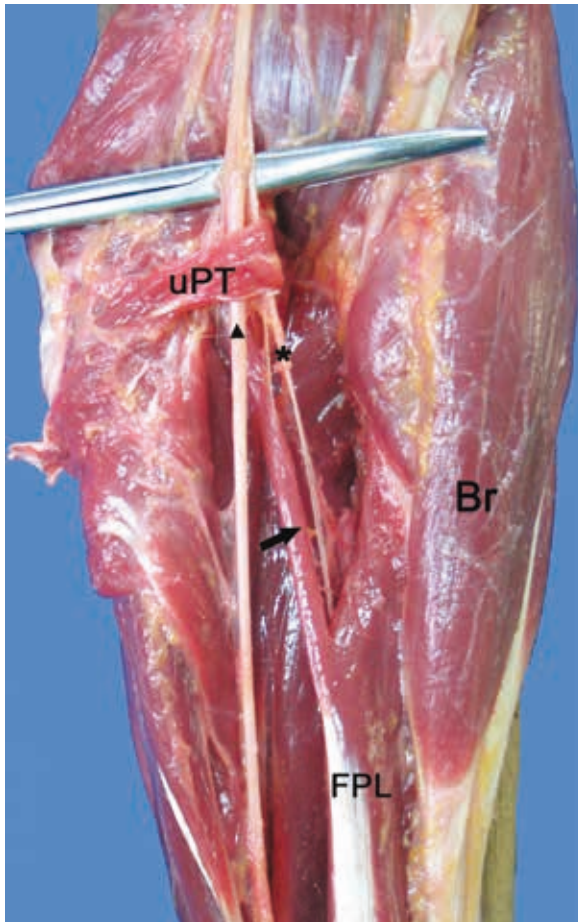


Figure 3. Anterior compartment of the left forearm. Slender morphology of the accessory head of the flexor pollicis longus (AHFPL) (arrow). The anterior interosseous nerve is located lateral to the muscle belly of the AHFPL (asterisk); uPT — ulnar head of the pronator teres muscle; Br — brachioradialis muscle; FPL — flexor pollicis longus muscle; ▲ — median nerve.

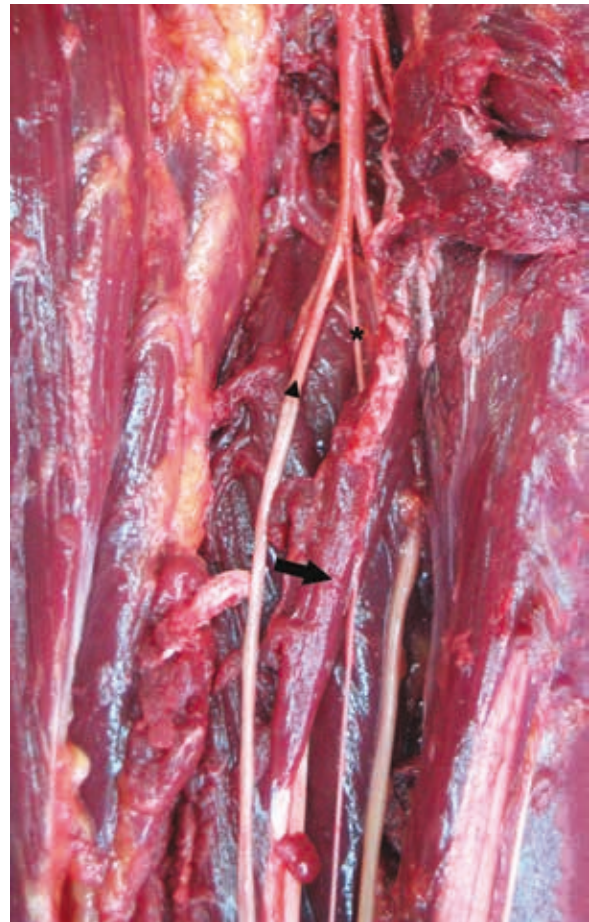

Figure 4. Anterior compartment of the right forearm. Voluminous morphology of the accessory head of the flexor pollicis longus (AHFPL) (arrow). The anterior interosseous nerve is located posterior to the muscle belly of the AHFPL (asterisk); ▲ — median nerve.

humerus as the most frequent site [1, 6, 10, 13, 14, 22], others have reported that is the coronoid process [9, 16, 27]. In our series, the most frequent origin was the flexor digitorum superficialis muscle, similarly reported by Jones et al. [11], El Domiaty et al. [7], Kara et al. [12] and Caetano et al. [3]. However, a recent meta-analysis of 24 cadaveric studies found that the most common origin of the AHFPL was the medial epicondyle of the humerus [19].

This discrepancy can be explained by the fact that in its origin the AHFPL is intimately related with other structures of the flexor mass, leading to a possible misidentification by authors [3, 10, 16, 19]. It is necessary to do a meticulous dissection to determine the origin appropriately, because the FDS has fascicles originated in the coronoid process and medial epicondyle of the humerus. Therefore, it is important

to adequately distinguish in which of these three structures the AHFPL arises from.

Regarding the insertion, earlier reports [1, 7, 11, 13] reveal that the AHFPL muscle inserts into the ulnar border of the FPL. In our series, the most frequent insertion level was the proximal third of the FPL tendon, similarly reported by Jones et al. [11] and El Domiaty et al. [7]. There were no instances of a second tendon to the FDP.

Jones et al. [11] were the first to classify the morphology of the AHFPL in four groups: slender, voluminous, triangular and fusiform. Subsequently Oh et al. [16] described three different morphological groups: papillary, spindle and band type. Afterwards Pai et al. [17] classified the morphology in three groups: strap-like (slender), fusiform and voluminous. In our series, the most frequent type was fusiform, consistent to the

Table 1. Prevalence of the accessory head of the flexor pollicis longus (AHFPL) reported in previous studies and organized by population groups

Authors	Nationality	Sample	Cases	Population	Prevalence
Mangini (1960)	American	76	56	North American	53.82%
Shirali et al. (1998)	American	60	33		
Malhotra, Sing and Tewari (1982)	American	240	130		
Dykes and Anson (1944)	American	150	80		
Dellon and Mackinnon (1987)	Canadian	43	14		
Tubbs et al. (2006)	American	20	4		
Hemmady, Subramanya and Mehta (1993)	Indian	54	36	Asian	52.12%
Oh, Chung and Koh (2000)	Korean	72	48		
Kida (1988)	Japanese	132	82		
Mahakkanukrauh et al. (2004)	Thai	240	149		
Al-Qattan (1996)	Saudi	25	13		
Gunnal et al. (2013)	Indian	180	92		
Mori (1964)	Japanese	205	103		
Pai et al. (2008)	Indian	126	58		
Sharma et al (2008)	Indian	60	24		
Uyaroglu, Kayalioglu and Erturk (2006)	Turkish (Anatolian)	52	27		
Kara et al. (2012)	Turkish (Anatolian)	142	49	European	49.71%
Bilecenoglu, Uz and Karalezli (2005)	Turkish (Anatolian)	30	6		
Jones et al. (1997)	British	80	36		
Dolderer et al. (2011)	German	19	5	South American	42.13%
Wood (1868)	British	72	44		
Caetano et al. (2015)	Brazilian	80	54		
Riveros, Olave and Sousa-Rodrigues (2015)	Brazilian	30	3	African	61.90%
Present study (2018)	Colombian	106	34		
El Domiaty, Zoair and Sheta (2008)	Egyptian	42	26		
Overall	–	2336	1206	–	51.6%

reported by Kara et al. [12], Pai et al. [17], El Domiaty et al. [7], Caetano et al. [3], Gunnal et al. [9].

Regarding the morphometric data, the length of the muscle belly and the tendon have been reported to range between 60 and 80.4 mm and between 8 and 20.7 mm, respectively [7, 9, 11, 12, 16, 17, 26]. Our findings reveal greater lengths compared to studies by Pai et al. [17], Kara et al. [12] and Oh et al. [16] but similar to the reported by Uyaroglu et al. [27] and Gunnal et al. [9].

The width has been reported to range between 6.9 and 7.8 mm [9, 12, 16, 26]. In our series, the width of the muscle belly was 7.62 ± 1.11 mm, consistent to the previously reported. Earlier re-

ports found that the right side was wider than the left [10, 13], with a statistically significant difference, explained possibly since most people are right handed [13]. However, our findings did not show any statistically significant difference between sides and width ($p > 0.05$).

The relationship between the AHFPL and the AIN was described originally by Mangini [14] who stated that the muscle always laid between the median nerve anteriorly and the AIN posteriorly. Subsequently, Dellon and Mackinnon [6] and Al-Qattan [1] stated that the muscle always laid posterior to both the median nerve and the anterior interosseous nerve. In our series, the median nerve was always located anterior to

the AHFPL. Moreover, the AIN was located posterior, posterolateral or lateral to the AHFPL, similarly to earlier reports [12, 13, 26].

In our series, the AIN was crossed by the muscle belly of the AHFPL in most of the cases, in concordance with the results of the meta-analysis by Roy et al. [19]. This finding is clinically relevant considering that the AINS may occur when the AIN courses underneath the muscle belly of the AHFPL originating an entrapment neuropathy [2, 5, 24]. There are two characteristics of the AHFPL that could be predisposing factors in the onset of the AINS: a hypertrophy of the muscle belly [3, 6, 22] and the morphology by itself [19], since a greater contact surface with the AIN may lead to an entrapment neuropathy.

The AIN is purely a motor nerve. It innervates the pronator quadratus, the FDP of the index and middle fingers, and the flexor pollicis longus [25]. The AINS is manifested clinically as weakness in flexion of the interphalangeal joint of the thumb and the distal interphalangeal joints of the index and middle finger [2, 18, 22]. During the physical examination, the physician may ask the patient to join the thumb and index fingers together forming a circle. The patient with AINS will be unable to do an active flexion of the interphalangeal joint of the thumb and the distal interphalangeal joint of the index finger [5, 18, 22, 24]. During the surgical exploration, if the AHFPL is encountered, it is mandatory to resect any fibrous bands that may be compressing the AIN [2, 5, 24].

CONCLUSIONS

The AHFPL has traditionally been considered a variant, however, in North Americans and Asians could be considered as a normal pattern. This study performed in a South American population sample, revealed a prevalence of the AHFPL in a lower range compared to previous studies in North Americans and Asians. The results of the morphometric variables in our series are consistent with the findings in the other population groups. The AIN coursed more frequently underneath the muscle belly of AHFPL. This finding has clinical significance in the onset of the AINS and the subsequent surgical procedures to decompress the AIN.

Acknowledgements

We would like to recognise the National Institute of Forensic Medicine (Instituto Nacional de Medicina Legal y Ciencias Forenses) for supplying the anatomical specimens used in this study.

REFERENCES

1. Al-Qattan MM. Gantzer's muscle. An anatomical study of the accessory head of the flexor pollicis longus muscle. *J Hand Surg Br.* 1996; 21(2): 269–270, indexed in Pubmed: [8732417](#).
2. Azar FM, Canale ST, Beaty JH. *Campbell's Operative Orthopaedics*. 13th ed. Philadelphia: Elsevier. 2016: 3213.
3. Caetano EB, Sabongi JJ, Vieira LÂ, et al. Gantzer muscle. An anatomical study. *Acta Ortop Bras.* 2015; 23(2): 72–75, doi: [10.1590/1413-78522015230200955](#), indexed in Pubmed: [27069404](#).
4. Cihák R. Ontogenesis of the skeleton and intrinsic muscles of the human hand and foot. *Ergeb Anat Entwicklungsgesch.* 1972; 46(1): 5–194, indexed in Pubmed: [5043313](#).
5. Degreef I, De Smet L. Anterior interosseous nerve paralysis due to Gantzer's muscle. *Acta Orthop Belg.* 2004; 70(5): 482–484, indexed in Pubmed: [15587039](#).
6. Dellon AL, Mackinnon SE. Musculoaponeurotic variations along the course of the median nerve in the proximal forearm. *J Hand Surg Br.* 1987; 12(3): 359–363, indexed in Pubmed: [3437205](#).
7. El Domiaty MA, Zoair MM, Sheta AA. The prevalence of accessory heads of the flexor pollicis longus and the flexor digitorum profundus muscles in Egyptians and their relations to median and anterior interosseous nerves. *Folia Morphol.* 2008; 67(1): 63–71, indexed in Pubmed: [18335416](#).
8. Gantzer KF. *Dissertatio anatomica musculorum varietates sistens: quam consensu gratiosi medicorum ordinis. Bero-lini: Typis Joannis Friderici Starckii.* 1813; 13: 14.
9. Gunnal SA, Siddiqui AU, Daimi SR, et al. A Study on the Accessory Head of the Flexor Pollicis Longus Muscle (Gantzer's Muscle). *J Clin Diagnostic Res.* 2013; 7(3): 418–421, doi: [10.7860/jcdr/2013/4545.2788](#).
10. Hemmady MV, Subramanya AV, Mehta IM. Occasional head of flexor pollicis longus muscle: a study of its morphology and clinical significance. *J Postgrad Med.* 1993; 39(1): 14–16, indexed in Pubmed: [8295137](#).
11. Jones M, Abrahams PH, Sañudo JR, et al. Incidence and morphology of accessory heads of flexor pollicis longus and flexor digitorum profundus (Gantzer's muscles). *J Anat.* 1997; 191 (Pt 3): 451–455, indexed in Pubmed: [9419002](#).
12. Kara A, Elvan O, Yildiz S, et al. Accessory head of flexor pollicis longus muscle in fetuses and adult cadavers and its relation to anterior interosseous nerve. *Clin Anat.* 2012; 25(5): 601–608, doi: [10.1002/ca.21296](#), indexed in Pubmed: [22038878](#).
13. Mahakkanukrauh P, Surin P, Ongkana N, et al. Prevalence of accessory head of flexor pollicis longus muscle and its relation to anterior interosseous nerve in Thai population. *Clin Anat.* 2004; 17(8): 631–635, doi: [10.1002/ca.20016](#), indexed in Pubmed: [15495169](#).
14. Mangini U. Flexor pollicis longus muscle. Its morphology and clinical significance. *J Bone Joint Surg Am.* 1960; 42-A: 467–470, indexed in Pubmed: [13853793](#).
15. Nagano A. Spontaneous anterior interosseous nerve palsy. *J Bone Joint Surg. British volume.* 2003; 85-B(3): 313–318, doi: [10.1302/0301-620x.85b3.14147](#).
16. Oh CS, Chung IH, Koh KS. Anatomical study of the accessory head of the flexor pollicis longus and the anterior interosseous nerve in Asians. *Clin Anat.* 2000; 13(6): 434–438, doi: [10.1002/1098-2353\(2000\)13:6<434::AID-CA7>3.0.CO;2-4](#), indexed in Pubmed: [11111895](#).

17. Pai MM, Nayak SR, Krishnamurthy A, et al. The accessory heads of flexor pollicis longus and flexor digitorum profundus: Incidence and morphology. *Clin Anat.* 2008; 21(3): 252–258, doi: [10.1002/ca.20612](https://doi.org/10.1002/ca.20612), indexed in Pubmed: [18351652](https://pubmed.ncbi.nlm.nih.gov/18351652/).
18. Park JJ, Roh YT, Jeong C, et al. Spontaneous anterior interosseous nerve syndrome: clinical analysis of eleven surgical cases. *J Plast Surg Hand Surg.* 2013; 47(6): 519–523, doi: [10.3109/2000656X.2013.791624](https://doi.org/10.3109/2000656X.2013.791624), indexed in Pubmed: [23627594](https://pubmed.ncbi.nlm.nih.gov/23627594/).
19. Roy J, Henry BM, Pękala PA, et al. The prevalence and anatomical characteristics of the accessory head of the flexor pollicis longus muscle: a meta-analysis. *Peer J.* 2015; 3: e1255, doi: [10.7717/peerj.1255](https://doi.org/10.7717/peerj.1255), indexed in Pubmed: [26557419](https://pubmed.ncbi.nlm.nih.gov/26557419/).
20. Riveros A, Olave E, Sousa-Rodrigues C. Estudio Anatómico del Fascículo Accesorio del Músculo Flexor Largo del Pulgar y su Relación con el Nervio Interóseo Anterior en Individuos Brasileños. *Int J Morphol.* 2015; 33(1): 31–35, doi: [10.4067/s0717-95022015000100004](https://doi.org/10.4067/s0717-95022015000100004).
21. Sharma M, Chabbra U, Kaushal S, et al. Accessory head of flexor pollicis longus muscle. *J Exerc Sci Physiother.* 2008; 4(1): 15–18.
22. Shirali S, Hanson M, Branovacki G, et al. The flexor pollicis longus and its relation to the anterior and posterior interosseous nerves. *J Hand Surg Br.* 1998; 23(2): 170–172, indexed in Pubmed: [9607652](https://pubmed.ncbi.nlm.nih.gov/9607652/).
23. Spinner M. The anterior interosseous-nerve syndrome, with special attention to its variations. *J Bone Joint Surg Am.* 1970; 52(1): 84–94, indexed in Pubmed: [5411776](https://pubmed.ncbi.nlm.nih.gov/5411776/).
24. Standring S. *Gray's Anatomy: The Anatomical Basis of Clinical Practice.* 41st ed. Elsevier; 2016: 837–861.
25. Tabib W, Aboufarah F, Asselineau A. Compression du nerf interosseux antérieur par le muscle de Gantzer. *Chirurgie de la Main.* 2001; 20(3): 241–246, doi: [10.1016/s1297-3203\(01\)00041-5](https://doi.org/10.1016/s1297-3203(01)00041-5).
26. Ulrich D, Piatkowski A, Pallua N. Anterior interosseous nerve syndrome: retrospective analysis of 14 patients. *Arch Orthop Trauma Surg.* 2011; 131(11): 1561–1565, doi: [10.1007/s00402-011-1322-5](https://doi.org/10.1007/s00402-011-1322-5), indexed in Pubmed: [21611763](https://pubmed.ncbi.nlm.nih.gov/21611763/).
27. Uyaroglu FG, Kayalioglu G, Erturk M. Incidence and morphology of the accessory head of the flexor pollicis longus muscle (Gantzer's muscle) in a Turkish population. *Neurosciences (Riyadh).* 2006; 11(3): 171–174, indexed in Pubmed: [22266615](https://pubmed.ncbi.nlm.nih.gov/22266615/).