

The applied anatomy and clinical significance of the proximal, V1 segment of vertebral artery

X. Li^{1#}, L. Guan^{1#}, Prince L.M. Zilundu^{2#}, J. Chen¹, Z. Chen¹, M. Ma¹, H. Zhuang¹, Z. Zhuang¹, Y. Qiu¹, F. Ye¹, X. Wu¹, H. Sang¹, Y. Ye¹, Y. Han¹, H. Yao², H. Li², G. Zhong², H. Wu², Z. Jiang², G. Chu², D. Xu², L. Zhou^{1,2}

¹Zhongshan School of Medicine, Sun Yat-sen University, Guangzhou City, Guangdong Province, China

²Department of Human Anatomy, Zhongshan School of Medicine, Sun Yat-sen University, Guangzhou City, Guangdong Province, China

[Received: 31 December 2018; Accepted: 6 March 2019]

Background: The aim of the study was to probe the morphological features of the proximal segment (V1) of vertebral artery (VA) in a sample of Chinese cadavers.

Materials and methods: The origin, course and outer diameter at origin of the pre-vertebral part of the VAs were evaluated in 119 adult cadavers.

Results: It was found that 94.12% of the VAs originated from the subclavian arteries, bilaterally. The variant origins were present in 5.88% of the cadavers and all originated directly from the arch of the aorta. All the variations were observed on the left side of male cadavers. The average outer diameters at origin of the normal and variation groups were 4.35 ± 1.00 mm and 4.82 ± 1.42 mm, respectively, $p = 0.035$. In the normal group, but not in the variation group, the average diameter in the males was significantly larger than that in the females (4.50 ± 0.99 mm, 3.92 ± 0.92 mm, respectively, $p = 0.000$). In addition, only 5 cadavers in the normal group had hypoplastic VAs (4.20%, 4 males, 3 right-sided). Vertebral artery dominance (VAD) was present in 91 (69 males) out of 112 cadavers and more common on the left ($n = 48$). In addition, 3 cadavers satisfied conditions for coexistence of VAD and vertebral artery hypoplasia. All 7 cadavers in the variation group exhibited VAD, which was more common on the right side ($n = 5$).

Conclusions: The morphologic variations and frequencies described above have implications for the early prevention, abnormal anatomy detection, accurate diagnosis, safe surgery and endovascular treatment of cardiovascular and neurological disease. (Folia Morphol 2019; 78, 4: 710–719)

Key words: anatomy, vertebral artery — hypoplasia, dominance

INTRODUCTION

The vertebral artery (VA) takes origin from the supero-posterior subclavian arteries on each side. It is the primary blood supply for posterior circulation central nervous system structures such as the spinal cord, inner ear, the brainstem, cerebellum, midbrain,

thalamus, and areas of temporal and occipital cortices [10, 32]. Therefore, any change in VA haemodynamics may cause important disorders in cerebellum, brain stem, inner ear and spinal cord. Incidentally, atherosclerosis, cardioembolism and congenital disorders are leading causes of ischaemic strokes of the pos-

Address for correspondence: Dr. D. Xu, Dr. G. Chu, Department of Anatomy, Zhongshan School of Medicine, Sun Yat-sen University, No. 74 Zhongshan 2nd Road, Guangzhou City, Guangdong Province, 510080, People's Republic China, tel: +8687332332, e-mail: 462695262@qq.com; chugl@mail.sysu.edu.cn

#X. Li, L. Guan and Prince L.M. Zilundu contributed equally to this work.

terior circulation territory [3]. In addition, posterior circulation strokes represent approximately 20% of all ischaemic strokes [13], thereby making the vertebral arterial tree very important clinically.

Normally, the VA is divided into four segments, namely: proximal segment (V1), transverse process segment (V2), suboccipital segment (V3), and intracranial segment (V4) [47]. V1 is the most proximal segment from the VA origin to point of entry into the initial foramen transversarium, usually at the level of the sixth cervical vertebral body [24]. The tapering diameters, bilaterally, of the vertebral arteries' V1 segments are usually unequal [42], ranging from 2 mm to 7.5 mm. The current study focused mainly on the V1 segment and explored its variations such as the aberrant origin, size, and presence of vertebral artery dominance (VAD) or vertebral artery hypoplasia (VAH). The V1 segment is more prone to atherosclerotic change, particularly at its origin [24]. Additionally, the risk of VA injury during anterior surgical decompression of the cervical spine is greatly increased when the anatomy is atypical [8]. Although a few studies describing the anatomical variations of the V1 segment of the VA have been conducted earlier, data from China is scarce [22, 38].

According to Hong et al. [15], VAH is associated with pontine or posterior inferior cerebellar artery territory infarctions. In addition, the incidence of posterior circulation infarctions is higher in VAD patients, especially in the posterior inferior cerebellar and basilar artery territories [48]. However, there is no consensus among researchers and clinicians over the exact definitions of VAD and VAH [7]. Discordance also exists in the literature regarding which side is dominant in several populations. Some researchers have reported left vertebral dominance [35, 51], others right [1, 7] whilst others reported no difference at all [29]. Previously, VAH was defined as a VA diameter < 2.5 mm [11] and VAD was defined as the side to side diameter difference ≥ 0.3 mm [14]. To provide anatomical data for medical education, clinical diagnosis and treatment, 119 cadavers were evaluated for VAs' dimensional characteristics, course and origin variations. For comparison purposes, we also examined different criteria from the literature to determine the VAD, VAH and rate of co-dominance of hypoplasia of the VA, emphasizing some morphological, functional and clinical data about this rare vascular abnormality, in order to offer useful information to anatomists, radiologists, vascular and head-and-neck surgeons.

MATERIALS AND METHODS

The present study was based on a sample of 119 formalin fixed adult cadavers which were offered by the Department of Human Anatomy, Sun Yat-sen Zhongshan School of Medicine (90 males, 29 females). Their ages ranged from 55 to 85 years old. All cadavers were inspected for any evidence of surgery performed on the cervical and axillary regions and none of the them had any apparent history of surgery. Information available on each cadaver does not include cause of death or medical/surgical history. The vertebral arteries of both sides of 119 cadavers were dissected and evaluated for dimension, length, origin (normal or aberrant), course (tortuosity) and level of entry into respective foramen transversarium.

Morphometry

The external diameters at the beginning of each VA were measured using a Vernier callipers with an accuracy of 0.02 mm.

Statistical analysis

We used SPSS 20.0 for statistical analysis. Descriptive statistics (mean, minimum, maximum, range, standard deviation, and variance) were computed using SPSS. Comparability between groups was tested using the independent two-sample *t*-test for continuous variables and the χ^2 test for categorical variables. Continuous variables were represented as mean \pm standard deviation, and categorical data were represented by number (N) and percentage. The *t*-tests were performed to compare the data between different sides and genders in normal origin group and anomalous group. Chi-square tests were performed to analyse the relationship between sex, origin and the incidence of VAD and VAH. P-values less than 0.05 were considered statistically significant.

RESULTS

Origin of vertebral artery

Of the 119 cadavers, 75.63% (90/119) were male and 24.37% (29/119) were female. In 112 (94.12%) cadavers, the VA originated from the usual first part of the subclavian artery, bilaterally, while variations were present in the remaining cadavers ($n = 7$, 5.89%). In the variation group, the left vertebral artery (LVA) originated directly from the arch of the aorta of all the 7 male cadavers. There were no other associated anomalies in the V1 segment.

Table 1. Descriptive summary of V1 vertebral artery measurements in normal and variation groups

	Normal group morphometries					Variation group morphometries		
	All sides	Side		Sex		Side		All sides
	Both	Left	Right	Male	Female	Left	Right	Males
Number	224	112	112	166	58	7	7	14
Mean	4.35	4.44	4.27	4.50	3.92	4.82	5.06	4.94
Minimum	2.07	2.07	2.36	2.07	2.17	3.35	3.27	3.27
Maximum	7.38	7.32	7.38	7.38	6.05	7.15	6.38	7.15
Range	5.31	5.25	5.02	5.31	3.88	3.80	3.11	3.88
Standard deviation	1.00	1.01	0.99	0.99	0.92	1.42	0.96	1.17
Variance	1.01	1.03	0.99	0.98	0.85	2.01	0.92	1.37
P-value		0.190		0.000		0.717		

Table 2. Vertebral artery hypoplasia/vertebral artery dominance (VAH/VAD); incidences in normal and variation groups

Parameter	Sex: all cadavers		Variation group (males only)		Normal group		Incidence of VAH and VAD	P
	Male	Female	Left	Right	Left	Right		
VAD	76	22	2	5	48	43	98 (82.35%)	0.557
Non-VAD	14	7						
VAH	4	1	0	0	3	2	5 (4.20%)	1.000
Non-VAH	86	28						
P-value				0.414				

Morphometries of the vertebral arteries

The detailed presentation of the morphometries of the vertebral arteries (V1) in normal and variation groups are summarised in Table 1. The average V1 VA diameter in the normal group was 4.35 ± 1.00 mm, which was significantly smaller than that in the variation group (4.82 ± 1.42 mm, $p = 0.035$). In addition, average male cadavers' VA diameter was found to be significantly wider (4.50 ± 0.99 mm) than that of females (3.92 ± 0.92 mm; $p = 0.000$). The difference between the diameters of the left and right VAs in the normal group were not statistically significant, although the right side was generally wider.

All the cadavers with aberrant, aortic origin (variation group) of VAs were male. Although the cadavers' right VAs were generally larger (5.06 ± 0.96 mm) than those on the left (4.82 ± 1.42 mm), the difference was not statistically significant ($p = 0.717$) (Table 1). In addition, Table 1 shows that the recorded minimum diameters of both left and right VA (3.27 mm) in this group were way above the set criteria for VAH (diameter < 2.5 mm). As also shown in Table 1, the average difference between the thinnest

and the thickest vertebral arteries was greater in males (5.31 mm) than that of females (3.88 mm).

Sex and incidence of VAH and VAD

Results in Table 2 show the incidence of VAH and VAD among the males and females in the normal and variation groups. In the normal group, there were only 5 cadavers with VAH according to the criteria of Gaigalaite et al. [11] giving an incidence of 4.20%. In 3 cadavers there was left VAH while the remaining 2 exhibited right sided VAH. Four of the cadavers with VAH were male. As noted earlier, the VA diameter in the variation group were all larger than the set criterion for VAH.

As shown in Table 2, occurrence of VAD in the normal group was observed in 91 cadavers out of 112. Figure 1 shows a typical case of right sided vertebral dominance in which the LVA (2.18 mm, labelled 2) was thinner than the right vertebral counterpart (5.24 mm, labelled 7). Results from our normal group also showed that VAD was more common on the left ($n = 48$) then on the right ($n = 43$). More males had VAD ($n = 69$) then females ($n = 22$). The differences

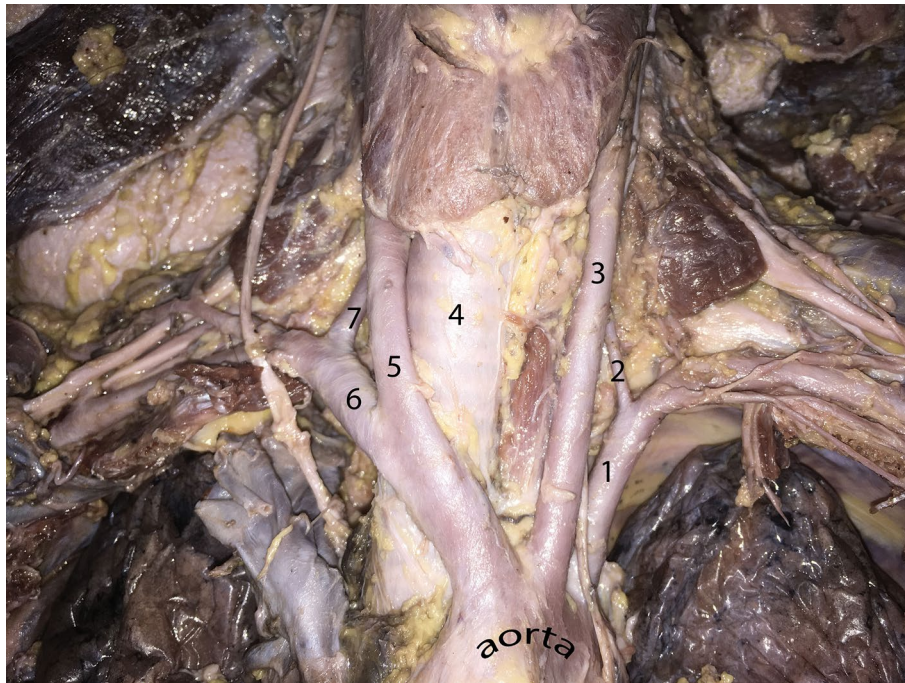


Figure 1. A typical case of right vertebral artery dominance (VAD) and left vertebral artery hypoplasia (VAH); 1 — left subclavian artery; 2 — left vertebral artery (2.18 mm); 3 — left common carotid artery; 4 — trachea; 5 — right common carotid artery; 6 — right subclavian artery; 7 — right vertebral artery (5.24 mm).

between sexes and sidedness of the dominance were, however, not statistically significant.

On the other hand, in the variation group, all the 7 cadavers exhibited VAD according to the criterion of Han et al. [14]. Table 2 also shows that right sided VAD was present in 5 cadavers while left sided VAD occurred twice. We also noted that 3 cadavers exhibited co-existence of VAD and VAH. This scenario is also depicted in Figure 1. This Figure 1 is an example of situation where the difference in the sizes of the two arteries satisfied the criteria for VAD (difference between the left and right VAs was above 0.3 mm) as well as that of VAH in which one of the VAs has a diameter under 2.5 mm.

Course of vertebral arteries

Upon close examination, we observed that there was nothing unusual about the course of the V1 segments of the VAs in all the 112 cadavers in the normal group with respect to origin, course, branches, tortuosity and entry into the foramen transversarium of the sixth cervical vertebra. However, in 4 of the 7 cadavers in the variation group we observed that the right V1 segments had some sinuous course, which was not very prominent, and appeared to be moulded around the convexities formed by the

seventh cervical vertebral transverse process. The left side V1 had a fairly straighter upward course. In 4 cadavers in the variation group we observed that the entry level of the left V1 segment occurred at the 5th cervical transverse foramina instead of the 6th, thus taking a longer upward course. There were no other abnormalities such as dual arteries, duplication, fenestration, tortuosity, kinking, arachnoid cysts, aneurysmal formation which were apparently observed in this region.

DISCUSSION

The two VAs, which usually arise from the ipsilateral subclavian arteries, converge into the basilar artery as an important blood supply of the central nervous system structures such as brainstem and cerebellum. It is not uncommon to find variations in the prevertebral segment of the VA because the region is devoid of bony structures [40]. Although the aberrant anatomic origins of the VA are rare and usually is asymptomatic [24], it is critical to identify them before performing open surgery of the supra-aortic vessels or endovascular interventions [34, 43], among other interventions. In addition, direct aortic origin of the left VA is the most frequent anatomic variant of the VA, which predisposes to arterial dissection [43].

In the present study, all the origin variations occurred on the left side and the LVA originated directly from the arch of the aorta.

Attempts to set a universally agreed upon criterion for diagnosing VAH have not yielded consensus as yet and operational definitions of VAH vary between diameters of less than 2 mm to less than 3 mm [17]. Numerous studies use different subjects often made up of small samples leading to the discordance. Park et al. [25] defined VAH as VA diameter less than 2 mm on magnetic resonance imaging and found an incidence of 35.2% in a Korean sample (3.4% of the sample had VAH bilaterally). Earlier on Touboul et al. [33] defined VAH as lumen diameter < 3 mm and reported an incidence of 6% in 50 healthy subjects while a little later Delcker and Diener [6] reported 1.9% VAH (≤ 2 mm) in 451 subjects who underwent ultrasonography. In our cadaveric study we report a VAH incidence of 4.20%, which is within the range of previously reported incidences although there is a wide variance of samples and methods of assessment.

However, there have been extremes of incidences reported previously in the literature. For instance, Zhang et al. [46] reported that 64 of 245 patients (26%) had VAH as defined by the luminal diameter of a VA ≤ 2 mm. Ideally normative data and diagnostic criteria must be population-specific and sometimes patient-specific because VA diameter showed a significant dependence on sex as well as anthropometric parameters (height) [11]. In addition, accompanying data from modern radiological tools such as colour coded duplex ultrasonography must be employed in each study or clinical population [17] in order to augment diagnosis. VAH is not rare in the normal population [25], and is frequent in patients with non-cardioembolic posterior circulation ischaemic events rather than in asymptomatic patients [11]. As a consequence, researchers have provided evidence which suggest that people with VAH may have a high probability of posterior circulation strokes [46], with atherosclerotic susceptibility and ipsilateral lesions in the VA territory, partly because the smaller of paired arteries are more vulnerable to occlusion [20, 25].

Vertebral artery dominance is a common congenital variation of VA. Several researchers have reported equal sizes of VAs only in 6% to 26% of patients in different settings and populations [17]. Therefore, VAs are either of equal size (VA codominance) or one side is significantly wider (VA dominance) [18]. The left side is most commonly found to be dominant

in VA origin and co-dominance is the second most common form in VAs [15, 17, 18]. Just like VAH, there is no consensus on the definition of VAD. In the present study, we adopted Hong et al. [15] standard that VAD is present when both sides of the VA diameters differed by ≥ 0.3 mm. This is however a very sensitive definition that gives little room for codominance and therefore incidence of VAD is inherently high (82.35%). In our present study, there was a tendency towards right hand dominance, although this difference was not statistically significant. Previously, other researchers reported right vertebral dominance in their samples [1, 7]. Interestingly, other researchers have used a wider vertebral artery diameter difference of more than 1.2 mm. According to Zhu et al. [49], VAD was present when the difference in diameters of two vertebral arteries was greater than 1.2 mm. They found that the left VA was larger (dominant), as was reported previously using the same criteria [17, 23]. Using this criterion on our data only reduces the prevalence of VAD, as expected. However, in the clinical practice and research settings, there is a need to balance sensitivity of tests and also integration of clinical data and that of other modalities, where present, in order to make a diagnosis of VAD or associate it with cerebrovascular events. Table 3 summarises the salient features and different criteria used by various researchers and clinicians in previous publications. This Table 3 shows widespread discordance in the criteria used and, therefore, calls for modality-based criterion that would be valid, reliable and sensitive to detect both VAD and VAH, where present, in clinical practice. Such data would be useful to make diagnosis accurate and endovascular intervention as well as surgery safer.

Previously ignored as an embryological vestige, accumulating evidence now supports the notion that VAD has significant connections with the angulation and elongation of basilar artery as well as being a risk factor for posterior circulation cerebral events [23, 25, 49]. Therefore, it is being consistently shown that VAD increases the risk of posterior circulation infarction [49]. It is thought that the unequal mechanical force of vascular wall in the bilateral VAs and the high vascular resistance of the side opposite to the of VAD leads to a high probability of atherosclerotic lesions. These, coupled with the bending of basilar artery, changes the blood flow pattern of the posterior circulation [15]. Consequently, the occurrence of the common cardiovascular disease such

Table 3. Summary of various studies using different criteria to define vertebral artery hypoplasia (VAH) and vertebral artery dominance (VAD)

Authors, year	Sample	Method	Criterion and prevalence	
			VAD	VAH
Fisher et al., 1965 [9]	178 cadavers (91males), USA	Pathoanatomical study	N/A	< 2 mm: right (5%), left (2%)
Touboul et al., 1986 [33]	50 normal subjects (20 males, 30 females), France	Ultrasonographic study	Difference \geq 1 mm: left 24 (48%); right 7 (14%)	< 3 mm: 3 (6%) cases: left 2, right 1
Delcker and Diener, 1992 [6]	451 patients, German	Extracranial CW Doppler sonography, transcranial Doppler sonography and colour-coded duplex sonography	N/A	Revealed a decrease in blood flow velocity in VAs with diameters less than 2 mm, based on a hypoplasia rate of 1.9%
Smith and Bellon, 1995 [30]	15 volunteers, Canadians	MRA	A dominant VA being one at least 30% greater in diameter (just for definition)	N/A
Grasso et al., 2005 [12]	6 formalin-fixed cadaveric heads, Italians	Microanatomy dissection	Difference \geq 0.8 mm left (4/6)	N/A
Yokoyama et al., 2005 [41]	20 patients with aneurysm, Japanese	CDU	Diameter ratio more than 1.4: Dissecting aneurysm was observed in 5 patients (1 in dominant VA and 4 in non-differentiated VA). Aneurysmal change was absent in the patients with dissection in hypoplastic VA	N/A
Cagnie et al., 2006 [2]	50 subjects (29 right handers, 21 left handers) with a mean age of 21.3 ± 2.5 years (ranging from 19 to 26 years), Belgium	Ultrasonographic investigation	The side-to-side diameter difference was greater than the standard error of measurement (0.16 mm): left (54%); right (30%); equal (16%); no correlation between differences in VA diameter and hand dominance can be found	N/A
Perren et al., 2007 [26]	725 sequentially admitted first-ever stroke patients, European	Colour-coded duplex flow imaging	N/A	\leq 2.5 mm: 13% in posterior circulation territory infarction (247); 4.6% in strokes in other territories, $p < 0.001$
Min and Lee, 2007 [23]	410 patients, Korean	MRA	N/A	Hypoplasia (diameter less than 50% of the contralateral side): 98 (23.9%); more common on the right side (63.3%, 62/98) Aplasia (non-visualisation of VA): 14 (3.4%); more common on the left side (64.3%, 9/14)
Songur et al., 2008 [31]	104 cadavers, Turks	Autopsy study	Difference \geq 1 mm right (17.3%), left (21.2%)	\leq 2 mm: right (20.2%), left (14.4%), both (4.8%)
Hong et al., 2009 [15]	91 patients with acute unilateral pontine or PICA territory infarcts, South Korean	CTA	Two criteria: 1) difference $>$ 0.3 mm 2) the VA was connected with the BA in more of a straight line 1) 84 (92.3%) patients; 2) 7 patients left VAD (69.2%; $p < 0.001$)	N/A

→

Table 3 (cont). Summary of various studies using different criteria to define vertebral artery hypoplasia (VAH) and vertebral artery dominance (VAD)

Authors, year	Sample	Method	Criterion and prevalence	
			VAD	VAH
Ergun et al., 2016 [7]	254 patients (133 males, 121 females), Turks	DSA	Difference in any diameter: co-dominance (3.1%), right (49.7%), left (47.2%) Difference \geq 0.3 mm: co-dominance (18%), right (42.1%), left (39%) Difference \geq 0.8 mm: co-dominance (50.8%), right (26.4%), left (22.8%) Difference \geq 1 mm: co-dominance (62.6%), right (20.1%), left (17.3%) Diameter ratio more than 1.4: co-dominance (66.1%), right (17.8%), left (16.1%)	\leq 2 mm: right (7.1%), left (9.4%)
Gaigalaite et al., 2016 [11]	367 symptomatic PCS or TIA, 742 asymptomatic subjects, Lithuanian	MRI or CT and MRA or CTA	N/A	$<$ 3 mm: 58.3% in PCS or TIA; 31.3% in asymptomatic subjects, $p <$ 0.01 $<$ 2.7 mm: the optimal VA diameter to increase the risk of PCS stenosed/occluded VA $<$ 2.2 mm: a risk factor of a severe distal VA stenosis or occlusion
Jeng and Yip, 2004 [17]	447 healthy subjects (231 men, 216 women), Chinese	CDU	Difference $>$ 0.3 mm: VA asymmetry (68.9%), right (22.4%), left (46.5%)	$<$ 2.2 mm (cut-off point through scatter plotting and ROC curve analyses: difference \geq 0.12 cm, side-to-side flow volume ratio \geq 5 and resistance index \geq 0.75): right (7.8%), left (3.8%)
Chen et al., 2010 [4]	1000 healthy subjects (582 men, 418 women), Chinese	CDU	N/A	\leq 2.5 mm (an ideal value for the discrimination of marked flow asymmetry and low flow volume of VA): left (3.3%), right (5.9%); \leq 2 mm: left (0.1%), right (0.2%); \leq 2.5 mm: left (25.4%), right (35.6%)
Wang, 2012 [39]	134 patients, Chinese	MRA	Difference $>$ 1.2 mm (just for definition). The incidence of posterior circulation infarcts and basal artery curvature is higher in VAD patients	N/A
Hu et al., 2013 [16]	841 stroke patients (264 women, 577 men), Chinese	MRA or CTA	N/A	1) $<$ 2 mm; 2) the whole artery was slim or absent: 10.8%; in VAH: right (56.9%), male (78.0%) VAH: an independent risk factor for PCI stroke
Lu et al., 2013 [21]	41 vertigo patients with VAD; 36 vertigo patients without VAD, Chinese	MRA	Difference $>$ 0.3 mm: mild subgroup (0.04–0.70 mm); moderate subgroup (0.70–1.17 mm); severe subgroup (\geq 1.17 mm); The abnormal rate of BA shape was higher in VA dominance vertigo; the more severe the variation, the more common of recurrent vertigo attacks and infarction in vertebral-basilar artery system	N/A

→

Table 3 (cont). Summary of various studies using different criteria to define vertebral artery hypoplasia (VAH) and vertebral artery dominance (VAD)

Authors, year	Sample	Method	Criterion and prevalence	
			VAD	VAH
Wang et al., 2014 [36]	37 Wallenberg syndrome (A), 452 control cases (B), Chinese	DSA	Difference > 0.3 mm A (51.35%): left (63.16%), right (36.84%) B (30.75%): left (56.12%), right (43.88%); $p = 0.010$	1) ≤ 1.5 mm; 2) diameter ratio < 1/3: A 16.22%: left (33.33%), right (66.67%), B (4.65%); $p = 0.010$
Wang et al., 2016 [37]	2370 adults (1348 men), Chinese	Thoracic enhanced CT, left VA, which directly originated from the arch, was associated with right VAD and left VAH	≥ 1.3 -fold of the contralateral diameter: Total (n = 2370): 41.7%: left 661 (27.9%); right 328 (13.8%) Normal origin (n = 1985): left 582 (29.3%); right 224 (11.3%); left VA originated directly from aortic arch (n = 126): left 10 (7.9%); right 70 (55.6%); $p < 0.001$	≤ 2.5 mm: Total (n = 2370): 11.9%: left 104 (4.4%), right 172 (7.3%), bilateral VAH 6 (0.3%) Normal origin (n = 1985): left 71 (3.6%); right 144 (7.3%); left VA originated directly from aortic arch (n = 126): left 22 (17.5%); right 5 (4.0%), $p < 0.001$
Zhang et al., 2016 [46]	245 patients with isolated vertigo with at least 1 vascular risk factor, Chinese	MRA or CEMRA	N/A	≤ 2 mm, slim or absent VA to CEMRA, or a diameter ratio for the 2 VAs > 1:1.7: 26% (64 of 245)

BA — basilar artery; CDU — colour Doppler ultrasonography; CEMRA — cervical contrast-enhanced MRA; CT — computed tomography; CTA — computed tomography angiography; CW — continuous-wave; DSA — digital subtraction angiography; MRA — magnetic resonance angiography; MRI — magnetic resonance imaging; NA — data not available or mentioned in the article; PCI — percutaneous coronary intervention; PCS — posterior circulation stroke; PICA — posterior inferior cerebellar artery; ROC — receiver operation characteristic; TIA — transient ischaemic attack; VA — vertebral artery

as atherosclerotic disease and transient ischaemic attack in the territory becomes commonplace [22]. Some scholars have suggested that VAD contributes to the vertebrobasilar dolichoectasia, a condition in which the vertebral/basilar artery is elongated, distended and tortuous leading to diminished blood supply and haemodynamic changes manifest clinically by compression of the cranial nerves, ischaemic symptoms or intracranial bleeding [19, 44]. As a result, VAD has been posited as an independent risk factor of vertigo and also related to the severity of this condition [5, 45]. However, in the present study we only observed a slight tendency towards tortuosity of the right VA in 4 cases that exhibited VAD. Tortuosity was not very apparent, although the LVA of our samples took a longer course owing to aortic origin inferiorly and foramen transversarium entry above the usual C6 level.

There is no general agreement on the underlying mechanism of asymmetry in the VA diameter. Ren et al. [28] suggested that most people prefer to use right hand, resulting in more exercise in the left cerebrum. The more the exercise the left cerebrum obtain, the more blood it needs, causing the enlarged aortic origin of the LVA or the left VAD. However, Cagnie et

al. [2] had earlier found that no correlation between differences in VA diameter and hand dominance existed, thus there is no significant connection between VAD and hand preference. As we noted previously [27], the embryologic origin of the present variation (LVA arising aortic arch) arises when the anastomosis between the 6th and 7th intersegmental arteries does not develop on the left side. In this scenario, the 6th intersegmental artery remains, leading to the LVA arising from the aortic arch between the left common carotid and subclavian arteries. It is, thus, possible that such a direct origin of the LVA from the high-pressure aortic arch would result in a wider artery, which is consistent with our present observation that all the cadavers in this group had no VAH but wide bore left VAs. However, further research is required on this matter. Lastly, since some scholars also used VAD and VAH interchangeably, there is an urgent need for clearer definition between them. There is also apparent overlap in discussing their clinical significance [48–50]. As observed in our sample, some 3 cadavers had both VAD and VAH present and whether that adds to the burden and heightened risk of stroke remains to be elucidated. We, therefore, also suggest further study on this matter.

CONCLUSIONS

In summary, we have described the VA morphologic variations and their frequencies. The study provides basic information about the relative frequency and potential clinical importance of VAH and dominance. Results from this study suggest that VAH is less common while VAD is very common. Such implications should be considered in patients requiring thoracocervical and cranial care, especially those with subclavian artery stenosis, and patients in whom the left subclavian artery is to be covered by a thoracic endograft. Our study has emphasized some morphological, functional and clinical data about these rare vascular abnormalities, in order to offer useful information to anatomists, radiologists, vascular and head and neck surgeons. We have also attempted to summarise and highlight the width and breadth of various criteria used by different researchers, diagnosticians and clinicians in defining VAH and VAD in the hope that, in future, there would be convergence towards universal definitions.

Acknowledgements

The authors would like to thank the Department of Human Anatomy of Zhongshan School of Medicine, Sun Yat-sen University for providing the cadaveric material for this study.

Funding

This study was funded by The Quality of Education for Undergraduate in Relation to Educational Reform. Award Number: 2017/79. Recipient: Lihua Zhou.

REFERENCES

- Akar ZC, Dujovny M, Slavin KV, et al. Microsurgical anatomy of the intracranial part of the vertebral artery. *Neurol Res.* 1994; 16(3): 171–180, indexed in Pubmed: [7936084](#).
- Cagnie B, Petrovic M, Voet D, et al. Vertebral artery dominance and hand preference: is there a correlation? *Man Ther.* 2006; 11(2): 153–156, doi: [10.1016/j.math.2005.07.005](#), indexed in Pubmed: [16380285](#).
- Caplan LR, Wityk RJ, Glass TA, et al. New England Medical Center Posterior Circulation registry. *Ann Neurol.* 2004; 56(3): 389–398, doi: [10.1002/ana.20204](#), indexed in Pubmed: [15349866](#).
- Chen YY, Chao AC, Hsu HY, et al. Vertebral artery hypoplasia is associated with a decrease in net vertebral flow volume. *Ultrasound Med Biol.* 2010; 36(1): 38–43, doi: [10.1016/j.ultrasmedbio.2009.08.012](#), indexed in Pubmed: [19900752](#).
- Cosar M, Yaman M, Eser O, et al. Basilar artery angulation and vertigo due to the hemodynamic effect of dominant vertebral artery. *Med Hypotheses.* 2008; 70(5): 941–943, doi: [10.1016/j.mehy.2007.07.051](#), indexed in Pubmed: [18037573](#).
- Delcker A, Diener HC. [Various ultrasound methods for studying the vertebral artery--a comparative evaluation]. *Ultraschall Med.* 1992; 13(5): 213–220, doi: [10.1055/s-2007-1005313](#), indexed in Pubmed: [1439717](#).
- Ergun O, Gunes Tatar I, Birgi E, et al. Evaluation of vertebral artery dominance, hypoplasia and variations in the origin: angiographic study in 254 patients. *Folia Morphol.* 2016; 75(1): 33–37, doi: [10.5603/FM.a2015.0061](#), indexed in Pubmed: [26365867](#).
- Eskander MS, Drew JM, Aubin ME, et al. Vertebral artery anatomy: a review of two hundred fifty magnetic resonance imaging scans. *Spine (Phila Pa 1976).* 2010; 35(23): 2035–2040, doi: [10.1097/BRS.0b013e3181c9f3d4](#), indexed in Pubmed: [20938397](#).
- Fisher CM, Gore I, Okabe N, et al. Atherosclerosis of the carotid and vertebral arteries: extracranial and intracranial. *J Neuropathol Exp Neurol.* 1965; 24(3): 455–476, doi: [10.1097/00005072-196507000-00007](#).
- Flossmann E, Rothwell PM. Prognosis of vertebrobasilar transient ischaemic attack and minor stroke. *Brain.* 2003; 126(Pt 9): 1940–1954, doi: [10.1093/brain/awg197](#), indexed in Pubmed: [12847074](#).
- Gaigalaite V, Vilimas A, Ozeraitiene V, et al. Association between vertebral artery hypoplasia and posterior circulation stroke. *BMC Neurol.* 2016; 16: 118, doi: [10.1186/s12883-016-0644-x](#), indexed in Pubmed: [27461465](#).
- Grasso G, Alafaci C, Passalacqua M, et al. Landmarks for vertebral artery repositioning in bulbar compression syndrome: anatomic and microsurgical nuances. *Neurosurgery.* 2005; 56(1 Suppl): 160–164, doi: [10.1227/01.neu.0000146685.17628.05](#), indexed in Pubmed: [15799805](#).
- Gulli G, Marquardt L, Rothwell PM, et al. Stroke risk after posterior circulation stroke/transient ischemic attack and its relationship to site of vertebrobasilar stenosis: pooled data analysis from prospective studies. *Stroke.* 2013; 44(3): 598–604, doi: [10.1161/STROKEAHA.112.669929](#), indexed in Pubmed: [23386676](#).
- Han HX, Wang JH, Chen XF. Correlation between vertebral artery superiority and posterior circulation infarction. *J Integ Trad Chinese Western Med Cardiovasc Cerebrovasc Dis.* 2015; 13: 1555–1557, doi: [10.3969/j.issn.1672-1349.2015.13.033](#).
- Hong JM, Chung CS, Bang OY, et al. Vertebral artery dominance contributes to basilar artery curvature and peri-vertebrobasilar junctional infarcts. *J Neurol Neurosurg Psychiatry.* 2009; 80(10): 1087–1092, doi: [10.1136/jnnp.2008.169805](#), indexed in Pubmed: [19414436](#).
- Hu XY, Li ZX, Liu HQ, et al. Relationship between vertebral artery hypoplasia and posterior circulation stroke in Chinese patients. *Neuroradiology.* 2013; 55(3): 291–295, doi: [10.1007/s00234-012-1112-y](#), indexed in Pubmed: [23117257](#).
- Jeng JS, Yip PK. Evaluation of vertebral artery hypoplasia and asymmetry by color-coded duplex ultrasonography. *Ultrasound Med Biol.* 2004; 30(5): 605–609, doi: [10.1016/j.ultrasmedbio.2004.03.004](#), indexed in Pubmed: [15183225](#).
- Kalia J, Hussain S, Wolfe T, et al. 026 Prevalence of co-dominance in vertebral arteries: a CT angiographic assessment. *J NeuroInterven Surg.* 2009; 1(1): 98–98, doi: [10.1136/jnis.2009.000869z](#).

19. Kansal R, Mahore A, Dange N, et al. Dolichoectasia of vertebrobasilar arteries as a cause of hydrocephalus. *J Neurosci Rural Pract.* 2011; 2(1): 62–64, doi: [10.4103/0976-3147.80106](https://doi.org/10.4103/0976-3147.80106), indexed in Pubmed: [21716844](https://pubmed.ncbi.nlm.nih.gov/21716844/).
20. Katsanos AH, Kosmidou M, Kyritsis AP, et al. Is vertebral artery hypoplasia a predisposing factor for posterior circulation cerebral ischemic events? A comprehensive review. *Eur Neurol.* 2013; 70(1-2): 78–83, doi: [10.1159/000351786](https://doi.org/10.1159/000351786), indexed in Pubmed: [23816871](https://pubmed.ncbi.nlm.nih.gov/23816871/).
21. Lu YJ, Wang YX, Li WJ. The relationship of vertebral artery dominance and vertebrobasilar arterial insufficiency vertigo. *Chinese J Neuroimmun Neurol.* 2013; 20(4): 253–259, doi: [10.3969/j.issn.1006-2963.2013.04.007](https://doi.org/10.3969/j.issn.1006-2963.2013.04.007).
22. Matula C, Trattinig S, Tschabitscher M, et al. The course of the prevertebral segment of the vertebral artery: anatomy and clinical significance. *Surg Neurol.* 1997; 48(2): 125–131, doi: [10.1016/s0090-3019\(97\)90105-1](https://doi.org/10.1016/s0090-3019(97)90105-1), indexed in Pubmed: [9242236](https://pubmed.ncbi.nlm.nih.gov/9242236/).
23. Min JH, Lee YS. Transcranial Doppler ultrasonographic evaluation of vertebral artery hypoplasia and aplasia. *J Neurol Sci.* 2007; 260(1-2): 183–187, doi: [10.1016/j.jns.2007.05.001](https://doi.org/10.1016/j.jns.2007.05.001), indexed in Pubmed: [17604054](https://pubmed.ncbi.nlm.nih.gov/17604054/).
24. Nouh A, Remke J, Ruland S. Ischemic posterior circulation stroke: a review of anatomy, clinical presentations, diagnosis, and current management. *Front Neurol.* 2014; 5: 30, doi: [10.3389/fneur.2014.00030](https://doi.org/10.3389/fneur.2014.00030), indexed in Pubmed: [24778625](https://pubmed.ncbi.nlm.nih.gov/24778625/).
25. Park JH, Kim JM, Roh JK. Hypoplastic vertebral artery: frequency and associations with ischaemic stroke territory. *J Neurol Neurosurg Psychiatry.* 2007; 78(9): 954–958, doi: [10.1136/jnnp.2006.105767](https://doi.org/10.1136/jnnp.2006.105767), indexed in Pubmed: [17098838](https://pubmed.ncbi.nlm.nih.gov/17098838/).
26. Perren F, Poglia D, Landis T, et al. Vertebral artery hypoplasia: a predisposing factor for posterior circulation stroke? *Neurology.* 2007; 68(1): 65–67, doi: [10.1212/01.wnl.0000250258.76706.98](https://doi.org/10.1212/01.wnl.0000250258.76706.98), indexed in Pubmed: [17200496](https://pubmed.ncbi.nlm.nih.gov/17200496/).
27. Qiu Y, Wu X, Zhuang Z, et al. Anatomical variations of the aortic arch branches in a sample of Chinese cadavers: embryological basis and literature review. *Interact Cardiovasc Thorac Surg.* 2019; 28(4): 622–628, doi: [10.1093/icvts/ivy296](https://doi.org/10.1093/icvts/ivy296), indexed in Pubmed: [30445440](https://pubmed.ncbi.nlm.nih.gov/30445440/).
28. Ren BS, Ma YW, Liu YG. Measurement and variation of the outer diameter of the vertebral artery. *J Mudanjiang Med Coll.* 2013; 34(2): 72–73, doi: [10.3969/j.issn.1001-7550.2013.02.038](https://doi.org/10.3969/j.issn.1001-7550.2013.02.038).
29. Scheel P, Ruge C, Schöning M. Flow velocity and flow volume measurements in the extracranial carotid and vertebral arteries in healthy adults: reference data and the effects of age. *Ultrasound Med Biol.* 2000; 26(8): 1261–1266, doi: [10.1016/s0301-5629\(00\)00293-3](https://doi.org/10.1016/s0301-5629(00)00293-3).
30. Smith AS, Bellon JR. Parallel and spiral flow patterns of vertebral artery contributions to the basilar artery. *AJNR Am J Neuroradiol.* 1995; 16(8): 1587–1591, doi: [10.1016/S1076-6332\(05\)80504-5](https://doi.org/10.1016/S1076-6332(05)80504-5), indexed in Pubmed: [7502960](https://pubmed.ncbi.nlm.nih.gov/7502960/).
31. Songur A, Gonul Y, Ozen OA, et al. Variations in the intracranial vertebrobasilar system. *Surg Radiol Anat.* 2008; 30(3): 257–264, doi: [10.1007/s00276-008-0309-6](https://doi.org/10.1007/s00276-008-0309-6), indexed in Pubmed: [18253692](https://pubmed.ncbi.nlm.nih.gov/18253692/).
32. Tarnoki AD, Fejer B, Tarnoki DL, et al. Vertebral Artery Diameter and Flow: Nature or Nurture. *J Neuroimaging.* 2017; 27(5): 499–504, doi: [10.1111/jon.12434](https://doi.org/10.1111/jon.12434), indexed in Pubmed: [28276103](https://pubmed.ncbi.nlm.nih.gov/28276103/).
33. Touboul PJ, Bousser MG, LaPlane D, et al. Duplex scanning of normal vertebral arteries. *Stroke.* 1986; 17(5): 921–923, doi: [10.1161/01.str.17.5.921](https://doi.org/10.1161/01.str.17.5.921), indexed in Pubmed: [3764964](https://pubmed.ncbi.nlm.nih.gov/3764964/).
34. Troutman DA, Bicking GK, Madden NJ, et al. Aberrant origin of left vertebral artery. *J Vasc Surg.* 2013; 58(6): 1670, doi: [10.1016/j.jvs.2012.08.101](https://doi.org/10.1016/j.jvs.2012.08.101), indexed in Pubmed: [24280328](https://pubmed.ncbi.nlm.nih.gov/24280328/).
35. Turan-Ozdemir S, Yildiz C, Cankur NS. Evaluation of vertebral artery system in a healthy population by using colour duplex Doppler ultrasonography. (in Turkish). *Uludag Univ Tip Fak Derg.* 2002; 28: 95–99.
36. Wang J, Guo F, Wang Q, et al. Relationship between Wallenberg syndrome and vertebral artery morphological variation: report of 37 cases. *J Third Military Medical University.* 2014.
37. Wang L, Zhang J, Xin S. Morphologic features of the aortic arch and its branches in the adult Chinese population. *J Vasc Surg.* 2016; 64(6): 1602–1608.e1, doi: [10.1016/j.jvs.2016.05.092](https://doi.org/10.1016/j.jvs.2016.05.092), indexed in Pubmed: [27590535](https://pubmed.ncbi.nlm.nih.gov/27590535/).
38. Wang S, Wang C, Liu Yi, et al. Anomalous vertebral artery in craniocervical junction with occipitalization of the atlas. *Spine.* 2009; 34(26): 2838–2842, doi: [10.1097/BRS.0b013e3181b4fb8b](https://doi.org/10.1097/BRS.0b013e3181b4fb8b), indexed in Pubmed: [20010391](https://pubmed.ncbi.nlm.nih.gov/20010391/).
39. Wang YQ. Study on the correlation of vertebral artery dominance and posterior circulation infarct. *Chin J Neurol.* 2012; 45(7): 490–494, doi: [10.3760/cma.j.issn.1006-7876.2012.07.009](https://doi.org/10.3760/cma.j.issn.1006-7876.2012.07.009).
40. Xue AQ, Wang W. Anatomical features of the proximal vertebral artery and its clinical significance. *J Heze Med Coll.* 2002; 22(1): 3–4, doi: [10.3969/j.issn.1008-4118.2010.01.03](https://doi.org/10.3969/j.issn.1008-4118.2010.01.03).
41. Yokoyama Y, Fujimoto S, Toyoda K, et al. Relationships between vertebral artery diameter and dissecting aneurysm formation. *J Cerebral Blood Flow Metab.* 2005; 25(Suppl 1): S148, doi: [10.1038/sj.jcbfm.9591524.0148](https://doi.org/10.1038/sj.jcbfm.9591524.0148).
42. Yu Y, Xu ZQ, Luo BY. Vertebral artery hypoplasia and posterior circulation ischemic stroke: from hypothesis to pathogenesis. *Chin J Stroke.* 2014; 9(10): 880–884, doi: [10.3969/j.issn.1673-5765.2014.10.014](https://doi.org/10.3969/j.issn.1673-5765.2014.10.014).
43. Yuan SM. Aberrant origin of vertebral artery and its clinical implications. *Braz J Cardiovasc Surg.* 2016; 31(1): 52–59, doi: [10.5935/1678-9741.20150071](https://doi.org/10.5935/1678-9741.20150071), indexed in Pubmed: [27074275](https://pubmed.ncbi.nlm.nih.gov/27074275/).
44. Yuan YJ, Xu K, Luo Qi, et al. Research progress on vertebrobasilar dolichoectasia. *Int J Med Sci.* 2014; 11(10): 1039–1048, doi: [10.7150/ijms.8566](https://doi.org/10.7150/ijms.8566), indexed in Pubmed: [25136259](https://pubmed.ncbi.nlm.nih.gov/25136259/).
45. Zhang D, Zhang S, Zhang H, et al. Characteristics of vascular lesions in patients with posterior circulation infarction according to age and region of infarct. *Neural Regen Res.* 2012; 7(32): 2536–2541, doi: [10.3969/j.issn.1673-5374.2012.32.008](https://doi.org/10.3969/j.issn.1673-5374.2012.32.008), indexed in Pubmed: [25337106](https://pubmed.ncbi.nlm.nih.gov/25337106/).
46. Zhang DP, Lu GF, Zhang JW, et al. Vertebral artery hypoplasia and posterior circulation infarction in patients with isolated vertigo with stroke risk factors. *J Stroke Cerebrovasc Dis.* 2017; 26(2): 295–300, doi: [10.1016/j.jstrokecerebrovasdis.2016.09.020](https://doi.org/10.1016/j.jstrokecerebrovasdis.2016.09.020), indexed in Pubmed: [27746083](https://pubmed.ncbi.nlm.nih.gov/27746083/).
47. Zhang Q, Guo Y. Clinical status of vertebral artery dysplasia. *Chin J Stroke.* 2016; 11(4): 318–323, doi: [10.3969/j.issn.1673-5765.2016.04.015](https://doi.org/10.3969/j.issn.1673-5765.2016.04.015).
48. Zhu W, Wang YF, Dong XF, et al. Study on the correlation of vertebral artery dominance, basilar artery curvature and posterior circulation infarction. *Acta Neurol Belg.* 2016; 116(3): 287–293, doi: [10.1007/s13760-015-0570-5](https://doi.org/10.1007/s13760-015-0570-5), indexed in Pubmed: [26615535](https://pubmed.ncbi.nlm.nih.gov/26615535/).
49. Zhu X, Xin SJ, Wang L, et al. The relationship of vertebral artery hypoplasia and anomalous origin of vertebral artery. *J China Med University.* 2015; 44(04): 293–297, doi: [10.12007/j.issn.0258-4646.2015.04.002](https://doi.org/10.12007/j.issn.0258-4646.2015.04.002).
50. Zhuang YM. Vertebral artery hypoplasia and stroke. *Chin J Stroke.* 2010; 05(7): 536–538, doi: [10.3969/j.issn.1673-5765.2010.07.007](https://doi.org/10.3969/j.issn.1673-5765.2010.07.007).
51. Zwiebel WJ. Introduction to vascular ultrasonography, second edition. Grune and Stratton Inc., Orlando, FL 1986: 37.