

The radioanatomical research of plural renal arteries

Irena Vilhova¹, Yuriy Yarosławowicz Kryvko¹, Ryszard Maciejewski²

¹Department of Human Anatomy, Danilo Galitsky Lviv State Medical University, Ukraine

²Department of Human Anatomy, Medical University of Lublin, Poland

[Received 22 October 2001; Revised 30 October 2001; Accepted 30 October 2001]

The aim of our study was to evaluate the physiological and pathological variations of plural renal arteries in individuals of various constitutional types. Data about sixty-six renal angiographies obtained post-mortem from 35 traffic accident victims were compared with 68 aortonephrograms of 35 randomly selected patients of the Medical Department. During the autopsy of the traffic casualties no major pathological traces were observed. Out of 35 medical patients, 19 were presented with no signs of renal artery diseases, 14 were diagnosed for stenosis of renal arteries and 2 for diabetes mellitus. Abdominal aortography with following selective angiography was performed. Out of the total of 35 patients examined by method of abdominal aortography with following selective angiography, plural renal arteries (PRA) were observed in 9 cases (25.7%), two of these having a double-sided PRA. Among 19 patients without angiography, signs of renal artery pathologies PRA were present in 5 cases (26.3%). This was also observed in 2 out of 14 patients with RA stenosis (14.2%), and in both diabetic patients. Among 35 examined patients, PRA were found in 25.7% (9 cases), in two of them PRA were revealed on both sides (5.7%). A total of 68 nephrograms was obtained in 35 patients (2 patients had one kidney only). PRA were present in 16.2% (11) of nephrograms. Six (25%) out of a total of 24 men had PRA. Among 11 examined women, PRA were observed in 3 cases (27.2%). Right-sided PRA were revealed in 6 out of a total of 35 right kidneys (17.1%) and left-sided PRA in 5 (15.2%) out of 33 left kidneys. Among 35 renal preparations taken from corpses of people who died from injuries and had no renal or any other pathology, PRA were present in 9 cases (25.7%). PRA were counted in 9 cases (34.6%) of 26 preparations from corpses with advanced arteriosclerosis. Plural kidney arteries were met in 3 cases from 5 preparations taken from diabetic cadavers (60%). PRA were found in 21 (31.8%) cases out of 66 preparations examined by method of post vital angiography. PRA were noticed in 9 (28.1%) cases of 32 right side preparations, and in 12 cases (35.3%) of 34 left side preparations. PRA were observed in 11 cases (30.6%) of 36 male preparations, and in 10 cases (33.3%) of 30 female preparations. Due to the constitutional types of body: in picnic type cadavers and patients PRA were described in 12 cases (36.4%) of a total of 33, in mesomorphic type — in 8 cases (29.6%) of a total of 27, and in asthenic type cadavers — in 1 case out of 10 (10%). Total statistics showed that most often lower pole (50%) and upper pole (16.5%) accessory arteries were observed. Upper pole perforating arteries were described

in nearly 22%, but lower pole arteries only in 4.4%. Double renal arteries occurred in 18.7%, and upper pole accessory arteries in 16.5%. Triple renal arteries were found very seldom (nearly 3%).

key words: aortonephrography, renal arteries, roentgenological experiments

INTRODUCTION

Accessory renal arteries are found frequently, more often on the left side and occurring in 25–35% of cases [2, 8, 18]. These arteries usually enter the upper or lower poles of the kidney. The main clinical significance of such arteries entering the lower pole is that they may obstruct the ureter and lead to hydronephrosis. The number and course of the accessory renal arteries are more variable than previously described in the medical literature. Knowledge of these anatomical variations is important for surgeons operating in the retroperitoneum [3, 4, 6, 20, 21].

The aim of the study was to evaluate the physiological and pathological variations of plural renal arteries (PRA) in individuals of various constitutional types.

MATERIAL AND METHODS

Sixty-six renal angiography data obtained post-mortem from 35 traffic accident victims were compared with 68 aortonephrograms of 35 randomly selected patients of the Medical Department. During the autopsy of the traffic casualties no major pathological traces were observed. Out of 35 medical patients 19 were presented with no signs of renal arteries diseases, 14 were diagnosed for stenosis of renal arteries and 2 for diabetes mellitus. Abdominal aortography with following selective angiography was performed with the use of radio-paque and with the following radiological parameters: P — 75 kV, I — 9 mA, T — 10 sec.

RESULTS

According to the obtained data the following PRA classification was introduced:

- 1) Double renal arteries (RA)
- 2) Triple RA
- 3) Accessory: upper pole lower pole
- 4) Perforating: upper pole lower pole

Double kidney arteries are two vessels originating from the aorta, similar in diameter, blood supply areas, and their branches entering the kidney through the hilum (Fig. 1, 3).

Triple RA — three vessels originating from the aorta with different diameters and blood supply areas, and their branches entering the kidney through the hilum (Fig. 2).

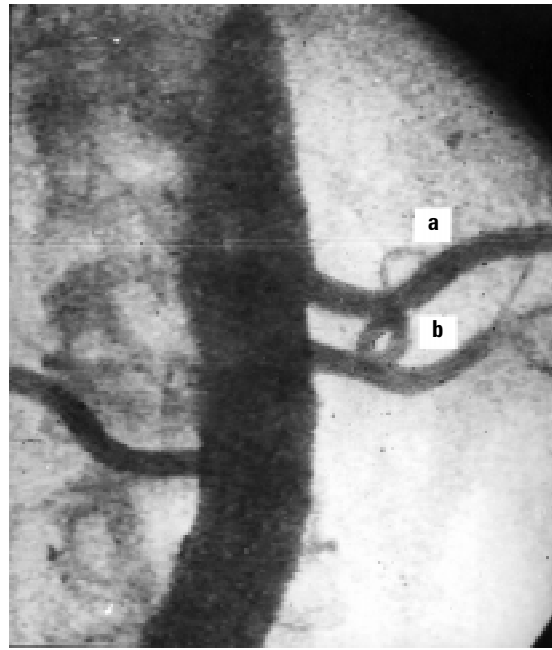

Figure 1. Aortonephrogram of the double left renal arteries. Single right renal artery; a — upper, b — lower.

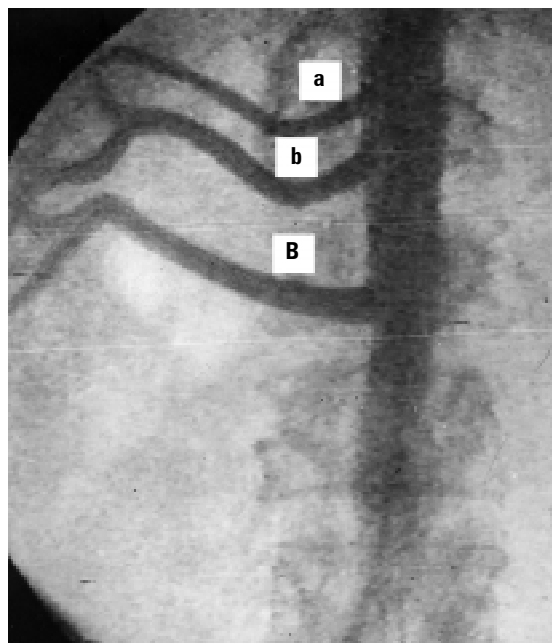


Figure 2. Aortonephrography of the triple right renal arteries. Congenital deficiency of the left kidney; a — upper branch, b — middle branch, B — lower branch.

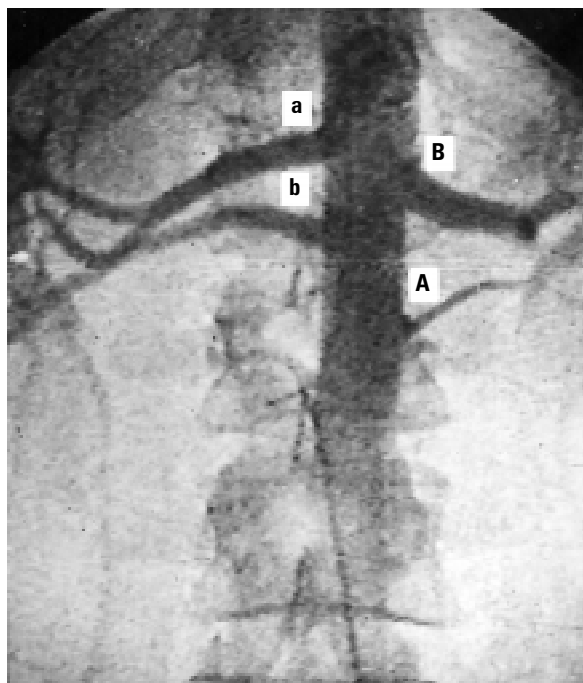


Figure 3. Angiogram of the renal branches of the aorta; a, b — double right renal arteries, B — single left renal artery, A — the left lower pole accessory artery.

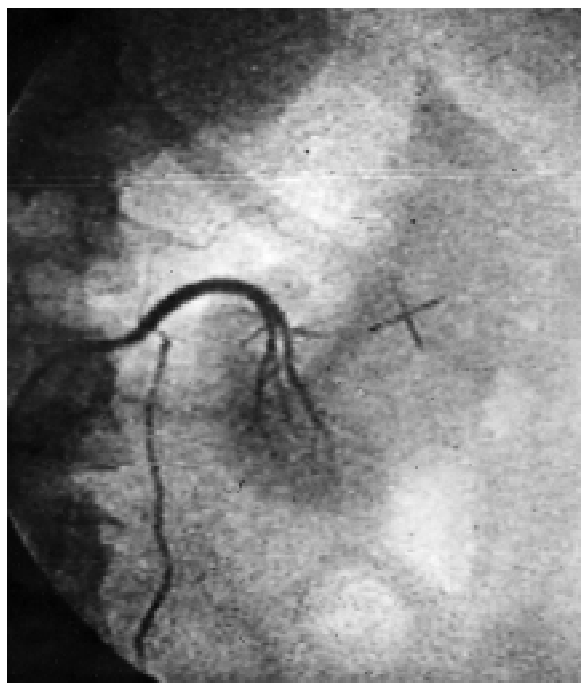

Figure 4. Selective angiography of the left renal lower perforating artery.

Accessory renal artery — originates from the aorta, the diameter of which being comparable to segmental arteries, supplying one segment only (upper or lower pole) entering the kidney through the hilum (Fig. 3).

Perforated renal artery — originates from the aorta or one of its major branches, the diameter of which being comparable to segmental or subsegmental arteries, supplying one segment only (upper or lower pole) entering the kidney outside the hilum (Fig. 4).

Out of a total of 35 patients examined by method of abdominal aortography with following selective angiography, PRA were observed in 9 cases (25.7%), two of these having a double-sided PRA. Among 19 patients without angiography signs of renal artery pathologies PRA were present in 5 cases (26.3%). This was also observed in 2 out of 14 patients with RA stenosis (14.2%), and in both diabetic patients (Table 1).

Among 35 examined patients, PRA were found in 25.7% (9 cases), in two of them PRA were revealed on both sides (5.7%). A total of 68 nephrograms were obtained in 35 patients (2 patients had one kidney only). PRA were present in 16.2% (11) of nephrograms (2 patients had a double-sided PRA). Six (25%) out of a total of 24 men had PRA. Among 11 examined women PRA were observed in 3 cases (27.2%).

Table 1. PRA frequency according to lifetime angiography data

| Examined groups of patients | Number of PRA cases | Total number of examined patients | Percent (%) |
|------------------------------|---------------------|-----------------------------------|-------------|
| With no signs of RA diseases | 5 | 19 | 26.3 |
| RA stenosis | 2 | 14 | 14.2 |
| Diabetis | 2 | 2 | 100 |
| Total number | 9 | 35 | 25.7 |

Right-sided PRA were revealed in 6 out of a total of 35 right kidneys (17.1%) and left-sided PRA in 5 (15.2%) out of 33 left kidneys.

PRA were observed in 21 cases (31.8%) of a total of 66 renal anatomical preparations. Among 35 renal preparations taken from corpses of people who died from injuries and had no renal or any other pathology, PRA were present in 9 cases (25.7%). PRA were counted in 9 cases (34.6%) out of 26 preparations from corpses with advanced arteriosclerosis. Plural kidney arteries were met in 3 cases from 5 preparations taken from diabetic cadavers (60%) — Table 2.

Table 2. The PRA frequency according to post mortem arteriography data

| Examined groups of cadavers | Number of PRA found cases | Total number of cases | Percent (%) |
|------------------------------------|---------------------------|-----------------------|-------------|
| Without any vascular pathology | 9 | 35 | 25.7 |
| With generalised arteriosclerosis | 9 | 26 | 34.6 |
| With symptoms of diabetes mellitus | 3 | 5 | 60 |
| Total number | 21 | 66 | 31.8 |

PRA were found in 21 (31.8%) cases out of 66 preparations examined by method of post vital angiography. PRA were noticed in 9 (28.1%) cases of 32 right side preparations, and in 12 cases (35.3%) of 34 left side preparations. PRA were observed in 11 cases (30.6%) of 36 male preparations, and in 10 cases (33.3%) of 30 female preparations.

Due to the constitutional types of body: in picnic type cadavers and patients, PRA were described in 12 cases (36.4%) of a total of 33, in mesomorphic type — in 8 cases (29.6%) of a total of 27, and in asthenic type cadavers — in 1 case out of 10 (10%).

Total statistics showed that most often lower pole (50%) and upper pole (16.5%) accessory arteries were observed. Upper pole perforating arteries were described in nearly 22%, but lower pole arteries only in 4.4%. Double renal arteries occurred in 18.7%, and upper pole accessory arteries in 16.5%. Triple renal arteries were found very seldom (nearly 3%).

DISCUSSION

In spite of a relatively large number of publications regarding the prevalence of plural renal arteries, the available data considering their number, level of origin and ultimate organ penetration are rather inconsistent [13, 19, 20].

Anomalous renal vessels arise as a result of the complicated development of the kidneys. Similarly, the aberrant origins of the other abdominal vessels could be explained on an embryological basis [10]. The presence of organ blood supply by additional arteries has been known from the middle of the 16th century. A particular interest in PRA appeared when the possible correlations between artheropaties and hypertension were further elaborated [17]. In more than 20% of subjects, at least one kidney is supplied by more than one artery. This aberrant renovascular

anatomy has been reported in the literature to occur in up to 80% of patients who suffer from essential hypertension [9]. These vessels are longer and narrower than the segmental arteries arising from the main renal artery. As a result, the renal segments supplied by these accessory vessels may have lower levels of blood pressure than the remainder of the parenchyma, thereby increasing the rennin secretion [8]. This hypothesis could be significant in terms of finding a casual treatment for disorders induced by this anatomical reason.

The clinical and roentgenological analyses indicate that double-sided anomaly of the kidney's blood supply, as a rule, impairs the process of urodynamics and results in the onset of various urological disorders [9, 14, 21]. So far there has been no generally accepted anatomical terminology addressing the plural renal arteries phenomena [7].

Additional arteries supplying the lower pole seem to be of the greatest importance from the practical point of view [12]. The anomalies of the kidneys and their vessels were observed very often [1, 5, 11, 15, 16]. Potential PRA crossings with ureters may be the reason for venous renal congestion and urine voiding disorders, and thus a cause of hydronephrosis, pyelonephrosis and secondary nephrolithiasis.

CONCLUSIONS

1. According to the data obtained it was concluded that there is a correlation between the PRA prevalence and the constitutional body type.
2. It seems that there is a practical need for the introduction of unified anatomical terminology regarding plural renal arteries.

REFERENCES

1. Atasever A, Hamdi-Celik H, Durgun B, Yilmaz E (1992) Unrotated left kidney associated with an accessory renal artery. *J Anat*, 181: 507–508.
2. Baniel J, Foster RS, Donohue JP (1995) Surgical anatomy of the lumbar vessels: implications for retroperitoneal surgery. *J Urol*, 153: 1422–1425.
3. Baryshnikow VL, Belle TS, Minkh NV (1990) Different types of kidney blood supply by different sicknesses. *J Radiol*, 56: 125–132.
4. Bielyj LS (1980) Current state of diagnostic of the vascular malformation of the kidney in children. *Mosc Region Clin Institute*, 28: 34–37.
5. Debatin JF, Sostman HD, Knelson M, Argabright M, Spritzer CE (1993) Renal magnetic resonance angiography in the preoperative detection of supranumerary renal arteries in potential kidney donors. *Invest Radiol*, 28: 882–889.

6. Dudarev VS, Fischer ME, Sinicyan AB (1986) Rare versions of the kidney blood supply. *Zdraw Belorusiji*, 5: 63–64.
7. Eligman SB, Boguslawskij VZ (1980) Accessory arteries of the human kidney and their genesis, Ukrainian congress of anatomists, histologists, embryologists and topographical anatomists. Vinnitsa, 65 Abstr.
8. Glodny B, Cromme S, Wortler K, Winde G (2001) A possible explanation for the frequent concomitance of arterial hypertension and multiple renal arteries. *Med Hypotheses*, 56: 129–133.
9. Hirmanow VN, Chekhuta SM, Rodionow KK, Lopatenkow GJ (1983) About the intercommunication of renal blood supply by means of multiplereal arteries and arterial hypertension. *Blood circulation*, 25: 44–46.
10. Kokoscuk GL, Dogadina IV (1998) Concerning genesis of the variability of kidney arteries. *Wisti Morfologii*, 4: 70–71.
11. Kruyt RH (1992) Vascularization of left kidney by single vessel originating from splenic artery. *Urology*, 39: 487–489.
12. Krylow AA (1982) Pathogenesis, diagnostics and treatment of the array of the disorders of the cardiovascular system. Science Academy of USSR, Leningrad.
13. Luzsa G (1974) X-ray anatomy of the vascular system. Akademiai Kiado, Budapest.
14. Mukhtarow AM, Bolgarsky IS, Mamadanowa LB (1989) Anomalies of the renal arteries and their clinical significance, IV conference of urologists and nephrologists of Bjelorus. Minsk, 143–144 Abstr.
15. Ozan H (1998) An unusual course of the right renal artery associated with an anomalous inferior vena cava. *Anat Anz*, 180: 569–572.
16. Redman JF, Aguilar-Guzman OF (1992) Ureteropelvic junction obstruction caused by accessory renal vessels in association with preureteral vena cava and vena cava duplication. *Urology*, 40: 362–367.
17. Reut LI, Savchenko AN, Krylow VP (1985) Surgical correction of the stenotic lesions of the twin renal arteries. *Zdraw Belorusiji*, 10: 56–58.
18. Singh G, Ng YK, Bay BH (1998) Bilateral accessory renal arteries associated with some anomalies of the ovarian arteries: a case study. *Clin Anat*, 11: 417–420.
19. Terescenko NK (1980) Significance of the bilateral anomalies of the renal arteries in development of urological disorders. III congress of urologists USSR. Dniepropietrowsk, 250–256 Abstr.
20. Vilhovyj VF (1975) Atlas of the rentgeno-anatomy of the vessels. Zdorowje, Kijev.
21. Vilhovyj VF, Srypnikow MS, Kens IR, Shepitko VI (1995) Atlas of retroperitoneal space organs. Astreja, Poltava.

