

Computed tomographic assisted study of morphological changes in the sutural areas as resulting from obliteration

Janusz Skrzat, Paweł Brzegowy, Jerzy Walocha

Department of Anatomy, Medical College, Jagiellonian University, Kraków, Poland

[Received 21 October 2002; Accepted 2 November 2002]

The authors have studied the morphological differences of sutural areas in human skulls at distinct stages of obliteration. A computed tomography aided with computer algorithm of tonal correction was applied to visualise structural changes in the sutural areas that are correlated with sutural ossification. The results of our study suggest that obliteration of cranial sutures is accompanied by local fluctuations of bony density in sutural areas, gradual unification of structural density towards ectocranium. When the obliteration proceeds, the sutural gap ceases. The laminae and diploic layers of the two opposing bones become a single structure of increased integrity.

key words: computerised tomography, cranial suture, ossification

INTRODUCTION

Until now investigations into obliteration of the cranial sutures have mostly concerned the timing of this process rather than an analysis of the morphological changes that accompany sutural obliteration. The beginning and rate of obliteration vary among individuals and between different types of cranial sutures [3, 6, 7].

A fully developed suture persists as an unchanged structure only for a defined period of time. Later its structure is subjected to variable morphological changes, which are related to the reorganisation of the bone tissues that comprise the sutural areas and finally lead to total ossification of the suture. The term «sutural area» includes the adjacent edges of two opposing bones, together with the intervening soft tissues [4].

Morphological changes of the cranial sutures area correlated with ageing process. The ends of the opposing bones within a suture are bound by connective tissues, which form the sutural ligament [5]. Age-

related changes of the structure of the sutural areas result from obliteration, which proceeds from the interior surface of the vault via the sutural ligament and cause its reduction and a narrowing of the gap between two bones.

The goal of our study was to detect the morphological changes of the bone matrix in the sutural areas of the human skull as a function of suture obliteration. This paper also presents an appropriate technique for imaging structural differences of the obliterating cranial sutures on the basis of computed tomographic images.

MATERIAL AND METHODS

Morphological analysis of sutural areas was performed on 10 human skulls, which showed different stages of sutural obliteration. Skull CT-scans of the completely obliterated sutures and partially obliterated sutures were compared with CT scans for non-obliterated sutures. The investigated skulls belong to the cranial collection of the Anatomical Museum

of the Department of Anatomy of the Jagiellonian University.

The study of the morphology of sutural areas was carried out with the help of computed topography and computer-assisted methods which enable the modification of obtained images (CT-scans) to improve their quality. For this purpose we employed a non-linear correction of the tonal histogram of greyscale images. The greyscale images contain black, white and two hundred and fifty-four different shades of grey. The non-linear tonal correction enabled us to modify the image so that the effect of intensification of the lights was not simultaneous with deepening of the shadows and conversely: that the lightening of the shadows would not produce additional lights, which would result in loss of visual information, which could be obtained in the images. This task was realised with the help of tonal correction of greyscale of the binary CT-scans of the skull that is obtainable in the graphic computer software. Thanks to such a procedure it was possible to select appropriate levels of greyscale ranging from 0 to 255 and re-map the grey levels within the image. In such a process of conversion the excessive dark fragments of the image become lighter, while too light ones become darker. It is also important that proportions of changes in the halftones are preserved. The applied method allowed us to demarcate borders between clusters of pixels, which are distinct in levels of grey that correlate with density of bony tissue and its distribution in sutural areas. The range of grey levels expresses the density of the structure while its gradient indicates direction of variability in structural density. Darker zones of the image show increase of the bone mineral density, while light zones indicate decrease of structural density. The grey levels of the image CT-scans correspond to the Hounsfield scale. The mean X-ray attenuation value of each pixel is expressed by the Hounsfield Unit, which depends on bone mineral density.

Radiographic studies were carried out by means of a Helicat Flash scanner (Marconi) using spiral technique. The parameters of examination were: collimation 2.7 mm, pitch 1.5, exposure factors 120 kV, 162 mAs. A zoom factor of CT-scans ranging from 2.5 to 5.0 was used in order to perceive more details in the image of the sutural area (Fig. 1).

RESULTS

We observed that the inner structure of bones in the region of non-obiterated sutures is highly heterogeneous. There is a vivid difference between dip-

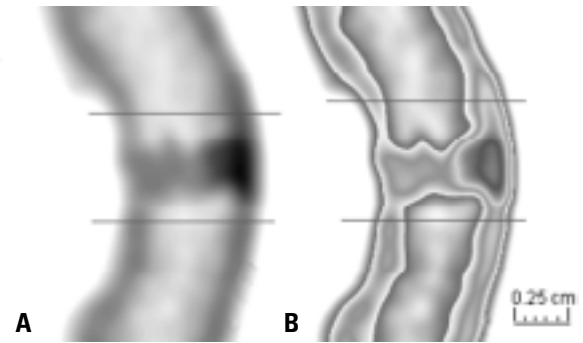


Figure 1. Axial original CT scan of non-obiterated coronal suture (A) and its counterpart (B) after tonal correction. Horizontal lines demarcate the sutural area.

loe, the external and internal lamina of the compact bone. These structures differ remarkably in their grey levels, which can be easily perceived in the CT-scans, and especially after tonal correction. Darker areas indicating increase of structural density are located mainly at the bone edges and within a suture. Local fluctuations of bony density in sutural areas were present in all specimens, however there is a gradual increase of structural density towards the ectocranium. A non-obiterated sutural area (Fig. 2A) is characterised by distinctly exposed adjacent bone edges forming a suture, a vivid gap between bones, with quite well demarcated diploe from the internal lamina and external lamina of the compact bone.

In the stage of progressive obliteration (Fig. 2B) a suture is partially ossified and local clusters of compact bone are visible on the adjacent bone edges forming the suture. A consequence of these changes is a gradual regress of the sutural gap, associated with vanishing of the fibrous connective tissue. The internal and external lamina of the compact bone

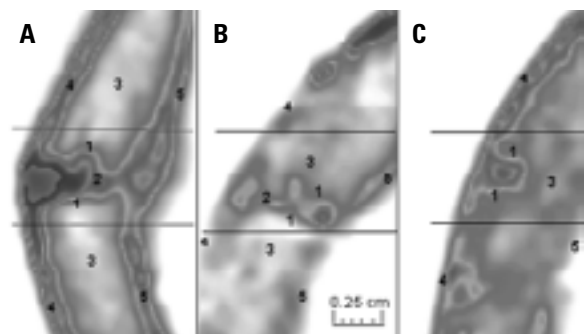


Figure 2. Comparison of structures of the sutural areas in distinct stages of obliteration; A. Non-obiterated suture; B. Partially obliterated suture; C. Completely obliterated suture; 1 — edges of the opposing bones, 2 — sutural gap, 3 — diploe, 4 — internal lamina of the compact bone, 5 — external lamina of the compact bone.

are less visible in CT-scans and they are not well demarcated from the diploe.

The partially obliterated sutures show morphological traits that indicate structural remodelling of the bone. When the obliteration proceeds, the sutural gap ceases. The laminae and diploic layers of the two opposing bones become a single structure of increased integrity. When complete obliteration occurs (Fig. 2C) one can observe in CT-scan of the sutural area the remnants of bone margins forming the suture, lack of sutural gap, which is structurally homogeneous with the diploe. These changes are often accompanied by degeneration of the inner layer of compact bone.

The performed analysis revealed remarkable differences in the inner structure of the cranial bones in the areas around the obliterated and non-obliterated sutures, according to the extent of sutural synostosis resulting from obliteration.

DISCUSSION

As the sutural obliteration proceeds, morphological changes occur in the edges of the cranial bone joined by a suture. This is a consequence of the ageing of the skull and the degree of structural reorganisation which is related to a defined suture. The period of sutural obliteration ranges basically from 2 years (e.g. metopic suture) to 70 years, when sutures of the vault are fully ossified [6]. With increasing age, alterations of the sutural appearance can be observed both on the ecto- and endocranium and they are related to disappearance of a sutural pattern, which is usually a wavy line. This observable changes of the sutural pattern result from morphological transformation arising inside the bone matrix. This process expresses in architectural relations between the inner and outer tables of the compact bone and the diploe [1]. Morphological differences of these components can be observed during sutural obliteration and analysed with the implementation of computed tomography, which allows them to be identified [2]. Additional appliance of tonal correction of tomographic images improves the di-

agnostic properties of the images. This technique enabled us easily to distinguish structures which have different bone mineral density [8]. Thus one can come to a conclusion about bone tissue distribution in the skull and local biomechanical properties, which can be presumably determined by obliteration changes inside the cranial bones. The obliteration process is tremendously extended in time and nearly spans the whole life. For that reason any structural changes in sutural areas are slow, rather even in the whole unit of the bone. In middle-age and old-age the joining edges of the cranial bones become more irregular due to the proliferation of the bony spines, which interlock in the suture [5]. Computed tomography and tonal correction appeared to be a useful tool for analyses of oblitative changes that occur in sutural areas.

REFERENCES

1. Creutz U (1977) Architecture of the human skullcap in the region of the parts bregmatica suturae sagittalis. I. Age dependence, *Gegenbaurs Morphol Jahrb*, 123 (5): 666–688.
2. Furuya Y, Edwards MS, Alpers CE, Tress BM, Ousterhout DK, Norman D (1984) Computerized tomography of cranial sutures. Part 1: Comparison of suture anatomy in children and adults. *J Neurosurg*, 61 (1): 53–58.
3. Meindl R, Lovejoy CO (1985) Ectocranial suture closure: a revised method for the determination of skeletal age at death based on the lateral-anterior sutures. *Am J Phys Antropol*, 68: 57–66.
4. Moss ML (1957) Experimental alteration of sutural area morphology. *Anat Rec*, 127: 569–589.
5. Retzlaf E, Upledger J, Mitchel F, Walsh J (1979) Aging of cranial sutures in humans. *Anat Rec*, 193: 663.
6. Todd TW, Lyon DW (1924) Endocranial suture closure, its progress and age relationship. Part I: Adult males of white stock. *Am J Phys Anthropol*, 7 (3): 325–384.
7. Todd TW, Lyon DW (1925) Cranial suture closure, its progress and age relationship. Part II: Ectocranial suture in adult males of white stock. *Am J Phys Anthropol*, 8 (1): 23–45.
8. Yamada K, Endo S, Yoshioka S, Hatazawa J, Yamaura H, Matsuzawa T (1982) Age-related changes of the cranial bone mineral: a quantitative study with computed tomography. *J Am Geriatr Soc*, 30 (12): 756–763.

