

Types of outlet of the major saphenous vein tributaries in patients with chronic vein insufficiency of the lower limbs

Konrad Janowski, Mirosław Topol

Department of Angiology, Chair of Morphology, Medical University of Łódź, Poland

[Received 13 July 2004; Accepted 3 September 2004]

Chronic vein insufficiency (CVI) is a disease which, when it develops, leads to varicose veins of the lower limbs. As approximately 25% to 50% of people suffer from it, it should be recognised as a public disease. The treatment of chronic vein insufficiency is based on a surgical approach. The aim of the operation is to remove (strip) the insufficient major saphenous vein (MSV), the main cause of the disease. The major saphenous vein drains into the femoral vein and forms the sapheno-femoral junction, which is located in the hiatus saphenous within the femoral triangle. We conducted 94 varicose vein operations by the Babcock method on patients suffering from chronic vein insufficiency. This surgical treatment was performed in "Therapy", a private clinic for peripheral vessel disease. We operated on 52 left lower limbs and 42 right lower limbs. The patients were qualified for the operation procedure after physical examination and Doppler ultrasonography imaging. We identified 5 types of major saphenous vein tributary drainage. The most common was Type I, in which there were 3 tributaries draining directly into the major saphenous vein. This type consisted of 45 cases (47.87%). We distinguished here 3 modifications. In Type II, however, there were 4 direct tributaries that drained into the major saphenous vein in 23 cases (24.46%). In this group of patients also 3 modifications were distinguished. Type III occurred in 14 cases (14.89%). We identified here 2 direct tributaries that drained into the saphenous vein and divided this type into 2 modifications. Type IV occurred in 8 cases (8.51%). Here we found 5 or 6 direct tributaries depending on the number of the external pudendal veins. Type V turned out to be very rare, occurring in only 4 cases (4.25%). Among all the types mentioned a thin tributary 1–2 mm wide was found in 10 cases (10.63%). This ran from under the fascia cribrosa into the sapheno-femoral junction in the hiatus saphenous. This may be one of the causes of the recurrences of chronic vein insufficiency. There is also the possibility that a tributary will be overlooked or ignored during the operation, particularly when Type IV appears with 5 or 6 direct collaterals.

Key words: lower limbs, chronic vein insufficiency, major saphenous vein tributaries

INTRODUCTION

Chronic vein insufficiency (CVI) is a disease which, when it develops, leads to varicose veins of the lower limbs. As approximately 25% to 50% of people suffer from it, it should be recognised as a public disease [13].

The treatment of chronic vein insufficiency is based on a surgical approach. The aim of the operation is to remove (strip) the insufficient major saphenous vein (MSV), the main cause of the disease. The major saphenous vein drains into the femoral vein and forms the sapheno-femoral junction that is located in the *hiatus saphenous* within the femoral triangle. The main tributaries drain into the latter part of the major saphenous vein (about 10 cm from the ostium). The tributaries are as follows: the superficial epigastric vein (SEV), the external pudendal veins (EPV), the superficial circumflex iliac vein (SCIV), the medial accessory saphenous vein (MASV) and the lateral accessory saphenous vein (LASV). These tributaries, or their branches that drain into the major saphenous vein separately, should be ligated very carefully. This is a very important part of an operation because the ligation all of these vessels decreases the frequency of recurrence of the condition [12]. In the literature reviewed [1–12] and the surgical operations performed we noticed that the tributary net system is very variable and this is the reason why it is so difficult to secure all the vessels thoroughly during the operation [10, 12]. The aim of the study therefore is to identify and systematise the types of major saphenous vein tributary draining patterns in patients with chronic vein insufficiency.

MATERIAL AND METHODS

We conducted 94 varicose vein operations by the Babcock method on patients suffering from chronic vein insufficiency. This surgical treatment was performed in "Therapy", a private clinic for peripheral vessel diseases. We operated on 52 left lower limbs and 42 right lower limbs. The patients were qualified for the operation procedure after physical examination and Doppler ultrasonography imaging. The *hiatus saphenous* and major saphenous vein ostium were exposed. We then identified the tributaries and determined the number vessels draining directly into the major saphenous vein. The number of these so-called "direct tributaries" (veins of 2 mm or more in length) became the criterion for distinguishing the types of tributary draining pattern.

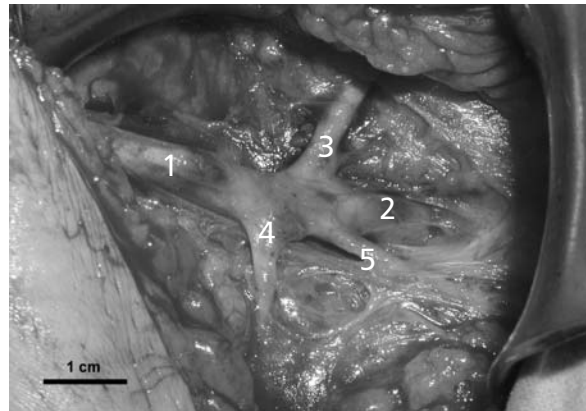


Figure 1. Intra-operative view. Right lower limb. 3 tributaries draining into the major saphenous vein (VSM) close to the sapheno-femoral junction (SFJ). Bare 1 cm. 1 — major saphenous vein (MSV), 2 — sapheno-femoral junction (SFJ), 3 — superficial circumflex iliac vein (SCIV), 4 — external pudendal vein (EPV), 5 — superficial epigastric vein (SEV).

RESULTS

We identified 5 types of major saphenous vein tributary drainage. The most common type was Type I, where there were 3 tributaries that drained directly into the major saphenous vein (Fig. 1). This type consisted of 45 cases (47.87%). We identified here 3 modifications, A, B and C. The number of tributaries that drained into the major saphenous vein together, as one trunk, became the criterion for distinguishing these 3 groups. In Modification A we found in 22 cases (23.4%) that 2 tributaries drained together into the major saphenous vein as a common trunk. In Modification B, 17 cases (18.09%), every tributary drained into the major saphenous vein separately and in Modification C, 6 cases (6.38%), there were 3 tributaries draining into the major saphenous vein as a common trunk. We were able to distinguish some variants to Modifications A and C because of the different combinations of the 3 tributaries that drained into the major saphenous vein by a common trunk, these being the superficial epigastric vein (SEV), the superficial circumflex iliac vein (SCIV) and the lateral accessory saphenous vein (LASV).

However, in 23 cases (24.46%) there were 4 direct tributaries that drained into the major saphenous vein. These specimens we classified as Type II (Fig. 2). Modifications B and C were also distinguished in this group of patients. Modification A occurred in 11 cases (11.7%). Here we noticed one common trunk that was formed by 2 tributaries which drained into the major saphenous vein. In Modification B, which occurred in 8 cases (8.51%), we found that each tributary drained separately into

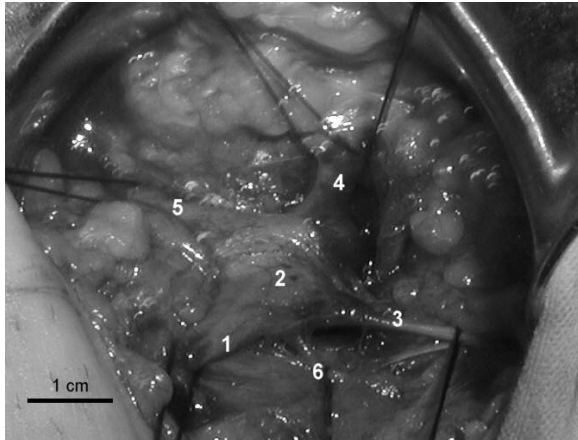


Figure 2. Intra-operative view. Right lower limb. 4 in our material direct tributaries draining into the major saphenous vein (MSV) close to the sapheno-femoral junction (SFJ). Bare 1 cm. 1 — major saphenous vein (MSV), 2 — sapheno-femoral junction (SFJ), 3 — superficial epigastric vein (SEV), 4 — superficial circumflex iliac vein (SCIV), 5 — lateral accessory saphenous vein (LASV), 6 — external pudendal vein (EPV).

the major saphenous vein. Modification C, on the other hand, was completely different. Here there were 2 main veins with similar diameters (± 1 mm), the major saphenous vein and the accessory lateral saphenous vein. These drained into the femoral vein in the *hiatus saphenous* and formed the duplex ostium of the major saphenous vein. This occurred in 4 cases (4.25%). In this type we divided Modification A into 2 anatomical variants (Fig. 3), Variant A1, where the superficial circumflex iliac vein (SCIV) and the superficial epigastric vein (SEV) formed a common trunk draining into the major saphenous vein, and Variant A2, where a similar trunk was formed by the superficial circumflex iliac vein (SCIV) and the lateral accessory saphenous vein (LASV).

Type III occurred in 14 cases (14.89%; Fig. 4). We identified here 2 direct tributaries that drained into the saphenous vein and we divided this type into 2 modifications, A and B, which were found in 10.64% and 4.25% of the specimens respectively. In Modification A (10 cases), the common trunk was formed by 2 tributaries, while in Modification B (4 cases) it was formed by 4 vessels. We distinguished 3 variants in Modification A (Fig. 3), Variant A1, where a common trunk was formed by the superficial epigastric vein (SEV) and the superficial circumflex iliac vein (SCIV), Variant A2, where the superficial circumflex iliac vein (SCIV) and the lateral accessory saphenous vein (LASV) formed a common trunk, and Variant A3, where two common trunks drained into the

saphenous vein. In Variant A3 the first common trunk was formed by the superficial epigastric vein (SEV) and the external pudendal vein (EPV) and the second by the superficial circumflex iliac vein (SCIV) and the lateral accessory saphenous vein (LASV).

Type IV occurred in 8 cases (8.51%). Here we found 5 or 6 direct tributaries, depending on the number of the external pudendal veins (EPV). Here we distinguished 2 modifications, Modification A with 5 direct tributaries and Modification B with 6 direct tributaries (double external pudendal vein; Fig. 3).

Type V turned out to be very rare, occurring in only 4 cases (4.25%). We discovered here only one direct tributary of the major saphenous vein that was formed by 2 or 3 thinner veins.

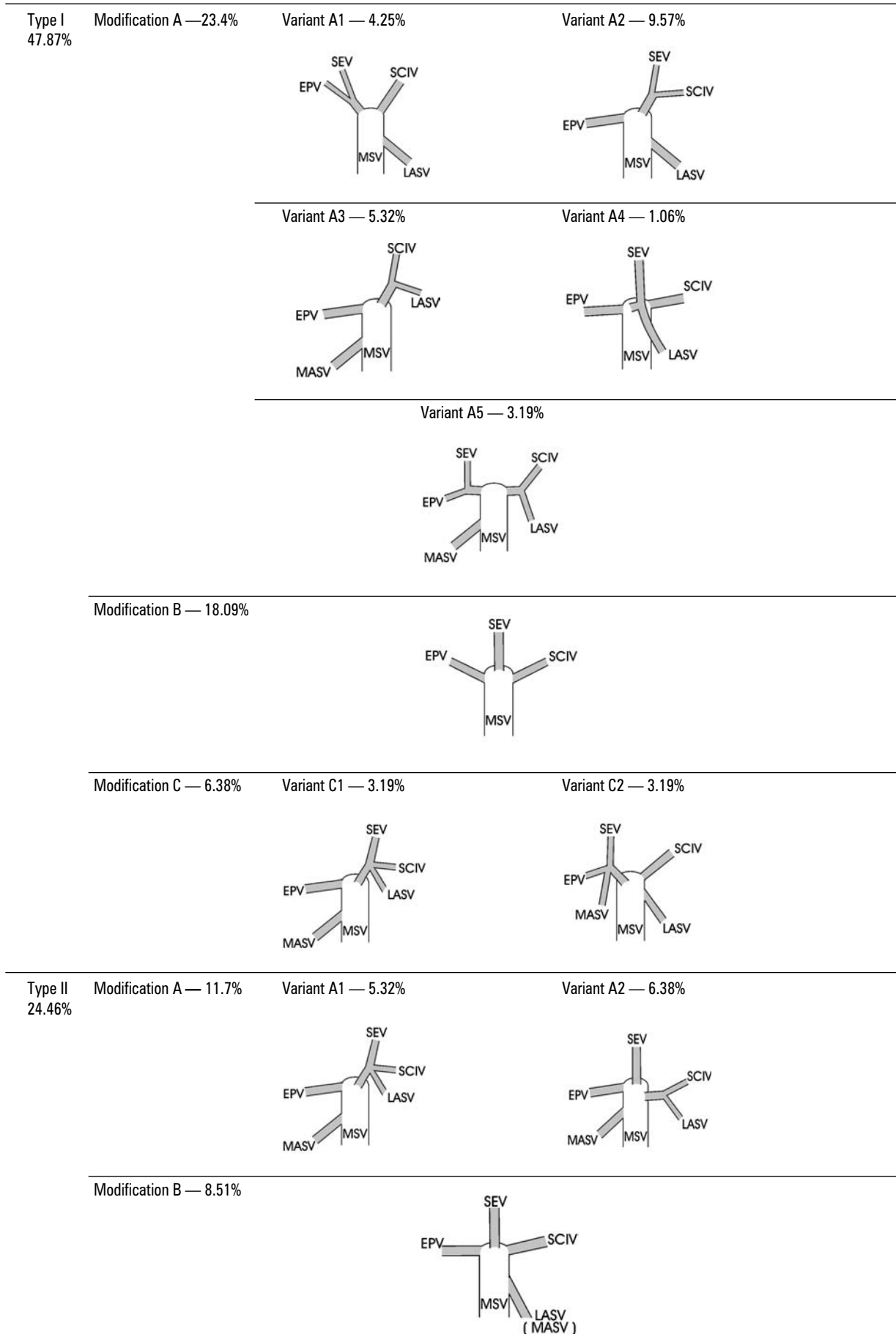
Among all the types mentioned a thin tributary 1–2 mm wide was found in 10 cases (10.63 %). This ran from under the *fascia cribrosa* into the sapheno-femoral junction in the *hiatus saphenous*.

In 6 cases (6.38%) we noticed the femoro-crural vein (Giacomini's vein), which drained into the major saphenous vein less than 5 cm from the ostium.

Of 12 operations performed bilaterally in 7 procedures the tributary net system of the major saphenous vein was the same in the left and right limbs (58.3%).

DISCUSSION

Studies on the anatomy of the sapheno-femoral junction began at the turn of the 19th century and were dominated by surgeons who stripped the major saphenous vein during surgical treatment of varicose veins. In 1916 Homans was the first to ligate all the tributaries of the major saphenous vein near the sapheno-femoral junction. This method of operation, including many different modifications, remains a main surgical procedure today [11]. Familiarity with the anatomy of this tributary network, termed by Profs. Bruska and Hilty [1, 6] the *confluens venosus subinguinalis*, is therefore very important in the radical surgery of the major saphenous vein. The *confluens venosus subinguinalis* is formed by 5 main veins. The connections between them are, however, variable according to Orsini [10], who distinguished 135 anatomical variants of draining patterns of the major saphenous vein, although without classifying them into general groups as Kocoń and Żebrowski did [7]. The types we have distinguished are quite similar to those in Kocoń and Żebrowski's study, although they contrast sharply in their frequent occurrence. In Kocoń's and Żebrowski's study Type II appeared less frequently, in 15.7%



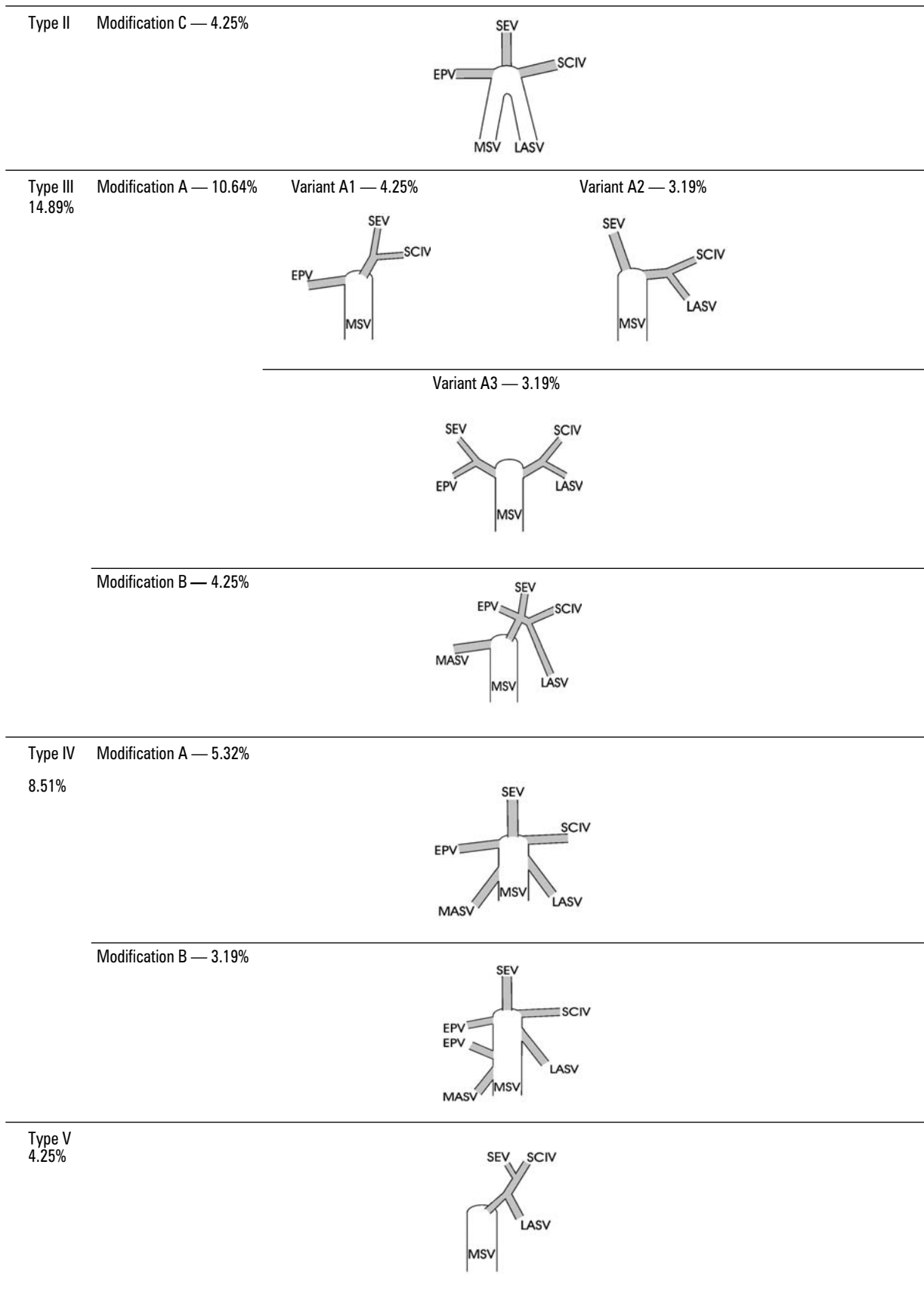


Figure 3. The schemes of the types, modifications and variants of outlet of the major saphenous vein tributaries in patients with chronic vein insufficiency of the lower limbs; MSV — major saphenous vein, SEV — superficial epigastric vein, EPV — external pudendal vein, SCIV — superficial circumflex iliac vein, MASV — medial accessory saphenous vein, LASV — lateral accessory saphenous vein.

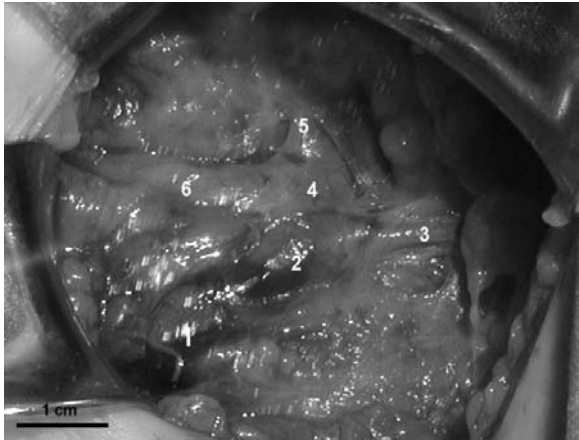


Figure 4. Intra-operative view. Right lower limb. 2 direct tributaries draining into the major saphenous vein (MSV) close to the sapheno-femoral junction (SFJ). Bare 1 cm. 1 — major saphenous vein (MSV), 2 — sapheno-femoral junction (SFJ), 3 — external pudendal vein (EPV), 4 — common trunk formed by superficial epigastric vein (SEV) and superficial circumflex iliac vein (SCIV), 5 — superficial epigastric vein (SEV), 6 — superficial circumflex iliac vein (SCIV).

of cases, while Type III occurred more frequently, in 34 % of cases, than in our material. The type with 3 direct tributaries has to be recognised as the most frequently occurring. It makes up 47.87% of all cases in our study and 47% of the cases in Kocoń and Żebrowski's study. In contrast, the type with 5 or 6 direct collaterals entering the major saphenous vein occurred in 10.63% of cases and is thus more frequent than in Kocoń's study (2% of cases), although less frequent in comparison with other publications (23–37% of cases [2, 4]).

We have found similar differences between articles regarding the presence and number of the external pudendal veins. In our study 2 external pudendal veins appeared in 4.35% of cases, while in other publications this was true in only in 1% of cases [4].

No case was observed by us where the major saphenous vein drained into the femoral vein separately without any collaterals. Nabatoff, however, found 2 such cases [9]. A duplex major saphenous vein joining at the *hiatus saphenous* appeared in 3.8% of cases in our material (the major saphenous vein and accessory lateral or medial saphenous vein with similar diameters of ± 1 mm draining together into the femoral vein), while the incidence in the literature varies from 3% to 49% of cases [3, 7, 10].

We have also noticed that there were some tributaries which emerged from under the *fascia cribrosa* and ran into the sapheno-femoral junction in the *hiatus saphenous*. These tiny vessels should be

recognised as joining the superficial veins with some deep veins of the thigh, so that we can say that they are the perforating veins of the thigh. We have found this kind of single vein in 10 cases (10.63%) in our material and this was similar to the incidence described in the literature [9, 10]. There is, therefore, a considerable likelihood of this tributary being overlooked during the operation procedure and this may lead to recurrences of the complaint.

CONCLUSIONS

1. We can identify 5 types of draining pattern of the major saphenous vein according to the number of its direct tributaries.
2. Type I, with 3 direct collaterals of the major saphenous vein, is the most frequently encountered, with an incidence of 47.8%.
3. The common trunk, which drains into the major saphenous vein, is formed by the conjunction of 2 or 3 collaterals. It is most often formed by 2 tributaries, the superficial epigastric vein (SEV) and the superficial circumflex iliac vein (SCIV).
4. There is a possibility of overlooking or ignoring a tributary during surgery, particularly when Type IV with 5 or 6 direct collaterals is involved. This type occurs relatively often, in approximately 10% of cases.
5. In about 10% of cases a tributary was found, probably a perforator vein, which came from under the *fascia cribrosa* in the *hiatus saphenous* and which may be one of the causes of the recurrences of chronic vein insufficiency.

REFERENCES

1. Bruska M, Woźniak W (1996) Connections between the great saphenous vein and cutaneous veins of the thigh in human fetuses. *Folia Morphol*, 55: 222–223.
2. Chun MH, Han SH, Chung JW, Cho SS, Ko JS, Chung IH, Chung GB, Lee MS, Kang HS, Park SS (1992) Anatomical observation on draining patterns of saphenous tributaries in Korean adults. *JKMS*, 7: 25–33.
3. Corrales NE, Irvine A, McGuinness CL, Dourado R, Burnard KG (2002) Incidence and pattern of long saphenous vein duplication and its possible implications for recurrence after varicose vein surgery. *Br J Surg*, 89: 323–326.
4. Glasser ST (1943) An anatomic study of venous variations at the fossa ovalis. *Arch Surg*, 46: 289–295.
5. Gillot C (1997) Superficial veins of the lower limbs. *Ann Chir*, 57: 713–727.
6. Hilty H (1955) Die makroskopische Gefässvariabilität in Mundungsgebiet der vena saphena magna des Menschen. *Basel*, 1955: 1–148.
7. Kocoń T, Żebrowski W (1973) Liczba i ukształtowanie dopływów końcowego odcinka żyły odpiszczelowej. *Przegl Chir*, 12: 1397–1402.

8. Lefebvre-Vilardebo M (1991) The sapheno-femoral area: anatomic study and concepts for the prevention of varicose recurrences. *J Mal Vasc*, 16: 355–358.
9. Nabatoff RA (1981) Anomalies encountered during varicose vein surgery. *Phlebologie*, 34: 21–27.
10. Orsini A, Molfetta S, Pagani C (2001) The importance of anatomical variants of the sapheno-femoral junction in lower limb varicose vein surgery. *Minerva Cardioangiol*, 49: 257–262.
11. Szyber P, Rybak Z (1993) Historia naturalna operacyjnego leczenia żylaków kończyn dolnych. *Przegl Flebol*, 1: 62–68.
12. Viani MP, Poggi RV, Pinto A, Andreani SM, Spagnoli C, Maruotti RA (1996) Re-exploration of the saphenofemoral junction in the treatment of recurrent varicose veins. *Int Surg*, 81: 382–384.
13. Wienert V (1993) Epidemiologie et socio-economie des maladies veineuses en Allemagne. *Phlebologie*, 46: 225.