

Histological and fluorescence microscopic examination of the bone/implant interface in orthodontic miniscrews (Mondeal®)

T. Gedrange, P. Proff, T. Bayerlein, P. Landsberger, S. Dietze, J. Fanghänel

Clinic for Orthodontics and Preventive and Paediatric Dentistry, University of Greifswald Dental School, Greifswald, Germany

[Received 21 December 2005; Accepted 8 February 2006]

*The temporary nature of orthodontic implants demands optimisation of size and design in order to minimise damage and risk to the patient. Slender and shorter miniscrews offer the advantage over conventional implants of easier and more ubiquitous positioning with minimised risk of injury to neighbouring anatomical structures such as tooth roots, nerves or vessels. The question is raised, however, as to what extent these advantages are gained at the price of diminished stability or a more unfavourable bone interface. In order to evaluate the screw/bone interface, 14 orthodontic miniscrews (Mondeal Medical Systems, diameter: 1.5 mm, length: 9 mm) were inserted into the right and left mandibles of 7 pigs (*Sus scrofa domestica*). Bone fluorochromes were administered in a defined order for polychrome sequencing. The samples gathered after 70 days were analysed using histological techniques and fluorescence microscopy. The lower part of the self-tapping thread displayed undisturbed bone apposition. Fluorescence microscopy revealed remodelling and bone apposition within the thread grooves.*

Key words: orthodontic miniscrews, bone apposition, remodelling

INTRODUCTION

One of the most frequent tasks in orthodontic practice routine is distalisation of teeth carried out for the treatment of space imbalance, (a discrepancy between the available and the required space), as well as for establishing a neutral occlusion.

A variety of intraoral and extraoral appliances is available for molar distalisation. A disadvantage of the extraoral devices is, apart from the poor aesthetics, their dependence on patient compliance. Inserting an implant or a miniscrew offers the chance for compliance-independent maximum anchorage [5, 8]. The clinical requirements for miniscrews for orthodontic anchorage are different from those for prosthetic implants owing to their temporary nature. The smaller size of miniscrews prevents larger bone defects and

enables rapid healing after removal. Screw-shaped titanium implants have proved successful as orthodontic anchorage [7]. Normally these are loaded with forces of 1 to 3 N. In the event of a mispositioning, however, short-term peak loads amounting to 200 N may arise from transmitted chewing forces, which are blamed for premature loss. On the other hand, inflammatory changes of the implant site, ultimately inducing peri-implantitis, may lead to untimely loss.

A primarily undisturbed bone adaptation to the implant is also of great importance in orthodontics. This may be influenced by the implant material as well as by the implant shape and surface.

This study aimed to examine the quality of the miniscrew (Mondeal®)/bone interface and the bone remodelling process.

MATERIAL AND METHODS

In this study one orthodontic miniscrew (Mondeal[®], System LOMAS, 1.5 × 9 mm) was inserted respectively into the right and left mandibles of 7 pigs (*Sus scrofa domestica*) according to a uniform protocol. Implantation was conducted under analgesedation and additional local anaesthesia. The screws were fixed in the right and left mandibles between the canines and premolars. Intravenous application of bone fluorochromes was performed for polychrome sequence labelling after a fixed protocol: first week — calcein (5 mg/kg; light green), third week — xylenol (60 mg/kg; orange), tenth week — alizarin (20 mg/kg; red).

After 70 days the implant/bone complex was removed en bloc and thin sections were prepared for histological analysis.

RESULTS

Two out of 14 miniscrews were lost prematurely. In total, thin sections of 12 resectates were prepared for histological and fluorescence microscopic examination. All specimens displayed undisturbed bone adaptation in the medium and lower third (Fig. 1). Neither resorption lacunae nor gaps were detected at the bone/implant interface. Fluorescence micros-

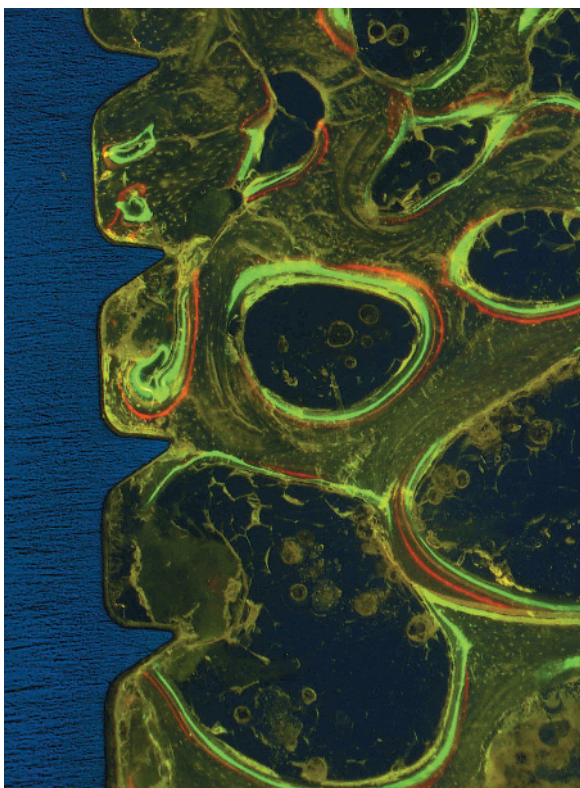


Figure 1. Fluorescence microscopic image of the lower third of a miniscrew with clearly visible bone apposition up to the thread grooves.

copy revealed bone apposition within the thread grooves in the first week in particular but also in the tenth week after implantation.

DISCUSSION

Any orthodontic treatment implies the application of forces which require corresponding counteracting forces according to Newton's third axiom. Structures that resist these counteracting forces are referred to as anchorage. If the natural teeth are insufficient for anchorage or side-effects to the anchorage units are undesired, the use of miniscrews may be helpful. The normally undisturbed bone adaptation to miniscrews assures good resilience. Osseous integration of dental implants was studied by Brånemark et al. and ideally characterised by direct bone apposition to the implant [1]. Schroeder et al. [3, 4] termed this state "functional ankylosis". The healing process of titanium implants starts with the apposition of proteins from the blood or the extracellular matrix. Neutrophil granulocytes, monocytes and macrophages interact with them. Finally, messengers induce activation of fibroblasts which isolate the foreign body. Later apposition of bone progenitor cells and differentiation to osteoblasts occurs, initiating bone mineralisation. Healing is mostly accomplished by contact osteogenesis, close to the mineralised tissue yet surrounded by a connective tissue cover, and infrequently by bonding osteogenesis with direct connection to the bone [2, 6].

REFERENCES

1. Brånemark PI, Adell R, Breine U, Hansson BO, Lindstrom J, Ohlsson A (1969) Intra-osseous anchorage of dental prostheses. I. Experimental studies. *Scand J Plast Reconstr Surg*, 3: 81–100.
2. Davies JE (1998) Mechanisms of endosseous integration. *Int J Prosthodont*, 11: 391–401.
3. Schroeder A, Pohler O, Sutter F (1976) Tissue reaction to an implant of a titanium hollow cylinder with a titanium surface spray layer. *SSO Schweiz Monatsschr Zahnheilkd*, 86: 713–727.
4. Schroeder A, Van Der Zypen E, Stich H, Sutter F (1981) The reactions of bone, connective tissue, and epithelium to endosteal implants with titanium-sprayed surfaces. *J Maxillofac Surg*, 9: 15–25.
5. Schweizer CM, Schlegel KA, Rudzki-Janson I (1996) Endosseous dental implants in orthodontic therapy. *Int Dent J*, 46: 61.
6. Steflik DE, Meenaghan M (1998) Introduction: surface and coating variability on implanted biomaterials. *Implant Dent*, 7: 301–302.
7. Wehrbein H, Yildirim M, Diedrich P (1999) Osteodynamics around orthodontically loaded short maxillary implants. An experimental pilot study. *J Orofac Orthop*, 60: 409.
8. Wehrbein H (1994) Enossale Titanimplantate als orthodontische Verankerungselemente. *Fortschr Kieferorthop*, 55: 236.