

The relationship of the parotid duct to the buccal and zygomatic branches of the facial nerve; an anatomical study with parameters of clinical interest

K.M. Erbil¹, A. Uz², M. Hayran³, N. Mas⁴, S. Senan³, M. Tuncel¹

¹Department of Anatomy, Faculty of Medicine, Hacettepe University, Ankara, Turkey

²Department of Anatomy, School of Medicine, Ankara University, Ankara, Turkey

³Department of Preventive Oncology, Institute of Oncology, Faculty of Medicine, Hacettepe University, Ankara, Turkey

⁴Department of Anatomy, Faculty of Medicine, Baskent University, Ankara, Turkey

[Received 25 August 2006; Revised 28 March 2007; Accepted 28 March 2007]

There have been studies concerning the protection of the facial nerve during plastic surgery intended for the parotid gland. The close relationship between the parotid duct and the buccal and zygomatic branches of the facial nerve is studied here. The dissections were performed on 10 fixed cadavers at the Anatomy Dissection Laboratory of Ankara University in 2004. The reference points used for surgery of this region were taken into consideration as the landmarks for morphometric measurements. In 7 of the cases the zygomatic branch was double and in 3 it was single. In 4 of the 7 cases with a double zygomatic branch both superior and inferior branches crossed the parotid duct. In the remaining 3 cases the superior branches of the zygomatic nerve coursed through the zygomatic major and minor muscles. In 9 of all the cases the zygomatic branch of the facial nerve crossed the duct anteriorly and in one it did so posteriorly (case 10). The buccal branch was single in 4 of the cases and double in 6. Among these one of the most precise measurements was the distance between the lateral canthus and the intersection point of the zygomatic branch and the duct with a coefficient of variation of 9.9%. With the use of this reliable measurement the intersection point of the zygomatic branch and the duct may be estimated to be within 5.16 ± 1.01 centimetres of the lateral canthus. Facial nerve paralysis is the most important complication of superficial face surgery and the anatomy of this region must thus be taken into detailed consideration by surgeons.

Key words: parotid duct, facial nerve, zygomatic branch, buccal branch, anatomy

INTRODUCTION

The position of the buccal and zygomatic branches of the facial nerve is critical in performing surgical procedures. There are number of studies concerning protection of the facial nerve during plastic surgery procedures and operations intended for the parotid gland,

but no consistent description of them has been given so far. The risk for facial nerve injury is reported to have been increased with the inclusion of the superficial musculoaponeurotic system (SMAS) elevation as compared to a skin-only face-lift [16]. Closely related to vital structures of the face such as the terminal branches of the

facial nerve, the transverse facial artery and parotid duct constitute very important landmarks when treating injuries to this region [14]. Anatomical textbooks and journal articles vary greatly in demonstrating their relationship with the temporal branch, but not only are references to the peripheral facial nerve branches near the buccal fat pad and the oral commissure scarce, but no comments are provided about anatomical variations. The position of the buccal branch is critical in performing procedures such as rhytidectomy. However, there is less information in the literature about the relation between the parotid duct, which is one of the most important structures on the face, and these branches of the facial nerve. The close relationship between the parotid duct and buccal and zygomatic branches of the facial nerve has therefore been studied. The proposed localisation landmarks are thought to allow fast and safe identification of the facial nerve, significant during surgery in the parotid region. This study examined the usefulness of anatomical lines in predicting the extraparotid course of the buccal and zygomatic branches of the facial nerve around the parotid duct.

MATERIAL AND METHODS

The dissections were performed on 10 fixed cadaver heads at the Anatomy Dissection Laboratory of Ankara University in 2004. The skin, subcutaneous tissue, platysma and the subcutaneous musculoaponeurotic system were dissected, leaving the branches of the facial nerve and parotid duct exposed. The buccal and zygomatic branches were dissected from the point of exposure from the parotid gland until they entered the superficial face muscles. The parotid duct was dissected from its point of exposure at the anterior border of the parotid gland until it turned around the anterior border of the masseter muscle to enter the oral cavity through the buccinator muscle. The reference points in this region were taken according to surgical usage (Fig. 1).

The morphometric measurements were performed between these landmarks, the parotid duct and the buccal and zygomatic branches of the facial nerve, as shown below:

- the length of the duct (A–C);
- the dimension of the duct (PDIM);
- the distance between the preface of the parotid duct and the intersection point of the zygomatic nerve and the duct (A–B);

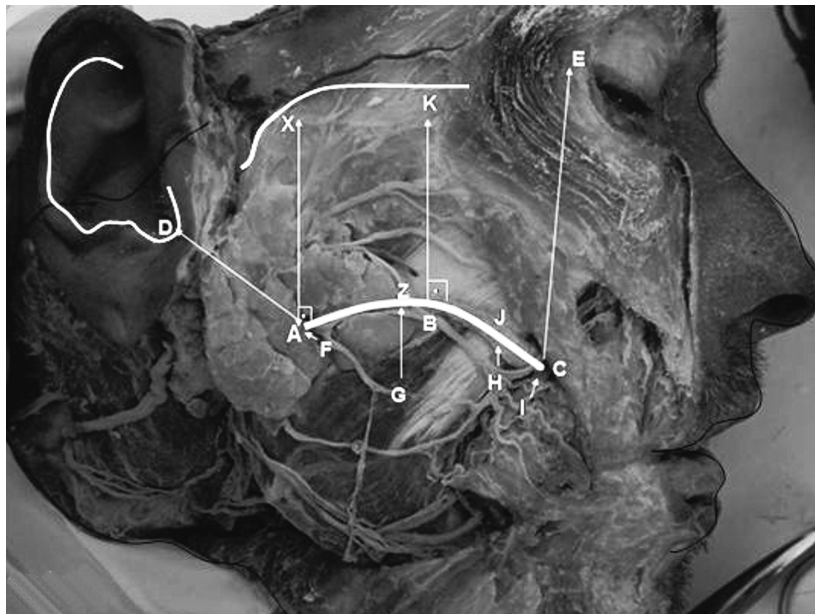


Figure 1. Cadaveric view of the landmarks on the parotid duct, zygomatic and buccal branches. A — beginning of the parotid duct; B — point on the duct where the zygomatic branch crossed; C — end of the parotid duct; D — intertragic notch; E — lateral canthus; F — beginning of the buccal nerve; G — mid point of the buccal nerve; H — point where the buccal and zygomatic branches arched; I — end of the buccal nerve; J — point where the H intersects the duct with 90°; K — point where the B intersects the zygomatic arch with 90°; Z — point where the G intersects the duct with 90°; X — point where the A intersects the zygomatic arch with 90°.

- the distance between the beginning of the duct and the intertragic notch (A–D);
- the distance between the end of the duct and the lateral cantus (C–E);
- the distance between the beginning of the duct and the zygomatic arch (A–X);
- the distance between the arch formed by the buccal and zygomatic nerves and the duct (H–J);
- the distance between the buccal branch and the duct at three different points (the beginning, middle and final parts of the duct) measured (F–A, G–Z, I–C);
- the distance between the lateral canthus and the intersection point of the zygomatic nerve and the duct (E–B);
- the distance between the zygomatic arch and the intersection point of the zygomatic nerve and the duct (B–K) (Fig. 1).

All the measurements were evaluated statistically. For each measurement between landmarks the measures of central tendency and dispersion are provided in terms of mean and standard deviation. The analyses focused on finding reliable measurements with small coefficients of variation (CV). CVs were calculated for each measurement as the standard deviation divided by its mean. As the CV value gets smaller, the measurement between landmarks is interpreted as being more reliable. The upper and lower limits of a 95% confidence interval for a measurement are found by adding and subtracting 1.96 times the standard deviation to and from its mean.

RESULTS

In cadaver dissections in 7 of cases the zygomatic branch was double and in 3 it was single. In 4 of the 7 cases with a double zygomatic branch both superior and inferior branches crossed the parotid duct (case 3, 7, 8 and 9) and so distances E–B and B–K were measured twice in these 4 cases. In the remaining 3 cases the superior branches of the zygomatic nerve coursed through the zygomatic major and minor muscles. In 9 of all the cases the zygomatic branch crossed the duct anteriorly and in one posteriorly (case 10).

The buccal branch was single in 4 of the cases and double in 6 of the cases. In all of the double cases the superior branches added to the anastomosis with the zygomatic branches and the inferior branches coursed through the orbicularis oris muscle. Therefore all the measurements of the buccal nerve were performed on the superior branch. The buccal branch coursed in contact with the inferior margin of the parotid duct

at cases 7 and 9, and so distances H–J, F–A, G–Z and I–C were not measured in these cases.

The zygomatic and buccal branches united to form an anastomosis (arch) around the area where the duct pierced the buccinator muscle. The accessory parotid gland was seen only in case 4. The distance between the beginning of the duct and the accessory gland was measured as 15.65 mm and this accessory gland was crossed by a branch of the buccal nerve. The length of the parotid duct was 21.90–37.36 mm and the diameter was 3.41–6.57 mm. The distance between the preface of the parotid duct and the intersection point of the zygomatic nerve and the duct (A–B) was 3.53–23.26 mm. The distance between the beginning of the duct and the intertragic notch (A–D) was 23.33–44.12 mm. The distance between the end of the duct and the lateral cantus (C–E) was 40.29–56.40 mm. The distance between the beginning of the duct and the zygomatic arch (A–X) was 13.57–27.63 mm. The distance between the arch formed by the buccal, zygomatic nerves and the duct (H–J) was 1.66–5.18 mm. The distance between the buccal branch and the duct at three different points (the beginning, middle and final parts of the duct) (F–A, G–Z, I–C) was 0.96–5.91 mm, 1.56–6.61 mm and 1.40–5.33 mm respectively. The distance between the lateral canthus and the intersection point of the zygomatic branch and the duct (E–B) was 41.00–61.41 mm and the distance between the zygomatic arch and the intersection point of the zygomatic branch and the duct (B–K) was 13.16–46.40 mm (Table 1).

Among these one of the most precise measurements was the distance between the lateral canthus and the intersection point of the zygomatic branch and the duct with a coefficient of variation of 9.9%. With the use of this reliable measurement the intersection point of the zygomatic branch and the duct may be estimated as being within 5.16 ± 1.01 centimetres of the lateral canthus. This will mean that the intersection points (points a and b) of two circles with the duct drawn with radii of 4.15 and 6.17 centimetres will mark a segment along the path of the duct, which with 95% confidence will include the intersection point with the zygomatic branch (Fig. 2).

DISCUSSION

Reconstructive surgery by free muscle transplantation in irreversible facial palsy and other operations in this region have evoked interest in the detailed anatomy of the mimic muscle system parotid gland and duct and the branches of the facial nerve.

Table 1. Presentation of the measurements between the landmarks

	A-C	PDIM	A-B	A-D	C-E	A-X	H-J	F-A	G-Z	I-C	E-B	B-K
1	29.80	4.42	20.95	42.29	50.43	23.17	1.66	4.12	5.03	4.32	54.31	18.94
2	32.60	4.32	17.02	41.48	56.40	27.63	4.79	5.11	4.18	4.20	50.12	13.16
3	21.90	4.27	15.23	44.12	48.22	23.9	1.66	3.24	4.02	4.31	1: 50.71 2: 48.23	1: 24.63 2: 22.75
4	36.82	4.90	23.26	26.48	52.16	24.70	5.18	4.30	6.61	5.33	41.00	23.61
5	37.36	4.68	17.41	23.33	45.18	19.20	3.54	5.83	4.72	3.60	61.41	23.75
6	35.83	5.81	15.18	26.42	46.71	20.63	1.74	0.96	3.38	4.68	53.64	21.03
7	30.62	3.41	18.01	38.56	53.14	25.32	–	–	–	–	1: 46.83 2: 52.80	1: 24.44 2: 26.63
8	32.65	4.18	3.53	27.90	48.11	24.60	4.06	5.91	6.52	4.90	1: 49.65 2: 53.24	1: 28.06 2: 46.40
9	36.45	6.57	14.10	31.15	40.29	19.62	–	–	–	–	1: 57.09 2: 50.18	1: 25.84 2: 25.09
10	29.66	4.51	12.86	25.27	44.45	13.57	3.75	1.10	1.56	1.40	51.32	24.78
Mean	32.4	4.7	15.8	32.7	48.5	22.2	2.6	3.1	3.6	3.3	51.6	23.7
SD	4.5	0.9	5.3	8.0	4.7	4.1	1.9	2.3	2.4	2.0	5.1	6.1
CV	13.8%	18.9%	33.7%	24.6%	9.7%	18.2%	71.3%	76.8%	66.4%	61.9%	9.9%	25.6%

PDIM — parotis duct dimension, SD — standard deviation, CV — coefficient of variation

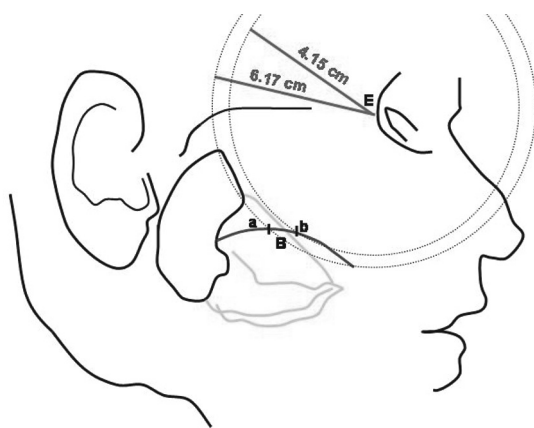


Figure 2. Schematic view of the intersection points (points a and b) of two circles with the duct drawn with radii of 4.15 and 6.17 cm which mark a segment along the path of the duct, which with 95% confidence will include the intersection point with the zygomatic branch; B — point on the duct where the zygomatic branch crossed; E — lateral canthus; a and b — the intersection points of two circles with the duct.

Injuries to the buccal region of the face can carry multiple complications because of the complex anatomy that lies within. The facial nerve and the parotid

duct can easily be injured by sharp or penetrating trauma to the cheek. Knowledge of the anatomy of the parotid duct and its relationship to other structures, such as the terminal branches of the facial nerve, are essential when treating these injuries [14]. The normal anatomy of the facial nerve has been well described in the textbooks [6, 17]. There are a number of studies concerning the protection of the facial nerve during plastic surgery procedures and operations intended for the parotid gland but no consistent description of them has been given so far [1, 5, 8, 9, 13]. Although the literature includes a large amount of research which describes the parotid gland as a whole, little attention is given to the parotid duct [12].

In 2003 Wilhelmi et al. [16] mentioned the importance of the anterior edge of the parotid gland in elevating the superficial musculoaponeurotic system. They identified and measured the most anterior portion of the parotid gland and reported that anterior to the parotid gland the buccal branches become more fragile and are more susceptible to injury. For this reason the surgeon must be aware of the beginning of the buccal branch from the anterior edge of the parotid gland. The distance between

the beginning of the buccal branch and the parotid duct (F–A) was measured in the present study and found to be 0.96–5.91 mm [16].

Pereira et al. [10] and de Ru et al. [3, 4] mentioned that many surgical landmarks may help the surgeon identify the facial nerve when performing parotid gland surgery and that external palpable landmarks may be used to identify the facial nerve trunk quickly and safely. Pereira et al. [10] performed a 3 cm skin incision in the centre of the triangle formed by the temporomandibular joint, the mastoid process and the angle of the mandible, and dissection was continued deep until the main facial nerve trunk was identified. Nahl-ieli et al. [9] identified the main trunk of the facial nerve as it leaves in the stylomastoid foramen according to the anatomical landmarks as a mastoid process, insertion of the sternocleidomastoid muscle, and pointer cartilage of the ear. Kopuz et al. [7] studied the distribution of the facial nerve in the parotid gland; the cases in the present study were similar to types IIIB and IVA. Amin et al. [1] mentioned the importance of the protection of the branches of the facial nerve during parotidectomy of the parotid sialadenitis. Pogrel et al. [11] studied the relationship of the buccal branch of the facial nerve to the parotid duct and its relevance to surgical procedures in this area but made no mention of the zygomatic branch. They reported that in 17 of the 20 cases there was a single buccal branch of the facial nerve but that in 3 of the cases two buccal branches of the facial nerve were present. The buccal branch was single in 4 of the cases and double in 6 in the present study. One of the double branches was superficial and the other was deep, as given in textbooks. In all of the double cases the superior branches added to the anastomosis with the zygomatic branches and the inferior branches coursed through the orbicularis oris muscle. The buccal branch was close and parallel to the inferior margin of the parotid duct in two of the cases, although Pogrel et al. did not mention a buccal branch as is emphasised in the present study. The buccal branch did not cross the duct as these authors reported. They emphasised that in 15 of the cases the buccal branch was inferior to the duct but in the present study all the buccal branches were inferior to the duct. They also stressed the average vertical distance between the buccal branch and the duct as being 5.43 ± 3.65 mm when the branch was inferior to the duct. In the present study it was con-

sidered of greater validity to measure the distance between the beginning, middle and end of the buccal branch to the duct. Thus the distance of the buccal branch to the duct at three different points (the beginning, middle and final parts of the duct) (F–A, G–Z, I–C) was found to be 0.96–5.91 mm, 1.56–6.61 mm and 1.40–5.33 mm respectively. They authors referred to found the exposed mean distance of the duct to be 26.7 ± 8.34 mm. In the present study the average length of the duct (A–C) was found to be 21.90–37.36 mm [11].

Bernstein and Nelson [2] examined the types of facial nerve branching according to the study of the Davis et al., and most of our cases were as type III. Richards et al. [12] studied the surgical anatomy of the parotid duct and the relationship of the facial nerve to the duct. They mentioned that the facial nerve and its branches were always observed lateral to the parotid duct and that the facial nerve formed a loop superficial to the duct. However, they did not give any measurements for these structures.

Tohma et al. [15] reported the communication between the buccal nerve and the facial nerve in the human face. They stressed that the lower zygomatic and upper buccal branches joined inferiorly to the parotid duct (Z–B junction) and that multiple sub-branches emerged from the Z–B junction and spread throughout the buccal region. These findings are similar to our results.

The facial nerve has complex branches and patterning, as mentioned in the textbooks. There is obvious variability between patients and cases. The buccal and zygomatic branches and the parotid duct are especially vulnerable to surgical and traumatic injuries because of their location in the face. As they course so close to each other, if one of them is damaged the other structure should be influenced. As a result, facial nerve paralysis is the most important complication of superficial face surgery. Thus the anatomy of this region and the facial nerve must be taken into detailed consideration by surgeons. In this the distance between the lateral canthus and the intersection point of the zygomatic branch and the duct is the most precise measurement of the study. It is significant for the surgeon that the intersection points (points a and b) of two circles, with the duct drawn with radii of 4.15 and 6.17 centimetres, will mark a segment along the path of the duct, which with 95% confidence will include the intersection point with the zygomatic branch.

REFERENCES

1. Amin MA, Bailey BM, Patel SR (2001) Clinical and radiological evidence to support superficial parotidectomy as the treatment of choice for chronic parotid sialadenitis: a retrospective study. *Br J Oral Maxillofac Surg*, 39: 348–352.
2. Bernstein L, Nelson RH (1984) Surgical anatomy of the extraorotid distribution of the facial nerve. *Arch Otolaryngol*, 10: 177–183.
3. de Ru JA, Ronald LA, Bleys W, Paul P, Benthem G, Hordijk GJ (2001) Preoperative determination of the location of parotid gland tumors by analysis of the position of the facial nerve. *J Oral Maxillofac Surg*, 59: 525–528.
4. de Ru JA, Benthem PP, Bleys RL, Lubsen H, Hordijk GJ (2001) Landmarks for parotid gland surgery. *J Laryngol Otol*, 115: 122–125.
5. Freilinger G, Gruber H, Happak W, Pechmann U (1987) Surgical anatomy of the mimic muscle system and the facial nerve: importance for reconstructive and aesthetic surgery. *Plast Reconstr Surg*, 80: 686–690.
6. Hollinshead WH (1968) *Anatomy for surgeons: The head and neck*. Vol 1. 2nd ed. Harper & Row, USA, pp. 347–364.
7. Kopuz C, Turgut S, Yavuz S, Ilgi S (1994) Distribution of facial nerve in parotid gland: Analysis of 50 cases. *Okajimas Folia Anat Jpn*, 70: 295–300.
8. Mazzocconi G, Mantella F, Fabrizio G, Stasio A, Bucchianeri R, Zechini F (2002) Study of the facial nerve in parotid surgery. *G Chir*, 23: 279–284.
9. Nahlieli O, Levy Y (2001) Intravital staining with methylene blue as an aid to facial nerve identification in parotid gland surgery. *J Oral Maxillofac Surg*, 59: 355–356.
10. Pereira JA, Meri A, Potau JM, Prats-Galino A, Sancho JJ, Sitges-Serra A (2004) A simple method for safe identification of the facial nerve using palpable landmarks. *Arch Surg*, 139: 745–747.
11. Pogrel MA, Schmidt B, Ammar A (1996) The relationship of the buccal branch of the facial nerve to the parotid duct. *J Oral Maxillofac Surg*, 54: 71–73.
12. Richards AT, Digges N, Norton NS, Quinn TH, Say P, Galer C, Lydiatt K (2004) Surgical anatomy of the parotid duct with emphasis on the major tributaries forming the duct and the relationship of the facial nerve to the duct. *Clin Anat*, 17: 463–467.
13. Schwember G, Rodriguez A (1988) Anatomic surgical dissection of the extraparotid portion of the facial nerve. *Plastic Reconstr Surg*, 183–188.
14. Steinberg M J, Herrera AF (2005) Management of parotid duct injuries. *Oral Maxillofacial Surg*, 99: 136–141.
15. Tohma A, Mine K, Tamatsu Y, Shimada K (2004) Communication between the buccal nerve (V) and facial nerve (VII) in the human face. *Ann Anat*, 186: 173–178.
16. Wilhelmi BJ, Mowlavi A, Neumeister MW, (2003) The safe face lift with bony anatomic landmarks to elevate the SMAS. *Plast Reconstruct Surg*, 15: 111: 1723–1726.
17. Williams PL, Bannister LH, Berry MM et al. (1995) *Gray's anatomy*, 38th ed. Churchill Livingstone, London, pp. 1107–1111.