

An unusual muscular variation of the infratemporal fossa

R.S. Tubbs^{1, 6}, W. Stetler², M.M. Shoja³, M. Loukas^{4, 5}, E.G. Salter¹, W.J. Oakes⁶

¹Department of Cell Biology, University of Alabama at Birmingham, USA

²School of Medicine, University of Alabama at Birmingham, USA

³Tuberculosis and Lung Disease Institute, Tabriz University, Tabriz, Iran

⁴Department of Anatomical Sciences, St. George's University, Grenada, West Indies

⁵Department of Education and Development, Harvard Medical School, Boston, Massachusetts, USA

⁶Section of Pediatric Neurosurgery, University of Alabama at Birmingham, USA

[Received 16 February 2007; Revised 19 June 2007; Accepted 19 June 2007]

The infratemporal fossa is often the site of pathology or surgical intervention. We describe an unusual muscle found during the routine dissection of the right infratemporal fossa. The literature germane to this variable muscle, best described as a variant of the pterygoideus proprius, is reviewed. The clinician may contemplate the wide array of muscular anomalies within the infratemporal fossa when considering unexplained neurological symptoms attributed to branches of V3 and pursue appropriate diagnostic testing.

Key words: anatomy, head, V3

INTRODUCTION

The infratemporal fossa is of great interest to clinicians and houses important structures such as the mandibular nerve and the maxillary artery. This region also contains several of the muscles of mastication derived from a common embryologic source [2]. The temporalis, lateral and medial pterygoids, and the masseter are all derived from a common muscular sheet from the first pharyngeal arch, and are all associated with the temporomandibular disc during embryologic development [5]. Owing to their common lineage and rearrangement during development [5], many smaller muscles and tendons have been described within the infratemporal fossa, representing developmental anomalies and possibly clues to the phylogeny of this region.

The pterygoideus proprius was first described by Henle in 1858 [4]. This structure has been described as originating from the anterior infratemporal crest, running vertically down to insert on the lateral pterygoid plate and crossing superficially to the lateral pterygoid muscle. Henle also described a distinctive

band of fibers he termed the "temporalis minor" that arose from the anterior aspect of the (greater) temporalis muscle and inserted onto the mandibular notch instead of the coronoid process [2]. Similarly, Akita et al. [1] noted the presence of an aberrant band of muscle arising from the anteromedial aspect of the temporalis and interdigitating with fibers from the lateral pterygoid. Such fibromuscular bands are often given a nomenclatural description within the greater context of the pterygoideus proprius name. In this report, we describe a similar muscular finding and note its relationship to the surrounding clinically relevant structures. Some have held the view that such variations may result in entrapment or compression of the mandibular nerve with resultant trigeminal neuralgia [6].

CASE REPORT

We report an unusual muscular variation within the right infratemporal fossa found, upon deep dissection, in a 73-year-old male cadaver during an anatomy course at the University of Alabama at

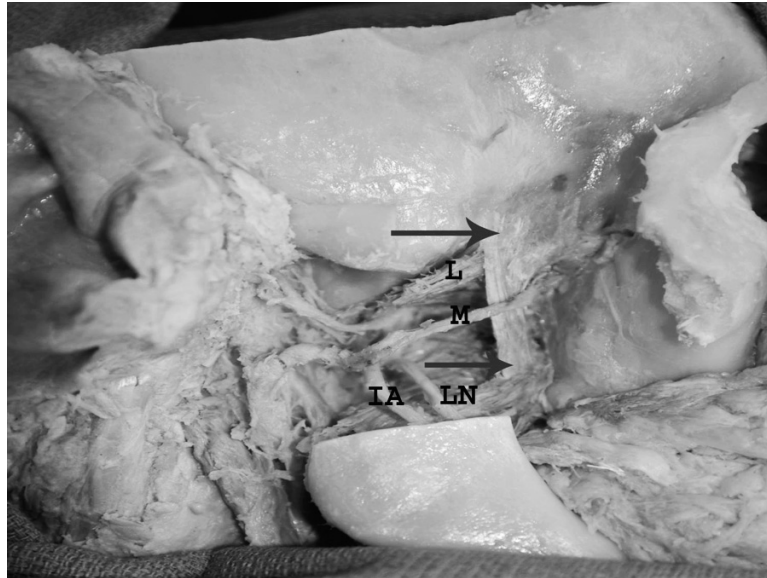


Figure 1. Cadaveric view of the right variant of the pterygoid proprius muscle (arrows). Note the distal maxillary artery (M) crossing distally to this muscle. For reference, the lateral pterygoid (L), inferior alveolar nerve (IA) and lingual nerve (LN) are shown.

Birmingham. The dissection revealed the presence of a pterygoideus proprius-like muscle originating from the anterior aspect of the infratemporal crest (superficial to the fibers of the lateral pterygoid muscle) of the greater wing of the sphenoid bone toward the inferior orbital fissure, running inferiorly to insert onto the pyramidal process of the palatine bone and fusing with fibers of the inferior part of the medial pterygoid muscle (Fig. 1). This structure was partially tendinous and partially muscular. The dimensions of this muscle were approximately 3.5×1.5 cm. No nerve innervation to this muscle was identified. The contralateral side of this cadaver had no such anomalous muscle.

This aberrant muscle was mostly consistent with the original description that Henle gave of the pterygoideus proprius. However, this structure seems also to have fibers that mesh with the lateral pterygoid near its origin, as well as the medial pterygoid muscle near the latter's insertion onto the ramus of the mandible. Also of note and differing from the classical description is a partial insertion onto the infratemporal surface of the maxilla near the angle of the lateral pterygoid plate, thereby providing a connection between the two structures. Such a description most closely relates this structure to the pterygospinous structure described by Bergman et al. [2].

This variant muscle ran deep to the maxillary artery (Fig. 1). The lingual and inferior alveolar nerves coursed superficially to the connecting meshwork of the pterygoideus proprius-like muscle and the

medial pterygoid and posterolaterally to the vertical, fibromuscular part of this muscle.

DISCUSSION

Knowledge of the contents of the infratemporal fossa is of importance for any surgical procedure in the area, such as repair of the maxillary artery, as well as for greater understanding of the embryologic development of the first pharyngeal arch. Study of the pterygoideus proprius can help shed light on both these issues.

The infratemporal muscles of mastication differentiate from common muscular anlagen [1, 2, 5]. Penhall et al. [5] offer two hypotheses for the differentiation of the pterygoideus proprius from the infratemporal embryological musculature. The first hypothesis suggests that the pterygoideus originates from the temporalis muscle early in development before the coronoid process of the mandible is fully developed for the insertion of the masseter and temporalis muscles. Thus, without a proper location to insert, some of the temporalis fibers may attach to the lateral pterygoid plate, thereby excluding them from their host muscle. A second hypothesis is that this muscle derived from the lateral pterygoid and that during its differentiation some of its fibers failed to insert onto the developing temporomandibular disc, which develops independently and later than this muscle. These fibers could then fall inferiorly and elongate to insert onto the lateral pterygoid plate.

Akita et al. [1] have suggested that the embryologic precursors to the muscles of mastication may be divided into a medial group, consisting of the medial pterygoid, and a lateral group, consisting of all the other muscles of mastication. The aberrant muscle we describe gives further evidence of a common embryologic origin with differentiation upon development to give separate muscles because the structure described links the two separated groups as described by Akita et al. [1], implying a single origin. This finding connecting the two developmental groups is consistent with the muscle described by Akita et al. [1] as connecting the temporalis with the lateral pterygoid, which was noted as possibly representing an intermediary vestige.

The functionality of the pterygoideus proprius-like muscle as described herein is purely speculative, but it has been proposed that the pterygoideus proprius muscle has a role in thermoregulation [5]. When contracted, this muscle could feasibly help propel blood from the pterygoid venous plexus, which is in part between the lateral pterygoid muscle and the pterygoideus, to the cavernous sinus via the small connecting vessel that courses through the foramen ovale. This action would possibly surround the internal carotid artery carrying warm arterial blood to the brain parenchyma with fresh, cooler venous blood from the nasal mucosa and face, thereby decreasing the temperature of the blood in the carotid as heat moves down the temperature gradient [3]. The purpose of the unusual pterygoideus we describe could help with the action of mastication or at least aid in stabilizing the mandible for mastication as a result of its connections to the medial and lateral pterygoids; however, this too is only speculation. Akita et al. [1] noted direct innervation by the anterior deep temporal nerve (V3) of their reported aberrant muscle, providing additional evidence of the functionality of the pterygoideus with contraction. We did not observe any nerve entering the muscle described in the present report.

Perhaps more important than contraction is the ability of a predominantly fibrous structure to ossify with age and impinge upon nearby structures. Bergman et al. [2] report that a fibrous band, termed the "pterygospinous ligament", with connections between the medial and lateral pterygoid muscles, has potential for ossification. Similarly, a predominantly fibrous pterygoideus-like muscle could potentially ossify and impinge on branches of V3 coursing nearby. The aberrant muscle described in this report could potentially impinge upon either the lingual or inferior alveolar branches or possibly even act as a point of compression for the maxillary artery or its nearby branches. This muscle additionally brought the maxillary artery to a more superficial position, which could predispose this vessel to iatrogenic injury. The clinician may contemplate the wide array of muscular anomalies within the infratemporal fossa when considering unexplained neurological symptoms attributed to branches of V3 and may then pursue appropriate diagnostic testing [6].

REFERENCES

1. Akita K, Shimokawa T, Sato T (2001) Aberrant muscle between the temporalis and the lateral pterygoid muscles: *M. pterygoideus proprius* (Henle). *Clin Anat*, 14: 288–291.
2. Bergman RA, Afifi AK, Miyauchi R (1984) *Catalog of human variation*. Urban & Schwarzenberg, Baltimore.
3. Dean MC (1988) Another look at the nose and the functional significance of the face and nasal mucous membrane for cooling the brain in fossil hominids. *J Hum Evol*, 17: 715–718.
4. Henle J (1858) *Handbuch der systematischen Anatomie des Menschen*. Friedrich Vieweg und Sohn, Braunschweig, pp. 161–164.
5. Penhall B, Townsend G, Tomo S, Nakajima K (1998) The pterygoideus proprius muscle revisited. *Clin Anat*, 11: 332–337.
6. Shimokawa T, Akita K, Sato T, Ru F, Yi SQ, Tanaka S (2004) Penetration of muscles by branches of the mandibular nerve: a possible cause of neuropathy. *Clin Anat*, 17: 2–5.