

Two variant muscles in the gluteal region

Nicol Zielinska¹, Richard Shane Tubbs^{2–7}, Piotr Łabętowicz¹, Łukasz Olewnik¹

¹Department of Anatomical Dissection and Donation, Medical University of Lodz, Poland

²Department of Anatomical Sciences, St. George's University, Grenada, West Indies

³Department of Neurosurgery, Tulane University School of Medicine, New Orleans, Louisiana, United States

⁴Department of Neurology, Tulane University School of Medicine, New Orleans, Louisiana, United States

⁵Department of Structural and Cellular Biology, Tulane University School of Medicine, New Orleans, Louisiana, United States

⁶Department of Surgery, Tulane University School of Medicine, New Orleans, Louisiana, United States

⁷Department of Neurosurgery, Ochsner Medical Centre, New Orleans, Louisiana, United States

[Received: 19 August 2022; Accepted: 9 November 2022; Early publication date: 16 February 2023]

The short lateral rotators of the thigh found in the gluteal region can have morphological variations. During anatomical dissection of a right lower limb, two variant structures were found in this region. The first of these accessory muscles originated from the external surface of the ramus of the ischium. Distally, it was fused with the gemellus inferior muscle. The second structure comprised tendinous and muscular parts. The proximal part originated from the external part of the ischiopubic ramus. It inserted on the trochanteric fossa. Both structures were innervated by small branches of the obturator nerve. The blood supply was via branches of the inferior gluteal artery. There was also a connection between the quadratus femoris and the superior part of the adductor magnus. These morphological variants could be clinically important. (Folia Morphol 2024; 83, 1: 235–238)

Keywords: pelvic region, morphological variations, gluteus inferior, gluteus superior, quadratus femoris, sciatic nerve, adductor minimus, adductor magnus

INTRODUCTION

The lateral rotator muscles of the thigh include the piriformis (PM), gemellus superior (GS) and inferior (GI), obturator externus (OE) and internus (OI), and quadratus femoris (QF) muscles [17]. These muscles can be morphologically variable. For example, the GS or GI can be absent (very rarely, both the GS and GI are lacking) [2, 8, 16]. These muscles can be also doubled [15]. Cases have been reported in which the GS is fused with the PM or gluteus minimus, or the GI is fused with the QF [12]. The OI is not as variable, though it can be divided into two distinct parts [9].

The PM, in contrast, is morphologically highly variable. For example, it can be fused with the GS, or OI, or gluteus medius [3].

Morphological variations in this region can have clinical implications. For example, additional structures such as an accessory head of the PM can compress nearby nerves or arteries. In cases of a three-headed PM, with the common fibular nerve passing between the first and second heads and the tibial nerves passing between the second and the third, there can be paraesthesia, loss of sensation, or lack or weakened function of the muscles [13].

Address for correspondence: Łukasz Olewnik, DPT, PhD, Ass. Prof., Department of Anatomical Dissection and Donation, Medical University of Lodz, ul. Żeligowskiego 7/9, 90–136 Łódź, Poland, e-mail: lukasz.olewnik@umed.lodz.pl

This article is available in open access under Creative Commons Attribution-Non-Commercial-No Derivatives 4.0 International (CC BY-NC-ND 4.0) license, allowing to download articles and share them with others as long as they credit the authors and the publisher, but without permission to change them in any way or use them commercially.

Here, we report an unusual muscle found in the gluteal region during dissection and discuss the potential clinical ramifications.

CASE REPORT

An 84-year-old at death female cadaver donated to science was subjected to routine anatomical dissection for research and teaching purposes at the Department of Anatomical Dissection and Donation Medical University of Lodz, Poland. The left lower limb and its gluteal region were dissected traditionally and two interesting structures were found.

The next stage of the investigation involved detailed assessment of these variant muscles. The first muscle had only a muscular part, originating from the external surface of the ramus of the ischium (near the ischiopubic ramus). At the proximal attachment it was 7.46 mm wide and 2.17 mm thick. It was 79.90 mm long. Distally, this accessory muscle was fused with the GI, attached to the trochanteric fossa. At the point of fusion the width was 3.97 mm and the thickness 1.11 mm.

The second structure comprised tendinous and muscular parts. The proximal part originated from the external part of the ischiopubic ramus. At this point was 3.36 mm wide and 1.08 mm thick. The muscular part was 89.00 mm long, after which it passed into the tendinous part. The width at the myotendinous junction was 2.97 mm and the thickness was 1.64 mm. The tendon of this variant structure was 25.91 mm long, and it inserted on the trochanteric fossa. At this point it was 2.62 mm wide and 1.18 mm thick. Both structures were innervated by small branches of the obturator nerve. Blood was supplied by branches of the inferior gluteal artery (Fig. 1).

An electronic calliper (Mitutoyo Corporation, Kawasaki-shi, Kanagawa, Japan) was used for these measurements. Each measurement was repeated twice with an accuracy of up to 0.1 mm. No other morphological variants were found during dissection of the lower limb. Table 1 shows the morphometric measurements of the present case.

DISCUSSION

Muscles of pelvic region are morphologically variable. Sometimes there is no GS, or no GI, and in rare cases, both are lacking [2, 8, 16]. The QF can also be absent, and in most such cases there is an associated increase in the volume of the GI [16].

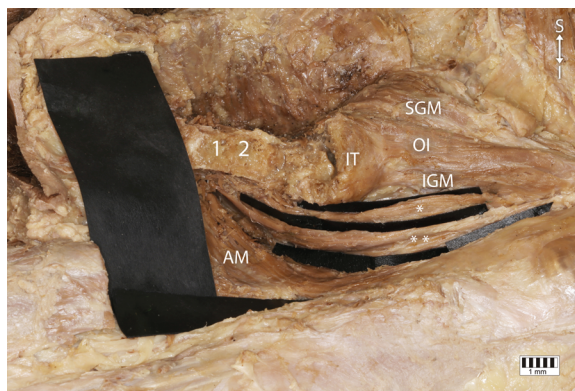


Figure 1. Anatomical variations of pelvic girdle; 1 — external part of the ischiopubic ramus; 2 — external surface of the ramus of the ischium; 3 — superior gemellus muscle (SGM); OI — obturator internus; IGM — inferior gemellus muscle; IT — ischial tuberosity; AM — adductor magnus; *first accessory muscle; **second accessory muscle.

Table 1. Morphometric measurements of the present case.

	1 st	2 nd
LENGTH	79.90 mm	114.91 mm (89.00 mm — muscular part 25.91 mm — tendinous part)
WIDTH		
PP	7.46 mm	3.36 mm
MJ	—	2.97 mm
PK	3.97 mm	2.62 mm
THICKNESS		
PP	2.17 mm	1.08 mm
MJ	—	1.34 mm
PK	1.11 mm	1.18 mm

MJ — myotendinosus junction; PP — proximal attachment; PK — distal attachment.

Some fusions have also been described in this region. For example, the GI can be fused with the QF. Leal et al. [12] also described fusion between the GS and the gluteus minimus. Charpy and Nicolas [5] found a muscular connection between the QF and the GI, and between the QF and the adductor magnus [5].

Macalister [10] reported that the QF can have two or three distinct parts. It is not known whether this was a divided muscle belly or duplication [13], though there are more detailed descriptions in the literature. For example, Natsis et al. [14] found two-headed PMs in 12 (4.1%) cases. Curiously, these two heads showed different arrangements. In five cases the first belly was not located superiorly to the second (as it is in most cases); it was positioned superficially and the other one more deeply [14]. Cassidy et al. [4] found cases in which the superior belly was partially superposed

on the inferior belly [4]. Such arrangements of two bellies can also occur in morphological variants of other pelvic muscles.

Tanyeli et al. [15] described an interesting case with a double PM, double GS, double GI, and double QF. The superior part of the PM originated from the anterior surface of the sacrum and the inferior part from the sacrotuberous ligament. Their common distal attachment was on the greater trochanter. The upper head of the GS was proximally attached on the body of the ischium and the lower head was attached to the ischial spine. The first head of the GI was proximally attached to the ischiadic spine and the second head to the ischial tuberosity. These four structures were inserted on to the greater trochanter. The final variation was the double QF, both parts originating from the ischial tuberosity and attaching distally on the intertrochanteric crest [15].

Analysing the attachments described above, we excluded the possibility that the present case involved an additional head of the PM or GS. However, a double GI and double QF seemed possible. We found two accessory structures. The first (superior) was fused with the GI, so it could either be an additional head of the GI or something never previously described in the literature. However, the second structure (inferior) was not connected to either the superior variant structure or the QF, so we cannot call it an accessory head of the QF or GI.

Interestingly, the volume of the QF was smaller than normal. In most cases, when the QF is absent, the volume of the GI is increased [16]. We can therefore infer that the additional structures described herein could be associated with incomplete development of the QF.

Moreover, the QF can be fused with the adductor magnus or adductor minimus, as it was in the present case. It is hard to say with which muscle it was fused because the adductor minimus is controversial in the literature. Some authors describe it as only a part of the adductor magnus [6], some as partially separate from the adductor magnus [14], and some as a completely separate accessory muscle. In our opinion, there was fusion between the superior part of the adductor magnus and the QF [7].

To assess the clinical significance of these variant structures, we should consider their position and morphological features. Usually, accessory structures are connected with some kind of neurovascular compression. For example, Arifoglu et al. [1] described

a case with double GS and double PF. The sciatic nerve passed between the two heads of the PF. In such variants there is a risk of piriformis syndrome, represented by chronic pain in the buttocks and hip with sporadic referred pain along the sciatic nerve distribution, external tenderness over the greater sciatic notch, aggravation of the pain through sitting, augmentation of it with manoeuvres that increase PM tension, and sometimes dyspareunia [10].

However, in the present case, the PM was anatomically normal and the sciatic nerve passed under it. Because the sciatic nerve was located under the described structures, the risk of PM syndrome was not high.

Taking everything into consideration, it is hard to say whether we should describe the superior variant muscle as an additional head of the GI or as something not previously described. In view of its course and morphological characteristics, the other variant muscle does not look like an accessory head of any pelvic muscle; it looks like a separate structure that is not a feature of normal anatomy.

CONCLUSIONS

The pelvic region shows several morphological variations. Accessory muscles can be associated with compression of nerves or vessels, and knowledge of them can therefore be important for clinicians, especially orthopaedists, neurologists, and physiotherapists. However, neurovascular compression depends on the arrangement and morphological characteristics of the variant muscles.

Ethical approval and consent to participate

The study protocol was accepted by the Bioethics Committee of the Medical University of Lodz. The cadavers were the property of the Department of Anatomical Dissection and Donation, Medical University of Lodz. Informed consents were obtained from all participants before they died.

Acknowledgements

The authors sincerely thank those who donated their bodies to science so that anatomical research could be performed. Results from such research can potentially increase mankind's overall knowledge that can then improve patient care. Therefore, these donors and their families deserve our highest gratitude [11].

Conflict of interest: None declared

REFERENCES

1. Arifoglu Y, Sürücü HS, Sargon MF, et al. Double superior gemellus together with double piriformis and high division of the sciatic nerve. *Surg Radiol Anat.* 1997; 19(6): 407–408, doi: [10.1007/BF01628510](https://doi.org/10.1007/BF01628510), indexed in Pubmed: [9479716](https://pubmed.ncbi.nlm.nih.gov/9479716/).
2. Bajka M, Manestar M, Hug J, et al. Detailed anatomy of the abdomen and pelvis of the visible human female. *Clin Anat.* 2004; 17(3): 252–260, doi: [10.1002/ca.10215](https://doi.org/10.1002/ca.10215), indexed in Pubmed: [15042575](https://pubmed.ncbi.nlm.nih.gov/15042575/).
3. Bergman R, Afifi A, Miyauchi R. *Illustrated Encyclopedia of Human Anatomic Variations. Anatomy Atlases 2017.*
4. Cassidy L, Walters A, Bubbb K, et al. Piriformis syndrome: implications of anatomical variations, diagnostic techniques, and treatment options. *Surg Radiol Anat.* 2012; 34(6): 479–486, doi: [10.1007/s00276-012-0940-0](https://doi.org/10.1007/s00276-012-0940-0), indexed in Pubmed: [22327640](https://pubmed.ncbi.nlm.nih.gov/22327640/).
5. Charpy A, Nicolas A. *Traite d'Anatomie Humaine.* In: Masson et Cie, Paris 1912: 238.
6. Clemente C. *Anatomy. A regional atlas of the human body.* Urban&Scha, Baltimire 1981.
7. Le Do. *Traité Des Variations Du Système Musculaire de l'homme et de Leur Signification Au Point de Vue de l'anthropologie Zoologique.* Schleicher frères, Paris 1897.
8. Duda GN, Brand D, Freitag S, et al. Variability of femoral muscle attachments. *J Biomech.* 1996; 29(9): 1185–1190, doi: [10.1016/0021-9290\(96\)00025-5](https://doi.org/10.1016/0021-9290(96)00025-5), indexed in Pubmed: [8872275](https://pubmed.ncbi.nlm.nih.gov/8872275/).
9. Gruber W. *Die Musculi Subscapulares (Major et Minor) Und Die Neuen Supernumären Schultermuskel Des Menschen.* Mémoires de l'Académie Impériale Des Sciences de Saint Pétersbourg Par Divers Savans et Lus Dans Ses Assemblées. 4th ed. Sankt Petersburg 1859.
10. Hopayian K, Song F, Riera R, et al. The clinical features of the piriformis syndrome: a systematic review. *Eur Spine J.* 2010; 19(12): 2095–2109, doi: [10.1007/s00586-010-1504-9](https://doi.org/10.1007/s00586-010-1504-9), indexed in Pubmed: [20596735](https://pubmed.ncbi.nlm.nih.gov/20596735/).
11. Iwanaga J, Singh V, Ohtsuka A, et al. Acknowledging the use of human cadaveric tissues in research papers: Recommendations from anatomical journal editors. *Clin Anat.* 2020; 34(1): 2–4, doi: [10.1002/ca.23671](https://doi.org/10.1002/ca.23671), indexed in Pubmed: [32808702](https://pubmed.ncbi.nlm.nih.gov/32808702/).
12. Leal MC, Alexander JG, Beber EH, et al. The absence of piriformis muscle, combined muscular fusion, and neurovascular variation in the gluteal region. *Autops Case Rep.* 2021; 11: e2020239, doi: [10.4322/acr.2020.239](https://doi.org/10.4322/acr.2020.239), indexed in Pubmed: [34307211](https://pubmed.ncbi.nlm.nih.gov/34307211/).
13. Macalister A. Observations on muscular anomalies in the human anatomy. Third series with a catalogue of the principal muscular variations hitherto published. *Trans Roy Irish Acad Sci.* 1875: 1–130.
14. Natsis K, Totlis T, Konstantinidis GA, et al. Anatomical variations between the sciatic nerve and the piriformis muscle: a contribution to surgical anatomy in piriformis syndrome. *Surg Radiol Anat.* 2014; 36(3): 273–280, doi: [10.1007/s00276-013-1180-7](https://doi.org/10.1007/s00276-013-1180-7), indexed in Pubmed: [23900507](https://pubmed.ncbi.nlm.nih.gov/23900507/).
15. Tanyeli E, Pestemalci T, Uzel M, et al. The double deep gluteal muscles. *Saudi Med J.* 2006; 27(3): 385–386, indexed in Pubmed: [16532103](https://pubmed.ncbi.nlm.nih.gov/16532103/).
16. Testut L. *Les Anomalies Musculaires Chez l'homme Expliquées Par Anatomie Comparée, Importance En Anthropologie.* Masson, Paris 1884.
17. Yoo S, Dedova I, Pather N. An appraisal of the short lateral rotators of the hip joint. *Clin Anat.* 2015; 28(6): 800–812, doi: [10.1002/ca.22568](https://doi.org/10.1002/ca.22568), indexed in Pubmed: [26032283](https://pubmed.ncbi.nlm.nih.gov/26032283/).