

Anatomical variations in the first dorsal compartment of the wrist: meta-analysis

M. Bonczar¹, J. Walocha, A. Pasternak, P. Depukat, M. Dziedzic, P. Ostrowski, T. Bonczar, Ł. Warchoń, M. Koziej

Department of Anatomy, Jagiellonian University Medical College, Krakow, Poland

[Received: 31 June 2022; Accepted: 9 September 2022; Early publication date: 27 September 2022]

Background: The first dorsal compartment of the wrist includes tendons of abductor pollicis longus (APL) and extensor pollicis brevis (EPB). However, many studies have showed multiple anatomical variations including anomalies in the number of both APL and EPB tendons and presence of intercompartmental fibro-osseous septum. Unfortunately, studies describing those variations are not consistent, hence, the aim of this study was to provide most accurate data about these anatomical variations in the population, using systematic review and meta-analysis.

Materials and methods: For this purpose, PubMed, Scopus, Web of Science, Embase and a number of minor online libraries were searched. Articles which included exact data about the number of APL or EPB tendons or a presence of intercompartmental septum were qualified for a more precise evaluation. Therefore, out of 1629 studies initially evaluated, 68 were finally included in this meta-analysis. We followed the Preferred Reporting Items for Systematic Reviews and Meta-Analyses (PRISMA) guidelines.

Results: A total of 5229 studied wrists have been included in this study. Double APL and single EPB are the most common variations of tendons in the first dorsal compartment, both in cadavers and patients with de Quervain's disease, with no statistically significant differences between those two groups. Presence of intercompartmental fibro-osseous septum is much more common in patients with de Quervain's disease than in cadavers.

Conclusions: Our results should improve the awareness of anatomical variations in the first dorsal compartment, which in turn should have impact on treatment of de Quervain's disease in clinical practice. (Folia Morphol 2023; 82, 4: 766–776)

Key words: de Quervain's disease, abductor pollicis longus, extensor pollicis brevis

INTRODUCTION

The first dorsal compartment of the wrist, also known as first extensor compartment of the wrist, includes tendons of abductor pollicis longus (APL) and of extensor pollicis brevis (EPB). APL tendon inserts into the radial side of the base of the first metacarpal bone

but also into the trapezium bone, allowing abduction and extension in the carpometacarpal joint of the thumb. EPB tendon inserts into the base of the first phalanx of the thumb, allowing extension in the metacarpophalangeal joint of the thumb. However, many studies have showed multiple anatomical variations in

Address for correspondence: Dr. M. Koziej, Department of Anatomy, Jagiellonian University Medical College, ul. Mikołaja Kopernika 12, 33–332 Kraków, Poland, tel: +48 888 202 628, e-mail: mateusz.koziej@gmail.com

This article is available in open access under Creative Common Attribution-Non-Commercial-No Derivatives 4.0 International (CC BY-NC-ND 4.0) license, allowing to download articles and share them with others as long as they credit the authors and the publisher, but without permission to change them in any way or use them commercially.

the first dorsal compartment. Most frequently reported anomalies are multiple APL tendons, multiple EPB tendons and the presence of the intercompartmental fibro-osseous septum [3, 8, 25, 41, 48]. Unfortunately, studies describing those variations are not consistent. Awareness of anatomical anomalies in the first dorsal compartment is highly significant during both conservative and surgical treatment of de Quervain's disease. Usually, first method used in clinical treatment of de Quervain's disease are corticosteroid injections into the first dorsal compartment of the wrist [49]. Knowledge of anatomical conditions in the first dorsal compartment may increase chances of successful steroid treatment [49]. During surgical treatment of de Quervain's disease, anatomical orientation may prevent potential misinterpretations, which may lead to failure to decompress the compartment [16]. Therefore, the aim of this study was to provide most accurate data about these anatomical variations in the population, using systematic review and meta-analysis.

MATERIALS AND METHODS

Search strategy

Data collection was performed in January 2022 using either leading databases such as PubMed, Scopus, Web of Science and Embase but also number of minor online libraries. Search was made for publications referring to anatomical variations in the first dorsal compartment of the wrist, especially number of APL tendons, number of EPB tendons and presence of intercompartmental fibro-osseous septum. Search was ended in February 2022. Searched phrases were made according to Boolean search terms. In each database we used the following scheme: (first) AND ((dorsal) OR (extensor)) AND ((compartment) OR (slot)) AND ((anatomy) or (anatomic) or (anatomical) OR (variations) OR (variant) OR (anomalies)). We also used terms like "de Quervain's", "Quervain", "APL", "abductor pollicis longus", "EPB", "extensor pollicis brevis", "septum", "extensor retinaculum" in many variations. Neither date, language, article type or text availability conditions were applied. During our study we followed the Preferred Reporting Items for Systematic Reviews and Meta-Analyses (PRISMA) guidelines. Furthermore, the Critical Appraisal Tool for Anatomical Meta-analysis (CATAM) was used to provide the highest quality findings [13].

Eligibility criteria

A total of 1629 articles were initially evaluated including the main search and search through the

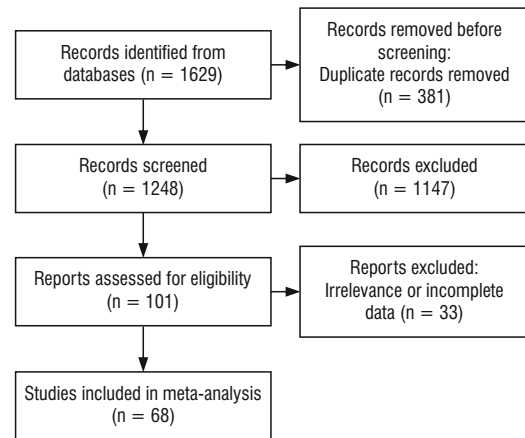


Figure 1. Flow diagram presenting process of collecting data included in this meta-analysis.

references of the classified articles. After removing duplicates, 1248 publications were enrolled. Each article which included exact data about number of APL tendons or number of EPB tendons or a presence of intercompartmental septum was qualified for a more precise evaluation. Studies showing incomplete data, conference abstracts, letter to the editors or case reports were excluded. Subsequently, 101 articles were extracted, of which 33 were excluded due to its irrelevance or incomplete data. Finally, 68 articles were included in this meta-analysis. To minimise bias of included studies, we used the AQUA Tool which was specifically designed for anatomical meta-analyses. Process of collecting data is imaged in Figure 1.

Data extraction

Data from qualified studies were extracted manually by two independent researchers. Numerical and categorical data including number of APL tendons, number of EPB tendons, presence of septum, number of individuals, number of wrists, sex of subjects and geographic location were extracted.

Statistical analysis

In order to perform those meta-analysis we used STATISTICA version 13.1 software (StatSoft Inc., Tulsa, OK, USA) and MetaXL version 5.3 (EpiGear International Pty Ltd, Wilston, Queensland, Australia) to calculate the pooled prevalence. We performed a random-effects model in all analyses. Heterogeneity among the studies was assessed, using both the Chi-squared test and I-squared statistic [23]. A p value less than 0.05 was considered to be statistically

significant. We interpretate the I-squared statistic as follows: 0–40% as “might not be important”; 30–60% as “may represent moderate heterogeneity”; 50–90% as “may represent substantial heterogeneity”; 75–100% as “may represent considerable heterogeneity”. In order to determine statistically significant differences between studied groups, we used confidence intervals (CIs). If the CIs between groups overlapped, we considered the differences insignificant, while in the reverse situation, we considered the differences statistically significant.

RESULTS

Due to diversity of studied groups we decided to divide the extracted data into three categories — cadavers, patients with the de Quervain’s disease and patients without the de Quervain’s disease. Each category includes meta-analysis of data considering quantity of APL tendons, EPB tendons and presence of septum in the first dorsal compartment. Sets of characteristics from each study that has been included in this meta-analysis are presented in Table 1. Summarised geographic features of admitted articles can be found in Table 2.

Table 1. Characteristic of included studies

Author, year	Continent	Country	Affiliation*	Number of studied wrists
Roy et al., 2016	Asia	India	1	86
Gao et al., 2017	Asia	China	1	40
Aktan et al., 1998	Asia	Turkey	1, 2	69
Hazani et al., 2008	North America	USA	1	32
Sugiura et al., 2017	Asia	Japan	1	45
Nam et al., 2018	Asia	South Korea	1	40
Xu et al., 2018	Asia	China	1	2
Jackson et al., 1986	North America	USA	1, 2	340
Shiraishi and Matsumura, 2005	Asia	Japan	1	60
Takahashi et al., 1994	Asia	Japan	1, 2	267
Kutsumi et al., 2005	North America	USA	1	15
Bernstein et al., 2019	North America	Texas	1, 2	181
Mahakkanukrauh and Mahakkanukrauh, 2000	Asia	Thailand	1	200
Gurses et al., 2015	Asia	Turkey	1	50
Alemohammad et al., 2009	Asia	Iran	1, 2	233
Kang et al., 2017	Asia	South Korea	1	30
Nayak et al., 2009	Asia	India	1	156
Kulthanan and Chareonwat, 2007	Asia	Thailand	1, 2	148
Ravi et al., 2019	Asia	India	1	77
Mirzanli et al., 2012	Asia	Turkey	1	150
Rousset et al., 2010	Europe	Paris	1	40
Opreanu et al., 2010	North America	USA	1	50
Tripathy et al., 2015	Asia	India	1	50
Motoura et al., 2010	Asia	Japan	1	246
Minamikawa et al., 1991	North America	USA	1, 2	141
Sugiura et al., 2019	Asia	Japan	1	24
Leslie et al., 1990	North America	USA	1	100
Gonzalez et al., 1995	North America	USA	1	66
Liversedge et al., 2016	North America	USA	1	50
Kutsikovich and Merrell, 2018	North America	USA	1	43
Öztürk et al., 2021	Asia	Turkey	1	86
Güleç et al., 2016	Asia	Turkey	1	48

→

Table 1. cont. Characteristic of included studies

Author, year	Continent	Country	Affiliation*	Number of studied wrists
Suhani et al., 2012	Asia	India	1	73
Abdel-Hamid et al., 2013	Africa	Egypt	1	95
Leao, 1958	South America	Brazil	1	50
dos Remédios et al., 2005	Europe	France	1	31
Bharambe et al., 2017	Asia	India	1	100
Vollala, 2006	Asia	India	1	100
Giles, 1960	Europe	England	1	50
Oudenaarde, 1991	Europe	Netherlands	1	84
Schulz et al., 2002	Europe	Germany	1	73
Palatty et al., 2020	Asia	India	1	50
El-Beshbishy and Abdel-Hamid, 2013	Asia	Saudi Arabia	1	50
Brunelli and Brunelli, 1992	Europe	Italy	1	52
Kulshreshtha et al., 2007	Europe	England	1	44
Matzon et al., 2019	North America	USA	2	130
Choi et al., 2011	Asia	South Korea	2	15
Gousheh et al., 2009	Asia	Iran	2	50
Beutel et al., 2020	North America	USA	2, 3	102
Bahm et al., 1995	Europe	France	2	10
Lee et al., 2014	Asia	South Korea	2	60
Chang et al., 2017	North America	USA	2	94
Stahl et al., 2015	Europe	Germany	2	77
Kwon et al., 2010	Asia	South Korea	2	43
Sato et al., 2016	Asia	Japan	2	112
McDermott et al., 2012	North America	USA	2	42
Bing et al., 2018	Asia	South Korea	2	28
Kim et al., 2020	Asia	South Korea	2	29
López Mendoza et al., 2011	North America	Mexico	2	32
Shiroishi et al., 2002	Asia	Japan	2	158
Harvey et al., 1990	Australia	Australia	2	20
Yuasa and Kiyoshige, 1998	Asia	Japan	2	22
de Keating-Hart et al., 2016	Europe	France	2	41
Alexander et al., 2002	North America	USA	2	26
Witt et al., 1991	North America	USA	2	30
Weiss et al., 1994	North America	USA	2	45
Nagaoka et al., 2000	Asia	Japan	2	32
Hoch et al., 2004	Europe	Germany	3	14

*Affiliation of data to subcategory; 1 — cadaveric group; 2 — patients with de Quervain's disease group; 3 — patients without de Quervain's disease

APL

The quantity of APL tendons in the first dorsal compartment of the wrist was examined in 21 cadaveric studies [3, 8, 14, 16, 17, 22, 25, 26, 30, 32, 47, 51–53, 57, 59, 60, 65–68] including 1749 wrists. Number of APL tendons varied from zero to seven.

For a single APL tendon, prevalence was 16.91% (95% CI: 8.96–26.63%). For a double APL tendon, prevalence was 46.04% (95% CI: 36.84–55.38%). For a triple APL tendon, prevalence was 19.19% (95% CI: 13.24–25.92%). Results mentioned above, are all gathered in Table 3.

Table 2. Summarized geographic featured of admitted articles

Continent	Number of studies	Number of wrists
Africa	1	95
Asia	36	3029
Australia	1	20
Europe	11	516
North America	18	1519
South America	1	50
Overall	68	5229

The quantity of APL tendons in the first dorsal compartment of the wrist in patients with de Quervain’s disease was examined in 9 studies [3, 5, 12, 25, 30, 39, 41, 61, 66] including 608 wrists. Number of APL tendons varied from 1 to 6. For a single APL tendon, prevalence was 23.79% (95% CI: 15.12–33.68%). For a double APL tendon, prevalence was 45.33% (95% CI: 38.88–51.86%). For a triple APL tendon, prevalence was 22.69% (95% CI: 17.29–28.58%). Results mentioned above, are all gathered in Table 3.

Table 3. Statistical result of meta-analysis in each category

Category	Structure	Subcategory	Number of wrists	Prevalence	LCI	HCI	Cochran’s Q	I ² (95% CI)
Cadavers	APL	None APL	1749	0.27%	0.07%	0.58%	4.84	0.00 (0.00–0.00)
		Single APL	1749	16.91%	8.96%	26.63%	471.02	95.75 (94.53–96.70)
		Double APL	1749	46.04%	36.84%	55.38%	297.65	93.28 (91.01–94.98)
		Triple APL	1749	19.19%	13.24%	25.92%	219.99	90.91 (87.49–93.39)
		Quadruple APL	1749	5.91%	3.26%	9.24%	131.98	84.85 (78.07–89.53)
		Fivefold APL	1749	1.53%	0.61%	2.81%	62.56	68.03 (49.74–79.66)
		Sixfold APL	1749	0.65%	0.28%	1.16%	24.17	17.25 (0.00–51.02)
	Sevenfold APL	1749	0.33%	0.11%	0.66%	17.12	0.00 (0.00–38.13)	
	EPB	None EPB	1814	1.18%	0.63%	1.89%	28.99	27.55 (0.00–57.00)
		Single EPB	1814	94.89%	92.54%	96.82%	81.45	74.22 (60.85–83.02)
		Double EPB	1814	3.47%	1.85%	5.55%	86.94	75.85 (63.59–83.98)
		Triple EPB	1814	0.49%	0.21%	0.87%	19.22	0.00 (0.00–41.21)
		Quadruple EPB	1814	0.27%	0.07%	0.57%	5.28	0.00 (0.00–0.00)
	Septum	Absent septum	2635	54.26%	47.25%	61.18%	383.58	91.92 (89.64–93.69)
Single septum		2635	45.74%	38.82%	52.75%	383.58	91.92 (89.64–93.69)	
Patients with de Quervain’s disease	APL	Single APL	608	23.79%	15.12%	33.68%	54.01	85.19 (73.70–91.66)
		Double APL	608	45.33%	38.88%	51.86%	19.12	58.16 (12.40–80.02)
		Triple APL	608	22.69%	17.29%	28.58%	20.37	60.72 (18.49–81.07)
		Quadruple APL	608	5.37%	2.50%	9.16%	23.63	66.13 (31.32–83.31)
		Fivefold ALP	608	1.04%	0.35%	2.06%	8.27	3.24 (0.00–65.94)
		Sixfold APL	608	0.38%	0.02%	1.07%	2.53	0.00 (0.00–0.00)
	EPB	None EPB	608	2.38%	0.98%	4.33%	13.12	39.00 (0.00–71.93)
		Single EPB	608	92.04%	89.63%	94.16%	8.59	6.87 (0.00–67.22)
		Double EPB	608	4.65%	1.90%	8.44%	25.88	69.09 (38.21–84.54)
		Triple EPB	608	0.75%	0.19%	1.63%	3.01	0.00 (0.00–6.58)
	Septum	Absent septum	1592	36.37%	30.98%	41.94%	142.47	80.35 (72.47–85.97)
		Single septum	1592	63.30%	57.66%	68.76%	145.767	80.79 (73.15–86.26)
		Double septum	1592	0.69%	0.34%	1.17%	28.30	1.06 (0.00–41.95)
	Patients without de Quervain’s disease	APL	Single APL	14	90.26%	71.79%	100.00%	0.00
Double APL			14	9.74%	0.00%	28.21%	0.00	0.00 (0.00–0.00)
EPB		None EPB	56	3.58%	0.06%	10.47%	0.00	0.00 (0.00–0.00)
		Single EPB	56	96.42%	89.53%	99.94%	0.00	0.00 (0.00–0.00)
Septum		Absent septum	164	69.89%	19.49%	100.00%	62.16	96.78 (93.42–98.43)
		Single septum	164	30.11%	0.00%	80.51%	62.16	96.78 (93.42–98.43)

Table 3. cont. Statistical result of meta-analysis in each category

Category	Structure	Subcategory	Number of wrists	Prevalence	LCI	HCI	Cochran's Q	I ² (95% CI)
Overall results	APL	None APL	2371	0.29%	0.11%	0.55%	7.18	0.00 (0.00–0.00)
		Single APL	2371	22.26%	15.34%	30.04%	564.23	94.51 (93.15–95.59)
		Double APL	2371	43.45%	36.77%	50.26%	332.66	90.68 (87.93–92.81)
		Triple APL	2371	19.27%	14.73%	24.26%	258.75	88.02 (84.17–90.93)
		Quadruple APL	2371	5.67%	3.67%	8.06%	154.82	79.98 (72.37–85.49)
		Fivefold APL	2371	1.43%	0.75%	2.32%	70.64	56.12 (37.79–70.46)
		Sixfold APL	2371	0.56%	0.29%	0.90%	27.17	0.00 (0.00–31.20)
	Sevenfold APL	2371	0.34%	0.14%	0.63%	18.54	0.00 (0.00–0.00)	
	EPB	None EPB	2478	1.57%	0.99%	2.28%	48.83	34.47 (0.00–57.20)
		Single EPB	2478	94.11%	92.28%	95.70%	95.46	66.48 (51.75–76.71)
		Double EPB	2478	3.78%	2.39%	5.46%	117.25	72.71 (61.46–80.67)
		Triple EPB	2478	0.57%	0.31%	0.91%	23.07	0.00 (0.00–15.69)
		Quadruple EPB	2478	0.29%	0.11%	0.55%	6.50	0.00 (0.00–0.00)
	Septum	Absent septum	4391	47.38%	42.24%	52.55%	751.84	91.35 (89.70–92.74)
Single septum		4391	52.62%	47.45%	57.76%	751.84	91.35 (89.70–92.74)	

APL — abductor pollicis longus; CI — confidence interval; EPB — extensor pollicis brevis; HCI — higher confidence interval; LCI — lower confidence interval; septum — intercompartmental fibro-osseous septum in the first dorsal compartment of the wrist

Overall, the number of APL tendons in the first dorsal compartment of the wrist was analysed in 2371 wrists. The number of APL tendons ranged from 0 to 7. The variation that occurs the most frequently was found to be a double APL tendon with a prevalence of 43.45% (95% CI: 36.77–50.26%). All the results mentioned above and the more detailed ones are gathered in Table 3.

EPB

The quantity of EPB tendons in the first dorsal compartment of the wrist was examined in 22 cadaveric studies [1, 3, 8, 10, 16, 17, 22, 25, 26, 29, 30, 47, 48, 52–54, 56, 57, 60, 63, 66, 71] including 1814 wrists. Number of EPB tendons varied from 0 to 4. For a single EPB tendon, prevalence was 94.89% (95% CI: 92.54–96.82%). Results mentioned above, are all gathered in Table 3.

The quantity of EPB tendons in the first dorsal compartment of the wrist in patients with de Quervain's disease was examined in 9 studies [3, 5, 12, 25, 30, 39, 41, 61, 66] including 608 wrists. Number of EPB tendons varied from 0 to 3. For a single EPB tendon, prevalence was 92.04% (95% CI: 89.63–94.16%). Results mentioned above, are all gathered in Table 3.

Overall, the number of EPB tendons in the first dorsal compartment of the wrist was analysed in 2478 wrists. The number of EPB tendons ranged from 0 to 4.

The variation that occurs the most frequently was found to be a single EPB tendon with a prevalence of 94.11% (95% CI: 92.28–95.70%). All the results mentioned above and the more detailed ones are gathered in Table 3.

Septum

The presence of intercompartmental fibro-osseous septum in the first dorsal compartment of the wrist was examined in 32 cadaveric studies [2, 3, 6, 10, 15, 17, 19, 20, 22, 25, 26, 30–32, 34, 37, 38, 40, 43–45, 47, 48, 50, 54–57, 63, 64, 66, 71] including 2635 wrists. The septum was either present or not (there were no reports of double septum in this group, unlike in the patients with de Quervain's disease group). For absence of septum, prevalence was 54.26% (95% CI: 47.25–61.18%). For presence of septum, prevalence was 45.74% (95% CI: 38.82–52.75%). Results mentioned above, are all gathered in Table 3.

The presence of intercompartmental fibro-osseous septum in the first dorsal compartment of the wrist in patients with de Quervain's disease was examined in 29 studies [2–7, 9, 11, 12, 18, 21, 25, 27, 28, 30, 33, 35, 39, 41–43, 46, 58, 61, 62, 66, 69, 70, 72] including 1592 wrists. The septum was either absent, single or double. For absence of septum, prevalence was 36.37% (95% CI: 30.98–41.94%). For a single septum, prevalence was 63.30% (95% CI: 57.66–68.76%).

Table 4. P-values obtained after comparing cadavers and patients with de Quervain's disease groups

Compared variant	P
Single APL	0.3912
Double APL	0.9131
Triple APL	0.4754
Quadruple APL	0.8463
Fivefold APL	0.5955
Sixfold APL	0.5034
None EPB	0.2058
Single EPB	0.1016
Double EPB	0.6000
Triple EPB	0.6051
Absent septum	0.0002
Present septum	0.0007

APL — abductor pollicis longus; EPB — extensor pollicis brevis; septum — intercompartmental fibro-osseous septum in the first dorsal compartment of the wrist

For a double septum, prevalence was 0.69% (95% CI: 0.34–1.17%). Results mentioned above, are all gathered in Table 3.

The presence of intercompartmental fibro-osseous septum in the first dorsal compartment of the wrist in patients without de Quervain's disease was examined in 3 studies [7, 11, 24] including 164 wrists. The septum was either present or not (there were no reports of double septum in this group, unlike in the patients with de Quervain's disease group). For absence of septum, prevalence was 69.89% (95% CI: 19.49–100.00%). For presence of septum, prevalence was 30.11% (95% CI: 0.00–80.51%). Results mentioned above, are all gathered in Table 3.

Overall, the presence of the intercompartmental septum in the first dorsal compartment of the wrist was analysed in 4391 wrists. The septum occurred in 52.62% (95% CI: 47.45–57.76%). All the results mentioned above and the more detailed ones are gathered in Table 3.

Comparison between cadavers and patients with de Quervain's disease

Data regarding cadavers and patients with de Quervain's disease groups were compared and there are no statistically significant differences between cadavers and patients with de Quervain's disease when it comes to anatomical variations of APL and EPB tendons in the first dorsal compartment ($p > 0.05$). Moreover, there is statistically significant difference between cadavers and patients with de Quervain's

disease when it comes to presence of septum in the first dorsal compartment ($p < 0.05$). Those p-values are gathered in Table 4.

DISCUSSION

Content of the first dorsal compartment of the wrist shows great anatomical variability. Many studies have described those anomalies, but overall results are inconsistent and some conclusions excludes one another. In clinical practice, anatomy of the first dorsal compartment is essential during treatment of de Quervain's disease, while its effectiveness may rely on awareness of the contents of patients compartment. Our goal was to provide surgeon's with the most comprehensive meta-analysis of anatomical variations of the first compartment of the wrist, regarding a total of 5229 studied hands. Our results differ from another systematic-review [36] showing, among others, higher prevalence of double APL variant, lower prevalence of single APL variant, higher prevalence of septum in both cadaveric and de Quervain's groups etc.

Our results differ from previous major studies regarding prevalence of all APL variations [3, 8, 25, 36, 41, 66]. Our results shows that mostly occurs the double-tendon APL variety with its 43.45% prevalence overall, 46.04% prevalence in cadavers and 45.33% prevalence in patients with de Quervain's disease. Comparing those and rest of the results in both groups, it may be accounted that there are no statistically significant differences between cadavers and patients with de Quervain's disease when it comes to anatomical variations of APL tendons in the first dorsal compartment ($p > 0.05$). Taking into consideration that data showing prevalence of the double APL tendon in cadavers may represent considerable heterogeneity ($I^2 = 93.28$; 95% CI: 91.01–94.98) and the fact that the lower CI value of prevalence of double APL is higher than any higher CI value of any other APL variety, we may acknowledge double APL as a most common variant in the population. In contrast of APL, EPB dominates with its single-tendon variety, both in cadavers and in patients with de Quervain's disease. Our results differ from previous major studies regarding prevalence of all EPB variations [3, 8, 25, 36, 41, 48, 66]. Comparing other varieties of EPB in both groups, it can also be accounted, that there are no statistically significant differences between cadavers and patients with de Quervain's disease, when it comes to anatomical variations of EPB in the first dorsal compartment ($p > 0.05$). Single EPB

tendon may be acknowledged as standard in the population because data showing its prevalence may represent substantial heterogeneity ($I^2 = 74.22$; 95% CI: 60.85–83.02) and its prevalence lower CI value is much higher than any other prevalence higher CI value in any other EPB variety in cadaveric studies. In case of the septum, there are statically significant differences between cadaveric and de Quervain's disease groups ($p < 0.05$). The presence of the septum is much more common in the de Quervain's disease group than in the cadaveric group, with its prevalence for a single septum being 63.30% and 45.74%, respectively. We decided not to compare the patients without de Quervain's disease with other groups due to small amount of studies and lack of data about first dorsal compartment in the no de Quervain's disease group. Results mentioned above may suggest that presence of the septum in the first dorsal compartment of the wrist may be one of the factors causing de Quervain's disease. Also it may be that presence of the septum originates this ailment more likely than multiple variations of APL or EPB tendon slips in the compartment. Those suggests can be considered in the further studies.

Clinical treatment of de Quervain's disease usually starts with a non-surgical approach. Most frequently the first used therapy technique is corticosteroids injection into the first dorsal compartment sheath. Unfortunately, patients experience treatment success after 1 injection only in 51.8% of cases, according to Oh et al. [49]. Anatomical knowledge and awareness of most common variations in the first dorsal compartment may increase chances of successful steroid treatment. We hope that by taking in consideration our results, surgeons will more often perform steroid treatment under the ultrasonography control so the awareness of patients anatomical variation may not be oversight. Especially important factors that may affect results of this treatment are number of APL tendons due to its great diversity in the population and presence of septum, because it creates either fully or partly closed two sub-compartments and injecting steroids into both sub-compartments results with increased chances for successful therapy [27, 42, 73]. During surgical release of the first dorsal compartment, comprehensive anatomical knowledge may prevent potential overlook of the supernumerary tendons, lying in the separate sub-compartment [66]. This knowledge is essential for surgeons while treating de Quervain's disease, as it may prevent

inadequate recognition and in effect, failure to decompress the whole first dorsal compartment [36, 48]. Awareness of anatomical variations in the first dorsal compartment should also be helpful for radiologists who treat and examine wrists. Our results shows that arrangement of 3 tendons (double APL and single EPB) in the first dorsal compartment should be expected most often. This may help to accurately interpretate and describe imaging tests, which may be the base of further diagnostics. Additionally, obtaining an image of intercompartmental septum in the first dorsal compartment, should rise awareness, that this may be the factor causing de Quervain's disease in the future.

Taking in consideration geographical differences, especially in quantity of carried out research, authors are aware that results included in this meta-analysis might be burdened with a potential bias. Asia dominates with a number of studied wrists, while on the other side, researches realised in Africa, Australia or South America are singular. This may cause our results to reflect more of Asian than global population.

CONCLUSIONS

In conclusion, we believe that it is the most comprehensive analysis of the contents of the first dorsal compartment of the wrist. Double APL and single EPB are the most common variations of tendons in the first dorsal compartment overall and both in cadavers and patients with de Quervain's disease, with no statistically significant differences between those two groups. Presence of intercompartmental fibro-osseous septum is much more common in patients with de Quervain's disease than in cadavers, which may be one of the factors evoking de Quervain's disease. Our results should improve the awareness of anatomical variations in the first dorsal compartment, which in turn should have impact on treatment of de Quervain's disease in clinical practice.

Conflict of interest: None declared

REFERENCES

1. Abdel-Hamid GA, El-Beshbishy RA, Abdel Aal IH. Anatomical variations of the hand extensors. *Folia Morphol.* 2013; 72(3): 249–257, doi: [10.5603/fm.2013.0040](https://doi.org/10.5603/fm.2013.0040), indexed in Pubmed: [24068687](https://pubmed.ncbi.nlm.nih.gov/24068687/).
2. Aktan ZA, Oztürk L, Calli IH. An anatomical study of the first extensor compartment of the wrist. *Kaibogaku Zasshi.* 1998; 73(1): 49–54, indexed in Pubmed: [9538622](https://pubmed.ncbi.nlm.nih.gov/9538622/).
3. Alemohammad AM, Yazaki N, Morris RP, et al. Thumb interphalangeal joint extension by the extensor pollicis

- brevis: association with a subcompartment and de Quervain's disease. *J Hand Surg Am.* 2009; 34(4): 719–723, doi: [10.1016/j.jhsa.2008.12.015](https://doi.org/10.1016/j.jhsa.2008.12.015), indexed in Pubmed: [19345877](https://pubmed.ncbi.nlm.nih.gov/19345877/).
4. Alexander RD, Catalano LW, Barron OA, et al. The extensor pollicis brevis entrapment test in the treatment of de Quervain's disease. *J Hand Surg Am.* 2002; 27(5): 813–816, doi: [10.1053/jhsu.2002.35309](https://doi.org/10.1053/jhsu.2002.35309), indexed in Pubmed: [12239669](https://pubmed.ncbi.nlm.nih.gov/12239669/).
 5. Bahm J, Szabo Z, Foucher G. The anatomy of de Quervain's disease. A study of operative findings. *Int Orthop.* 1995; 19(4): 209–211, doi: [10.1007/BF00185223](https://doi.org/10.1007/BF00185223), indexed in Pubmed: [8557414](https://pubmed.ncbi.nlm.nih.gov/8557414/).
 6. Bernstein DT, Gonzalez MA, Hendrick RG, et al. Impact of septated first dorsal compartments on symptomatic de Quervain disease. *Plast Reconstr Surg.* 2019; 144(2): 389–393, doi: [10.1097/PRS.0000000000005827](https://doi.org/10.1097/PRS.0000000000005827), indexed in Pubmed: [31348348](https://pubmed.ncbi.nlm.nih.gov/31348348/).
 7. Beutel BG, Doscher ME, Melone CP. Prevalence of a septated first dorsal compartment among patients with and without de Quervain tenosynovitis: an in vivo anatomical study. *Hand (NY).* 2020; 15(3): 348–352, doi: [10.1177/1558944718810864](https://doi.org/10.1177/1558944718810864), indexed in Pubmed: [30428712](https://pubmed.ncbi.nlm.nih.gov/30428712/).
 8. Bharambe V, Patel D, Manvikar PR. A study of extensor pollicis longus and brevis and abductor pollicis longus from the perspective of evolution. *J Med Res.* 2017; 3(3): 146–150, doi: [10.31254/jmr.2017.3311](https://doi.org/10.31254/jmr.2017.3311).
 9. Bing JH, Choi SJ, Jung SM, et al. Ultrasound-guided steroid injection for the treatment of de Quervain's disease: an anatomy-based approach. *Skeletal Radiol.* 2018; 47(11): 1483–1490, doi: [10.1007/s00256-018-2958-9](https://doi.org/10.1007/s00256-018-2958-9), indexed in Pubmed: [29730702](https://pubmed.ncbi.nlm.nih.gov/29730702/).
 10. Brunelli GA, Brunelli GR. Anatomy of the extensor pollicis brevis muscle. *J Hand Surg Br.* 1992; 17(3): 267–269, doi: [10.1016/0266-7681\(92\)90112-f](https://doi.org/10.1016/0266-7681(92)90112-f), indexed in Pubmed: [1624857](https://pubmed.ncbi.nlm.nih.gov/1624857/).
 11. Chang CY, Kheterpal AB, Vicentini JR, et al. Variations of anatomy on MRI of the first extensor compartment of the wrist and association with DeQuervain tenosynovitis. *Skeletal Radiol.* 2017; 46(8): 1047–1056, doi: [10.1007/s00256-017-2639-0](https://doi.org/10.1007/s00256-017-2639-0), indexed in Pubmed: [28389821](https://pubmed.ncbi.nlm.nih.gov/28389821/).
 12. Choi SJ, Ahn JH, Lee YJ, et al. de Quervain disease: US identification of anatomic variations in the first extensor compartment with an emphasis on subcompartmentalization. *Radiology.* 2011; 260(2): 480–486, doi: [10.1148/radiol.11102458](https://doi.org/10.1148/radiol.11102458), indexed in Pubmed: [21613443](https://pubmed.ncbi.nlm.nih.gov/21613443/).
 13. D'Antoni AV, Tubbs RS, Patti AC, et al. The critical appraisal tool for anatomical meta-analysis: a framework for critically appraising anatomical meta-analyses. *Clin Anat.* 2022; 35(3): 323–331, doi: [10.1002/ca.23833](https://doi.org/10.1002/ca.23833), indexed in Pubmed: [35015336](https://pubmed.ncbi.nlm.nih.gov/35015336/).
 14. El-Beshbishy RA, Abdel-Hamid GA. Variations of the abductor pollicis longus tendon: an anatomic study. *Folia Morphol.* 2013; 72(2): 161–166, doi: [10.5603/fm.2013.0027](https://doi.org/10.5603/fm.2013.0027), indexed in Pubmed: [23740505](https://pubmed.ncbi.nlm.nih.gov/23740505/).
 15. Gao ZY, Tao H, Xu H, et al. A novel classification of the anatomical variations of the first extensor compartment. *Medicine.* 2017; 96(35): e7875, doi: [10.1097/MD.0000000000007875](https://doi.org/10.1097/MD.0000000000007875), indexed in Pubmed: [28858099](https://pubmed.ncbi.nlm.nih.gov/28858099/).
 16. Giles KW. Anatomical variations affecting the surgery of de Quervain's disease. *J Bone Joint Surg Br.* 1960; 42-B: 352–355, doi: [10.1302/0301-620X.42B2.352](https://doi.org/10.1302/0301-620X.42B2.352), indexed in Pubmed: [13850049](https://pubmed.ncbi.nlm.nih.gov/13850049/).
 17. Gonzalez MH, Sohlberg R, Brown A, et al. The first dorsal extensor compartment: an anatomic study. *J Hand Surg Am.* 1995; 20(4): 657–660, doi: [10.1016/S0363-5023\(05\)80286-2](https://doi.org/10.1016/S0363-5023(05)80286-2), indexed in Pubmed: [7594297](https://pubmed.ncbi.nlm.nih.gov/7594297/).
 18. Gousheh J, Yavari M, Arasteh E. Division of the first dorsal compartment of the hand into two separated canals: rule or exception? *Arch Iran Med.* 2009; 12(1): 52–54, indexed in Pubmed: [19111030](https://pubmed.ncbi.nlm.nih.gov/19111030/).
 19. Güleç A, Türkmen F, Tokar S, et al. Percutaneous release of the first dorsal extensor compartment: a cadaver study. *Plast Reconstr Surg Glob Open.* 2016; 4(10): e1022, doi: [10.1097/GOX.0000000000001022](https://doi.org/10.1097/GOX.0000000000001022), indexed in Pubmed: [27826460](https://pubmed.ncbi.nlm.nih.gov/27826460/).
 20. Gurses IA, Coskun O, Gayretli O, et al. The anatomy of the fibrous and osseous components of the first extensor compartment of the wrist: a cadaveric study. *Surg Radiol Anat.* 2015; 37(7): 773–777, doi: [10.1007/s00276-015-1439-2](https://doi.org/10.1007/s00276-015-1439-2), indexed in Pubmed: [25645546](https://pubmed.ncbi.nlm.nih.gov/25645546/).
 21. Harvey FJ, Harvey PM, Horsley MW. De Quervain's disease: surgical or nonsurgical treatment. *J Hand Surg Am.* 1990; 15(1): 83–87, doi: [10.1016/s0363-5023\(09\)91110-8](https://doi.org/10.1016/s0363-5023(09)91110-8), indexed in Pubmed: [2299173](https://pubmed.ncbi.nlm.nih.gov/2299173/).
 22. Hazani R, Engineer NJ, Cooney D, et al. Anatomic landmarks for the first dorsal compartment. *Eplasty.* 2008; 8: e53, indexed in Pubmed: [19092992](https://pubmed.ncbi.nlm.nih.gov/19092992/).
 23. Higgins JPT, Thomas J, Chandler J. (eds). *Cochrane Handbook for Systematic Reviews of Interventions.* Wiley 2019.
 24. Hoch J, Fritsch H, Lewejohann S. Kongenitale oder erworbene Anlage des separaten Faches für die Sehne des M. extensor pollicis brevis bei der Tendovaginitis stenosans de Quervain? Makroanatomische und fetal-plastinationshistologische Untersuchungen zum 1. Strecksehnenfach. *Ann Anat Anatomischer Anzeiger.* 2004; 186(4): 305–310, doi: [10.1016/s0940-9602\(04\)80045-1](https://doi.org/10.1016/s0940-9602(04)80045-1).
 25. Jackson WT, Viegas SF, Coon TM, et al. Anatomical variations in the first extensor compartment of the wrist. A clinical and anatomical study. *J Bone Joint Surg.* 1986; 68(6): 923–926, doi: [10.2106/00004623-198668060-00016](https://doi.org/10.2106/00004623-198668060-00016).
 26. Kang JW, Park JW, Lee SH, et al. Ultrasound-guided injection for De Quervain's disease: Accuracy and its influenceable anatomical variances in first extensor compartment of fresh cadaver wrists. *J Orthop Sci.* 2017; 22(2): 270–274, doi: [10.1016/j.jos.2016.11.013](https://doi.org/10.1016/j.jos.2016.11.013), indexed in Pubmed: [28209340](https://pubmed.ncbi.nlm.nih.gov/28209340/).
 27. de Keating-Hart E, Touchais S, Kerjean Y, et al. Presence of an intracompartmental septum detected by ultrasound is associated with the failure of ultrasound-guided steroid injection in de Quervain's syndrome. *J Hand Surg Eur Vol.* 2016; 41(2): 212–219, doi: [10.1177/1753193415611414](https://doi.org/10.1177/1753193415611414), indexed in Pubmed: [26497593](https://pubmed.ncbi.nlm.nih.gov/26497593/).
 28. Kim SJ, Lee CH, Khil EK, et al. Can ultrasonography be useful in planning surgery for de quervain tenosynovitis?: a prospective study with emphasis on detection of the superficial radial nerve and dominant pathologic tendon. *J Ultrasound Med.* 2020; 39(8): 1553–1560, doi: [10.1002/jum.15244](https://doi.org/10.1002/jum.15244), indexed in Pubmed: [32045018](https://pubmed.ncbi.nlm.nih.gov/32045018/).
 29. Kulshreshtha R, Patel S, Arya AP, et al. Variations of the extensor pollicis brevis tendon and its insertion: a study of 44 cadaveric hands. *J Hand Surg Eur Vol.* 2007; 32(5):

- 550–553, doi: [10.1016/J.JHSE.2007.04.013](https://doi.org/10.1016/J.JHSE.2007.04.013), indexed in Pubmed: [17950220](https://pubmed.ncbi.nlm.nih.gov/17950220/).
30. Kulthanan T, Chareonwat B. Variations in abductor pollicis longus and extensor pollicis brevis tendons in the Quervain syndrome: a surgical and anatomical study. *Scand J Plast Reconstr Surg Hand Surg.* 2007; 41(1): 36–38, doi: [10.1080/02844310600869720](https://doi.org/10.1080/02844310600869720), indexed in Pubmed: [17484184](https://pubmed.ncbi.nlm.nih.gov/17484184/).
 31. Kutsikovich J, Merrell G. Accuracy of injection into the first dorsal compartment: a cadaveric ultrasound study. *J Hand Surg Am.* 2018; 43(8): 777.e1–777.e5, doi: [10.1016/j.jhsa.2018.01.020](https://doi.org/10.1016/j.jhsa.2018.01.020), indexed in Pubmed: [29478620](https://pubmed.ncbi.nlm.nih.gov/29478620/).
 32. Kutsumi K, Amadio PC, Zhao C, et al. Gliding resistance of the extensor pollicis brevis tendon and abductor pollicis longus tendon within the first dorsal compartment in fixed wrist positions. *J Orthop Res.* 2005; 23(2): 243–248, doi: [10.1016/j.orthres.2004.06.014](https://doi.org/10.1016/j.orthres.2004.06.014), indexed in Pubmed: [15734232](https://pubmed.ncbi.nlm.nih.gov/15734232/).
 33. Kwon BC, Choi SJ, Koh SH, et al. Sonographic Identification of the intracompartmental septum in de Quervain's disease. *Clin Orthop Relat Res.* 2010; 468(8): 2129–2134, doi: [10.1007/s11999-009-1199-6](https://doi.org/10.1007/s11999-009-1199-6), indexed in Pubmed: [20033358](https://pubmed.ncbi.nlm.nih.gov/20033358/).
 34. Leao L. De Quervain's disease; a clinical and anatomical study. *J Bone Joint Surg Am.* 1958; 40-A(5): 1063–1070, indexed in Pubmed: [13587574](https://pubmed.ncbi.nlm.nih.gov/13587574/).
 35. Lee KH, Kang CN, Lee BG, et al. Ultrasonographic evaluation of the first extensor compartment of the wrist in de Quervain's disease. *J Orthop Sci.* 2014; 19(1): 49–54, doi: [10.1007/s00776-013-0481-3](https://doi.org/10.1007/s00776-013-0481-3), indexed in Pubmed: [24132793](https://pubmed.ncbi.nlm.nih.gov/24132793/).
 36. Lee ZH, Stranix JT, Anzai L, et al. Surgical anatomy of the first extensor compartment: a systematic review and comparison of normal cadavers vs. De Quervain syndrome patients. *J Plast Reconstr Aesthet Surg.* 2017; 70(1): 127–131, doi: [10.1016/j.bjps.2016.08.020](https://doi.org/10.1016/j.bjps.2016.08.020), indexed in Pubmed: [27693273](https://pubmed.ncbi.nlm.nih.gov/27693273/).
 37. Leslie BM, Ericson WB, Morehead JR. Incidence of a septum within the first dorsal compartment of the wrist. *J Hand Surg Am.* 1990; 15(1): 88–91, doi: [10.1016/s0363-5023\(09\)91111-x](https://doi.org/10.1016/s0363-5023(09)91111-x), indexed in Pubmed: [2299174](https://pubmed.ncbi.nlm.nih.gov/2299174/).
 38. Leversedge F, Cotterell I, Nickel B, et al. Ultrasonography-guided de Quervain Injection. *J Am Acad Ortho Surg.* 2016; 24(6): 399–404, doi: [10.5435/jaaos-d-15-00753](https://doi.org/10.5435/jaaos-d-15-00753).
 39. López Mendoza FJ, Barón Ramos CX, Gargollo Orvañanos A. Repercusión de la variabilidad anatómica del primer compartimento extensor de la mano en la enfermedad de De Quervain. *Cirugía Plástica Ibero-Latinoamericana.* 2011; 37(3): 289–293, doi: [10.4321/s0376-78922011000300010](https://doi.org/10.4321/s0376-78922011000300010).
 40. Mahakkanukrauh P, Mahakkanukrauh C. Incidence of a septum in the first dorsal compartment and its effects on therapy of de Quervain's disease. *Clin Anat.* 2000; 13(3): 195–198, doi: [10.1002/\(sici\)1098-2353\(2000\)13:3<195::aid-ca6>3.0.co;2-v](https://doi.org/10.1002/(sici)1098-2353(2000)13:3<195::aid-ca6>3.0.co;2-v).
 41. Matzon JL, Graham JG, Lutsky KF, et al. A prospective evaluation of the anatomy of the first dorsal compartment in patients requiring surgery for de Quervain's tenosynovitis. *J Wrist Surg.* 2019; 8(5): 380–383, doi: [10.1055/s-0039-1688700](https://doi.org/10.1055/s-0039-1688700), indexed in Pubmed: [31579546](https://pubmed.ncbi.nlm.nih.gov/31579546/).
 42. McDermott JD, Ilyas AM, Nazarian LN, et al. Ultrasound-guided injections for de Quervain's tenosynovitis. *Clin Orthop Relat Res.* 2012; 470(7): 1925–1931, doi: [10.1007/s11999-012-2369-5](https://doi.org/10.1007/s11999-012-2369-5), indexed in Pubmed: [22552767](https://pubmed.ncbi.nlm.nih.gov/22552767/).
 43. Minamikawa Y, Peimer CA, Cox WL, et al. De Quervain's syndrome: surgical and anatomical studies of the fibroosseous canal. *Orthopedics.* 1991; 14(5): 545–549, doi: [10.3928/0147-7447-19910501-07](https://doi.org/10.3928/0147-7447-19910501-07), indexed in Pubmed: [2062731](https://pubmed.ncbi.nlm.nih.gov/2062731/).
 44. Mirzanli C, Ozturk K, Esenyel CZ, et al. Accuracy of intrasheath injection techniques for de Quervain's disease: a cadaveric study. *J Hand Surg Eur Vol.* 2012; 37(2): 155–160, doi: [10.1177/1753193411409126](https://doi.org/10.1177/1753193411409126), indexed in Pubmed: [21593074](https://pubmed.ncbi.nlm.nih.gov/21593074/).
 45. Motoura H, Shiozaki K, Kawasaki K. Anatomical variations in the tendon sheath of the first compartment. *Anat Sci Int.* 2010; 85(3): 145–151, doi: [10.1007/s12565-009-0070-x](https://doi.org/10.1007/s12565-009-0070-x), indexed in Pubmed: [20039153](https://pubmed.ncbi.nlm.nih.gov/20039153/).
 46. Nagaoka M, Matsuzaki H, Suzuki T. Ultrasonographic examination of de Quervain's disease. *J Orthop Sci.* 2000; 5(2): 96–99, doi: [10.1007/s007760050134](https://doi.org/10.1007/s007760050134), indexed in Pubmed: [10982641](https://pubmed.ncbi.nlm.nih.gov/10982641/).
 47. Nam YS, Doh G, Hong KiY, et al. Anatomical study of the first dorsal extensor compartment for the treatment of de Quervain's disease. *Ann Anat.* 2018; 218: 250–255, doi: [10.1016/j.aanat.2018.04.007](https://doi.org/10.1016/j.aanat.2018.04.007), indexed in Pubmed: [29746921](https://pubmed.ncbi.nlm.nih.gov/29746921/).
 48. Nayak SR, Hussein M, Krishnamurthy A, et al. Variation and clinical significance of extensor pollicis brevis: a study in South Indian cadavers. *Chang Gung Med J.* 2009; 32(6): 600–604, indexed in Pubmed: [20035638](https://pubmed.ncbi.nlm.nih.gov/20035638/).
 49. Oh JK, Messing S, Hyrien O, et al. Effectiveness of corticosteroid injections for treatment of de quervain's tenosynovitis. *Hand.* 2017; 12(4): 357–361, doi: [10.1177/1558944716681976](https://doi.org/10.1177/1558944716681976), indexed in Pubmed: [28644946](https://pubmed.ncbi.nlm.nih.gov/28644946/).
 50. Opreanu RC, Wechter J, Tabbaa H, et al. Anatomic variations of the first extensor compartment and abductor pollicis longus tendon in trapeziometacarpal arthritis. *Hand.* 2010; 5(2): 184–189, doi: [10.1007/s11552-009-9234-3](https://doi.org/10.1007/s11552-009-9234-3), indexed in Pubmed: [19834771](https://pubmed.ncbi.nlm.nih.gov/19834771/).
 51. Oudenaarde van E. Structure and function of the abductor pollicis longus muscle. *J Anat.* 1991; 174: 221–227, indexed in Pubmed: [2032936](https://pubmed.ncbi.nlm.nih.gov/2032936/).
 52. Öztürk K, Dursun A, Kastamoni Y, et al. Anatomical variations of the extensor tendons of the fetal thumb. *Surg Radiol Anat.* 2021; 43(5): 755–762, doi: [10.1007/s00276-020-02611-7](https://doi.org/10.1007/s00276-020-02611-7), indexed in Pubmed: [33170332](https://pubmed.ncbi.nlm.nih.gov/33170332/).
 53. Palatty B, Veeramani R, Manjunath KY. Variations in extensor tendons of the thumb: a cadaveric study. *Indian J Clin Anat Physiol.* 2020; 5(3): 383–388, doi: [10.18231/2394-2126.2018.0089](https://doi.org/10.18231/2394-2126.2018.0089).
 54. Ravi PK, Tewari J, Mishra PR, et al. Variations of extensor pollicis brevis tendon in Indian population: a cadaveric study and review of literature. *J Clin Orthop Trauma.* 2019; 10(2): 278–281, doi: [10.1016/j.jcot.2018.02.008](https://doi.org/10.1016/j.jcot.2018.02.008), indexed in Pubmed: [30828193](https://pubmed.ncbi.nlm.nih.gov/30828193/).
 55. dos Remédios C, Chapnikoff D, Wavreille G, et al. The abductor pollicis longus: relation between innervation, muscle bellies and number of tendinous slips. *Surg Radiol Anat.* 2005; 27(3): 243–248, doi: [10.1007/s00276-004-0286-3](https://doi.org/10.1007/s00276-004-0286-3), indexed in Pubmed: [15549300](https://pubmed.ncbi.nlm.nih.gov/15549300/).

56. Rousset P, Vuillemin-Bodaghi V, Laredo JD, et al. Anatomic variations in the first extensor compartment of the wrist: accuracy of US. *Radiology*. 2010; 257(2): 427–433, doi: [10.1148/radiol.10092265](https://doi.org/10.1148/radiol.10092265), indexed in Pubmed: [20829530](https://pubmed.ncbi.nlm.nih.gov/20829530/).
57. Roy AJ, Roy AN, De C, et al. A cadaveric study of the first dorsal compartment of the wrist and its content tendons: anatomical variations in the Indian population. *J Hand Microsurg*. 2016; 4(2): 55–59, doi: [10.1007/s12593-012-0073-z](https://doi.org/10.1007/s12593-012-0073-z), indexed in Pubmed: [24293951](https://pubmed.ncbi.nlm.nih.gov/24293951/).
58. Sato J, Ishii Y, Noguchi H. Ultrasonographic evaluation of the prevalence of an intracompartamental septum in patients with de Quervain's disease. *Orthopedics*. 2016; 39(2): 112–116, doi: [10.3928/01477447-20160222-05](https://doi.org/10.3928/01477447-20160222-05), indexed in Pubmed: [26913767](https://pubmed.ncbi.nlm.nih.gov/26913767/).
59. Schulz CU, Anetzberger H, Pfahler M, et al. The relation between primary osteoarthritis of the trapeziometacarpal joint and supernumerary slips of the abductor pollicis longus tendon. *J Hand Surg Br*. 2002; 27(3): 238–241, doi: [10.1054/jhsb.2002.0765](https://doi.org/10.1054/jhsb.2002.0765), indexed in Pubmed: [12074609](https://pubmed.ncbi.nlm.nih.gov/12074609/).
60. Shiraishi N, Matsumura G. Anatomical variations of the extensor pollicis brevis tendon and abductor pollicis longus tendon: relation to tenosynovectomy. *Okajimas Folia Anat Jpn*. 2005; 82(1): 25–29, doi: [10.2535/ofaj.82.25](https://doi.org/10.2535/ofaj.82.25), indexed in Pubmed: [15934601](https://pubmed.ncbi.nlm.nih.gov/15934601/).
61. Shiroishi T, Yasunaga H, Ohta K, et al. Clinical significance of first dorsal compartment in de quervain's disease. *Orthop Traumatol*. 2002; 51(3): 570–574, doi: [10.5035/nishiseisai.51.570](https://doi.org/10.5035/nishiseisai.51.570).
62. Stahl S, Vida D, Meisner C, et al. Work related etiology of de Quervain's tenosynovitis: a case-control study with prospectively collected data. *BMC Musculoskelet Disord*. 2015; 16: 126, doi: [10.1186/s12891-015-0579-1](https://doi.org/10.1186/s12891-015-0579-1), indexed in Pubmed: [26018034](https://pubmed.ncbi.nlm.nih.gov/26018034/).
63. Sugiura S, Matsuura Y, Kuniyoshi K, et al. Anatomic study of the first extensor compartment and the relationship between the extensor tendon width and its distal insertion. *Surg Radiol Anat*. 2017; 39(11): 1223–1226, doi: [10.1007/s00276-017-1867-2](https://doi.org/10.1007/s00276-017-1867-2), indexed in Pubmed: [28484860](https://pubmed.ncbi.nlm.nih.gov/28484860/).
64. Sugiura S, Matsuura Y, Suzuki T, et al. Histological assessment of a septum in the first dorsal compartment: a fresh cadaver study. *J Hand Surg Eur Vol*. 2019; 44(8): 805–809, doi: [10.1177/1753193419838204](https://doi.org/10.1177/1753193419838204), indexed in Pubmed: [30917737](https://pubmed.ncbi.nlm.nih.gov/30917737/).
65. Suhani S, Narga N, Kumar N, et al. Multiple tendons for abductor pollicis longus in the first dorsal compartment and variation in their insertion pattern: Anatomical and clinical relevance. *Res J Pharmaceutical*. 2012; 3(4): 755–763.
66. Takahashi Y, Hashizume H, Inoue H, et al. Clinicopathological analysis of de Quervain's disease. *Acta Med Okayama*. 1994; 48(1): 7–15, doi: [10.18926/AMO/31135](https://doi.org/10.18926/AMO/31135), indexed in Pubmed: [8191920](https://pubmed.ncbi.nlm.nih.gov/8191920/).
67. Tripathy SK, Tewari J, Mishra PR. Anatomical variation of abductor pollicis longus in Indian population: a cadaveric study. *Indian J Orthop*. 2015; 49(5): 549–553, doi: [10.4103/0019-5413.164038](https://doi.org/10.4103/0019-5413.164038), indexed in Pubmed: [26538762](https://pubmed.ncbi.nlm.nih.gov/26538762/).
68. Vollala VR. Abductor Pollicis Longus: A Study of 50 South Indian Cadavers. *Firat Tip Dergisi*. 2006; 12(1): 17–19.
69. Weiss AP, Akelman E, Tabatabai M. Treatment of de Quervain's disease. *J Hand Surg Am*. 1994; 19(4): 595–598, doi: [10.1016/0363-5023\(94\)90262-3](https://doi.org/10.1016/0363-5023(94)90262-3), indexed in Pubmed: [7963313](https://pubmed.ncbi.nlm.nih.gov/7963313/).
70. Witt J, Pess G, Gelberman RH. Treatment of de Quervain tenosynovitis. A prospective study of the results of injection of steroids and immobilization in a splint. *J Bone Joint Surg Am*. 1991; 73(2): 219–222, indexed in Pubmed: [1993717](https://pubmed.ncbi.nlm.nih.gov/1993717/).
71. Xu H, Wu JX, Wang Q, et al. Anatomical variations in the first extensor compartment: a cadaver study. *ANZ J Surg*. 2018; 88(9): 913–916, doi: [10.1111/ans.14808](https://doi.org/10.1111/ans.14808), indexed in Pubmed: [30117658](https://pubmed.ncbi.nlm.nih.gov/30117658/).
72. Yuasa K, Kiyoshige Y. Limited surgical treatment of de Quervain's disease: decompression of only the extensor pollicis brevis subcompartment. *J Hand Surg Am*. 1998; 23(5): 840–843, doi: [10.1016/S0363-5023\(98\)80160-3](https://doi.org/10.1016/S0363-5023(98)80160-3), indexed in Pubmed: [9763259](https://pubmed.ncbi.nlm.nih.gov/9763259/).
73. Zingas C, Failla JM, Van Holsbeeck M. Injection accuracy and clinical relief of de Quervain's tendinitis. *J Hand Surg Am*. 1998; 23(1): 89–96, doi: [10.1016/S0363-5023\(98\)80095-6](https://doi.org/10.1016/S0363-5023(98)80095-6), indexed in Pubmed: [9523961](https://pubmed.ncbi.nlm.nih.gov/9523961/).