VIA MEDICA

ORIGINAL ARTICLE

Folia Morphol.
Vol. 81, No. 3, pp. 606–613
DOI: 10.5603/FM.a2021.0057

ISSN 0015–5659
eISSN 1644–3284
journals.viamedica.pl

Morphological examination of the accessory sex glands of the Barki bucks (*Capra hircus*)

M.A.M. Alsafy[1], M.M.A. Abumandour[1], A.A. Karkoura[1], R. El-Bakary[1], M.A. Seif[2], K. Roshdy[3]

[1]*Department of Anatomy and Embryology, Faculty of Veterinary Medicine, Alexandria University, Alexandria, Egypt*
[2]*Department of Anatomy and Embryology, Faculty of Veterinary Medicine, Matrouh University, Matrouch, Egypt*
[3]*Department of Histology and Cytology, Faculty of Veterinary Medicine, Alexandria University, Alexandria, Egypt*

[Received: 2 March 2021; Accepted: 29 April 2021; Early publication date: 25 May 2021]

Background: *The present investigation was prepared to describe the accessory sex glands of the Barki bucks grossly and by light microscopy.*
Materials and methods: *There are four sex glands: ampullary, vesicular, prostate, and bulbourethral. The ampullary gland is an enlargement of the terminal part of the ductus deferens, its glandular part has branched tubuloalveolar glands, and its secretory alveoli lined with a pseudo-stratified epithelium composed of cuboidal to columnar cells. The vesicular gland takes the appearance of a cluster of grapes and the left vesicular gland is enlarged and higher than the right one. The vesicular gland is a lobulated tubuloalveolar gland with wide intralobular space and the gland contain a secretory unit which lined by pseudo-stratified columnar epithelium, and the interlobular ductules lined by the stratified epithelium, while the interlobular duct lined by simple cuboidal epithelium; moreover, the lining epithelium of secretory part consists of tall columnar cells. The prostate gland consists only of the disseminated part and is enclosed by a connective tissue capsule that was thin dorsally, thick laterally, and reduced in thickness ventrally. The prostatic acini are lined by simple cuboidal epithelium.*
Results: *The bulbourethral gland was similar in size to the walnut and surrounded by a capsule and there are interlobular connective tissue septa that divided the gland into lobes and lobules of different sizes. The bulbourethral gland contained secretory units lined by the tall simple columnar epithelium of mucous type with basely located nuclei and eosinophilic cytoplasm contains granular secretion.*
Conclusions: *The gross and microscopic examination of the four accessory sex glands gave valuable information in the future pathology diagnosis of the accessory sex glands of the Barki bucks.* (Folia Morphol 2022; 81, 3: 606–613)

Key words: bucks, sex glands, gross morphology, light microscopy, computed tomography scan

INTRODUCTION

The ruminant anatomy was generally concentrated on the bovine especially ox with limited comparative points to the small ruminants, especially goat. Goat is belonging to the Caprini of the Bovidae family in the sub-order Ruminantia of the order Artiodactyla. The goat is considered an important source of meat, milk, and hair in Egypt. The male goat is a very familiar

Address for correspondence: Prof. M. Alsafy, Department of Anatomy and Embryology, Faculty of Veterinary Medicine, Alexandria University, Abees 10th, Postal code: 22758, Alexandria, Egypt, tel: +201017816600, fax: +20452960450, e-mail: safy73@yahoo.com; mohamed.alsafy@alexu.edu.eg

animal in Egyptian farms. There are about seven to ten goat breeds in Egypt: Zaraibi, Barki (*Sahrawi*), Wahati, Sharkawi, and Black Sinai [14]. The three major breeds in Egypt are: Ossimi, Rahmani, and Barki, which are characterised by fat-tailed, their fleece is coarse wool and they are small to medium in size [14].

The male genital systems have to be sound to ensure successful breeding. Ram and buck breeding soundness examination is important to assess the ability to impregnate females during the breeding season [6].

The purpose of the present work was to describe the anatomical position and appearance of the accessory sex glands as well as the microscopic structure of these glands, as there is little available published information about the accessory sex gland of the Barki (*Sahrawi*) bucks. The study of the accessory sex gland in bucks is very important due to its big role in the fertility rate consideration. Additionally, the obtained data were compared with the previous published anatomical data about the accessory sex glands.

MATERIALS AND METHODS

Animals and ethics

The present work was carried out on eight normal healthy Barki bucks weighing 25–30 kg and the aged between 1 and 2 years. The Barki bucks were collected from the goat farms in the Matrouh government and transported to the Anatomical Laboratory at the Anatomy and Embryology Department, Faculty of Veterinary Medicine, Alexandria University, Egypt.

This study followed the rules for the care and use of animals and was approved by the Animal Welfare and Ethics Committees, Faculty of Veterinary Medicine, Alexandria University, Egypt.

Gross morphology

Four Barki bucks were used in the gross morphological descriptions after their sedation with intramuscular injection of the 2% xylazine HCl (0.2 mg/kg of body weight) and atropine (0.04 mg/kg). Then, these bucks were anesthetised by intravenous injection of ketamine (5 mg/kg). The bucks were injected with heparin (1.000 IU) to obtain well bleeding and prevent the coagulation. Then, they were sacrificed by the well bleeding through the common carotid artery for injection of 10% formalin. The specimens were stored for 2 weeks in formalin 10%. The cadavers were injected via a needle in several sites of the body and on the pelvic cavity using the ordinary preservation solution (10% formalin, 2% phenol, and 1% glycerin).

Computed tomography scans

Two bucks were subjected to computed tomography (CT). After physical examination of animals, they were anesthetised by using the combination of ketamine hydrate 0.5–2 mg/kg of body weight and 2% xylazine HCl 1–3 mg/kg of body weight. The bucks' cadavers were taken freshly to the CT centre immediately and fixed in the sternal recumbence position and then, serially sectioned using the Hitachi CT scanner (CT-W450-10A, Hitachi, Japan) (scanning conditions: 120 KV and 200 MA, the width and level of the window [W/L]: 2000/250) to examine the accessory male sex reproductive glands. The section thickness was 0.5 cm, part interval in the cross-section from the level of the last lumbar to the fourth caudal vertebrae. The CT images photographed were helpful in the identification of the structures situated from the level of the fifth lumbar and the fourth caudal vertebra. To obtain the good resolution images in the bone windows, the CT machine was adapted with 200 Hounsfield units (HU) in the windows width and 1600 HU in the level of the windows. While in the soft tissue, we adapted the apparatus with 30 HU in the width of the window and 290 HU in the level of the windows.

Light microscopy

Two bucks were used for light microscopic examination. The accessory sex glands were removed from the freshly slaughtered male bucks and were put in 10% normal buffer formalin solution and transported to the histological lab for the histological preparation of the slides (cutting and staining) to allow the examination of the slides under the light microscope to know the characteristic points of each gland. Then, the samples were put in 70% alcohol solution. Next, they were rapidly dehydrated through ascending grades of ethyl alcohol series (30, 50, 70, 90, and 100% for two changes) for a half-hour in each. Then, they were cleared by putting in xylene and embedded in paraffin wax. Samples sections of 5 μm were cut by Leica rotatory microtome and mounted on the glass slides. Finally, the paraffin sections were used for ordinary staining by Harris haematoxylin and eosin (H&E) stain. The histological techniques were carried according to Suvarna et al. [38].

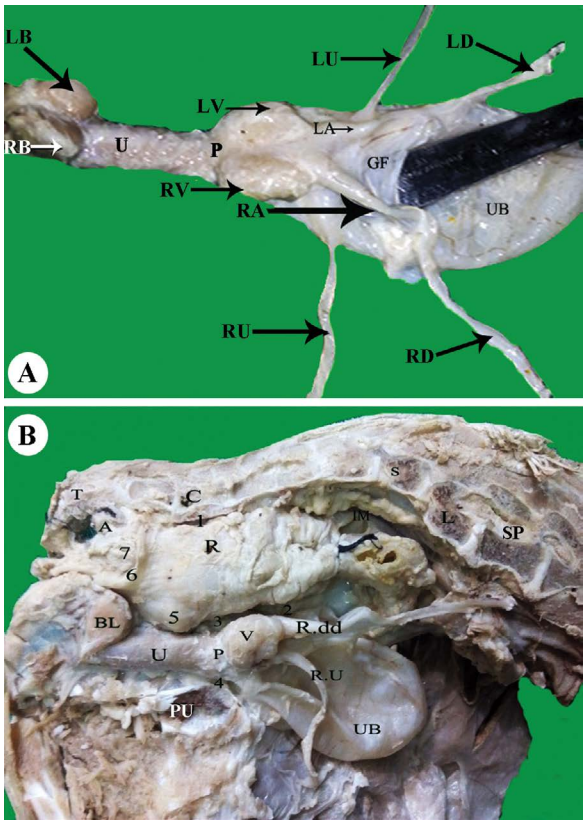

Figure 1. Morphological appearance of the position of the accessory sex reproductive glands of the buck; **A.** Isolated genital organs with the accessory sex reproductive glands of the buck; UB — urinary bladder; LD-RD — left and right ductus deference; GF — genital fold; LU-RU — left and right ureter; LA-RA — ampulla of ductus deference; LV-RV — left and right vesicular gland; P — prostate gland; U — urethra; LB-RB — left and right bulbo urethral gland; **B.** Left side of the pelvic cavity showing the topography of the accessory sex reproductive glands of the buck; 1 — pararectal fossa; 2 — vesicogenital pouch; 3 — rectogenital pouch; 4 — pubovesical pouch; 5 — ampulla recti; 6 — muscle sphincter ani internus; 7 — muscle sphincter ani externus; R — rectum, R.dd — right ampulla of ductus deference; R.U — right ureter; UB — urinary bladder; U — urethra; IM — mesorectum; V — vesicular gland; P — prostate gland; BL — bulbourethral gland; L — lumbar vertebrae; S — sacral vertebrae; C — caudal vertebrae.

The nomenclature used in this study is adapted to Nomina Anatomica Veterinaria [29].

RESULTS

In all examined bucks, there were four accessory sex glands (*Glandulae genitales accessoriae*): the paired ampulla of the ductus deferens (ampullary gland), the paired vesicular gland (*Glandula vesicularis*), the prostate (*Glandula prostatica*), and the paired bulbourethral gland (*Glandula bulbourethralis*). All accessory sex glands were located along the pelvic urethra and their ducts opened and empty their secretion into the urethra.

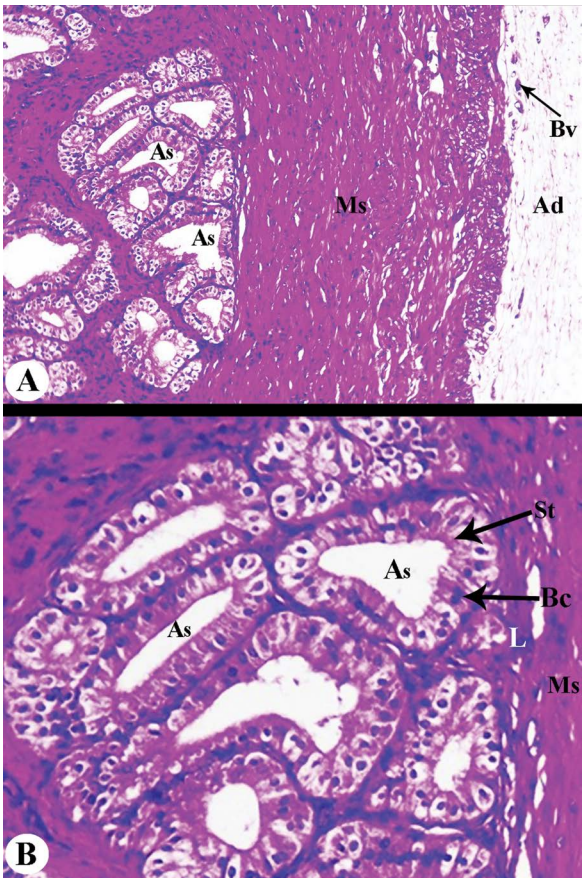

Figure 2. A, B. Micrograph of the ampullary gland of the adult buck showing; As — alveoli; Ms — tunica muscularis; Ad — tunica adventitia; Bv — blood vessels; St — pseudo-stratified epithelium; Bc — basal cell; L — lamina propria; haematoxylin and eosin, ×160.

Ampullary gland (*Glandula ampulla ductus deferentis*)

The ampullary gland (Fig. 1A\LA and RA; Fig. 1B/R.dd; Fig. 6A/4) is a glandular enlargement of the terminal part of the ductus deferens. The length of the ampullary gland reaches 3.5 ± 0.4 cm and the width was 0.5 ± 0.12 cm. The ampullary glands were directed ventrocaudally on the dorsal surface of the urinary bladder and attached by the genital fold (Fig. 1A\GF).

The light microscopic examination showed that the gland (Fig. 2) consisted of the tunica mucosa, tunica muscularis, lamina propria and tunica adventitia, and some blood vessels. The glandular part contained branches of tubuloalveolar glands. The secretory alveoli were lined with a pseudo-stratified epithelium composed of cuboidal to columnar cells with some basal cells.

Vesicular gland (*Glandula vesicularis*)

In all investigated bucks, the paired vesicular gland (Fig. 1A\LV-RV; Fig. 1B/V; Fig. 6A/3) were located on

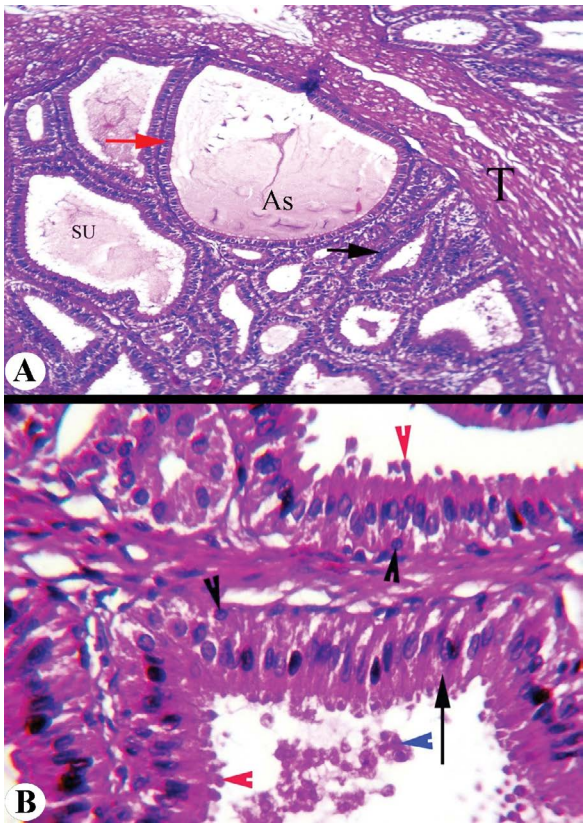

Figure 3. Cross-section micrograph of the vesicular gland of the mature buck showing; **A.** Secretory units (SU) lined by pseudo stratified columnar epithelium, intralobular ductules lined by stratified epithelium (black arrow) and intralobular duct lined by simple cuboidal epithelium (red arrow) with intraluminal eosinophilic secretion (As); haematoxylin and eosin, ×160; **B.** The lining epithelium of secretory part consists of tall columnar cells (arrow), apical blebs of granular end pieces (red arrowheads) and detached blebs in lamina (blue arrowheads), small and spherical basal cells (black arrowheads); haematoxylin and eosin, ×400.

the craniodorsal aspect of the neck of the urinary bladder (*Vesica urinaria*) and laterally to the ampullary glands. It could be identified by its appearance that looks like a cluster of grapes and it is important to note that the left vesicular gland was enlarged and higher than the right one in the same buck.

The light microscopic examination clarified that the vesicular gland (Fig. 3) is a lobulated tubulo-alveolar gland with wide intralobular space or sinuses for storage of a large number of secretions. The gland contained a secretory unit lined by pseudo-stratified columnar epithelium, and the interlobular ductules were lined by the stratified epithelium, while the interlobular duct was lined by simple cuboidal epithelium with intra-luminal eosinophilic secretion. The lining epithelium of the secretory part consisted of tall columnar cells, apical blebs of granular end pieces, and detached blebs in lamina, small and spherical basal cells.

Prostate gland (*Glandula prostatica*)

In all examined bucks, the single prostate gland (Fig. 1/P; Fig. 6B/16) was located close to the junction of the vesicular gland at the pelvic region. It was constituted only from the disseminated part (*pars disseminate*). The pars disseminate surrounded the pelvic urethra which was covered by the urethra masculina.

The light microscopic examination showed that the prostate gland was enclosed by a connective tissue capsule (Fig. 4) that was thin dorsally, thick laterally, and reduced in thickness ventrally. The gland capsule was enveloped by a layer of skeletal muscle (muscle urethralis) that was surrounded by a layer of loose connective tissue trabeculae extending from the capsule and descending into the parenchyma of the gland forming interlobular connective tissue and divided the gland into lobules. The glandular substance consisted of numerous follicles, which opened into the elongated canal. The prostatic acini were lined by simple cuboidal epithelium.

Bulbourethral gland (*Glandula bulbourethralis*)

In all investigated bucks, the paired bulbourethral gland was similar in size to the walnut and located dorsal to the urethra in both sides of it, cranial to the ischial arch (Fig. 1A\LB-RB; Fig. 1B/BL; Fig. 6C/23). It was closely related to the bulb of the penis and in general, it appeared to be covered mostly by the bulbospongiosus muscle. The right and left bulbourethral glands appeared to be nearly equal in size and their shape similar to each other.

The light microscopic examination showed that the bulbourethral gland was surrounded by a white fibrous capsule and there were interlobular connective tissue septa that divided the gland into lobes and lobules of different sizes (Fig. 5). The gland contained secretory units lined by the tall simple columnar epithelium of mucous type with basely located nuclei and eosinophilic cytoplasm contained granular secretion.

DISCUSSION AND CONCLUSIONS

There are four accessory sex glands in most mammalian species: ampullary, seminal vesicle, prostate, and the bulbourethral glands in the Barki bucks as reported in horse [8, 12], bull [7, 12], spotted paca [5], Gracilinanus microtarsus [10], Arabian oryx [13], Elk (*Cervus canadensis*) [22], red deer (*Cervus elaphus*) [36].

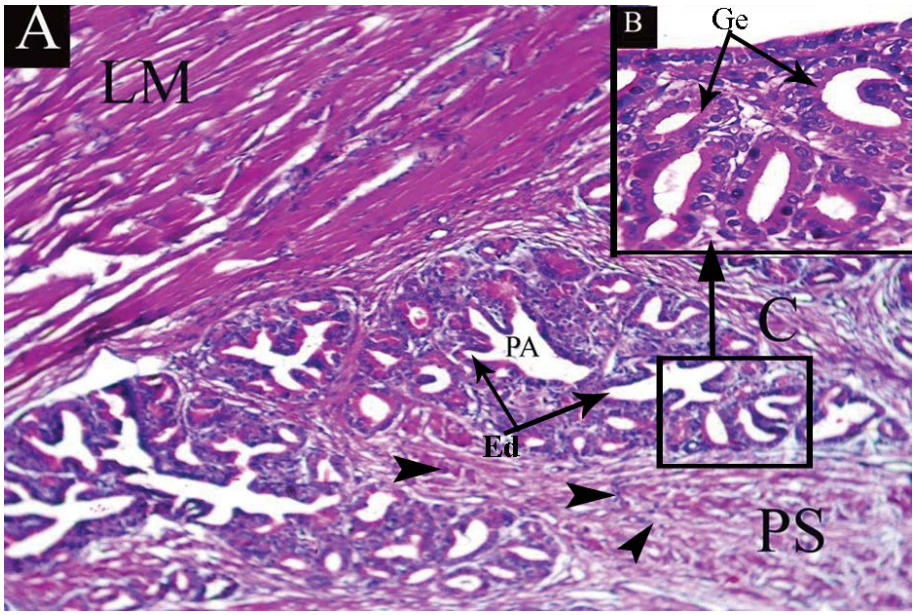

Figure 4. Histological micrograph of the prostate gland (pars dessiminata) from the mature buck; **A.** Lamina muscularis (LM), prostatic acini (PA), surrounded by fibrous capsule (C) and propria submucosa (PS) with smooth muscle bundles (black arrowheads), excretory ducts of the prostate gland (Ed); haematoxylin and eosin, ×160; **B.** Prostatic acini lined by simple cuboidal epithelium with glandular epithelium (Ge); haematoxylin and eosin, ×400.

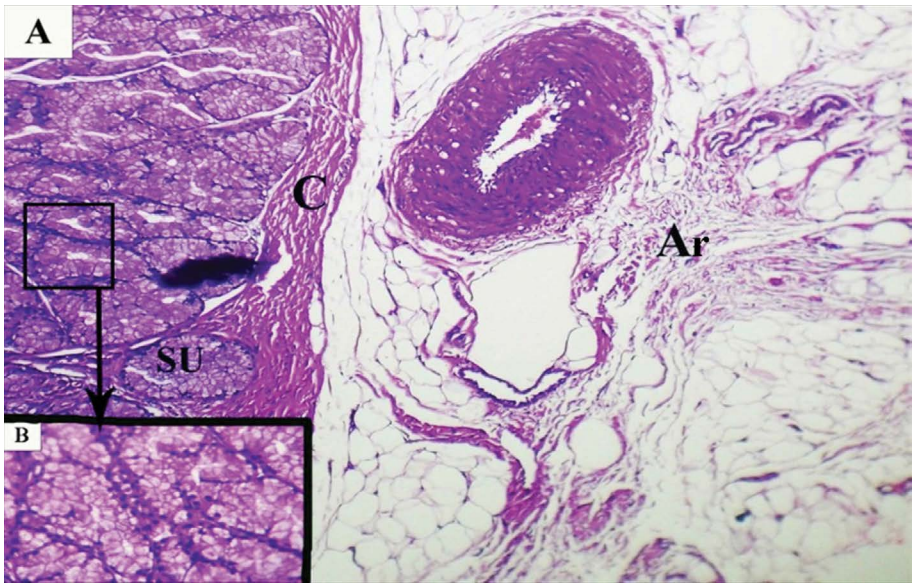

Figure 5. Histological cross section micrograph of the bulbourethral gland of the mature buck; **A.** Adventitia (Ar), capsule (C) and secretory unit (SU); haematoxylin and eosin, ×160; **B.** The lining epithelium of secretory unit is a tall simple columnar epithelium of mucous.

While, the presence of three accessory sex glands was reported in canine (prostate, bulbourethral glands and ampullary gland) [12], canine (prostate, seminal vesicle and ampullary gland) [32], in the pampas deer *Ozotoceros bezoarticus* (prostate, vesicular and the ampullary glands) [34], in the lesser anteater (prostate, seminal vesicle and bulbourethral glands). However, there are two accessory sex glands only, the prostate and vesicular gland, in the capybara [15]. Furthermore, El-Hagri [12] and Budras et al. [7] reported that the accessory sex glands were fully developed only in the bull.

The present investigation reported that the ampullary gland is a glandular enlargement of the terminal part of the ductus deferens, similar result mentioned by some authors [12, 16, 33, 37]. Furthermore, Frans-

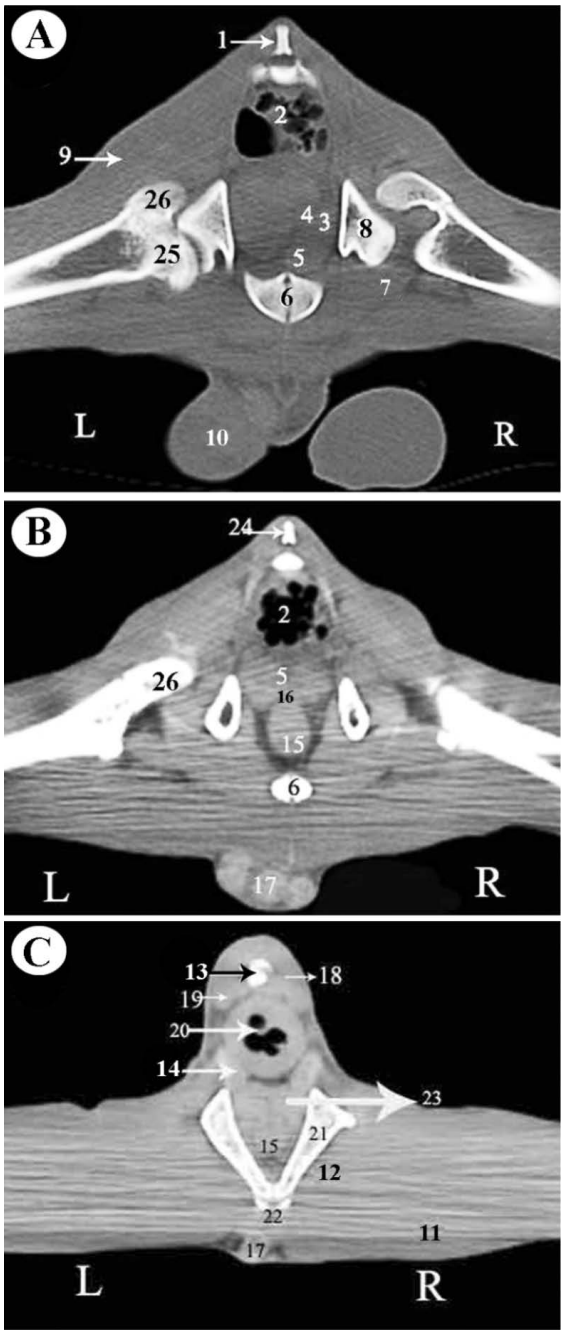

Figure 6. Computed tomography images of the male buck's pelvis; **A.** Transversal computed tomography scan at the level of the 3rd sacral vertebra; **B.** Transversal computed tomography scan at the level of the 5th sacral vertebra; **C.** Transversal computed tomography scan at the level of the 3rd caudal vertebra; 1 — 3rd sacral vertebra; 2 — rectum; 3 — vesicular gland; 4 — ampulla of ductus deference; 5 — neck of urinary bladder; 6 — pubic symphysis; 7 — ilio psoas muscle; 8 — right ilium shaft; 9 — superficial gluteal muscle; 10 — testis; 11 — right adductor muscle; 12 — external obturator muscle; 13 — 3rd caudal vertebra; 14 — muscle sphincter ani internus and externus; 15 — pelvic urethra; 16 — prostata; 17 — penis; 18 — right sacrocaudalis dorsalis lateralis muscle; 19 — right sacrocaudalis ventralis medialis and lateralis muscle; 20 — anal canal; 21 — right ischium; 22 — ischiatic arch; 23 — bulbo urethral gland; 24 — 5th sacral vertebra; 25 — head of femur; 26 — greater trochanter of femur; L — left side; R — right side.

don et al. [16] added that its size has a species variation among animal species; well-developed in stallion, bull and ram but, it is absent in the boar; however, Bacha and Bacha [4] and El-Hagri [12] mentioned that it is ill well-developed in the boar but absent in the tomcat and also do Nascimento Lima et al. [10] reported the absence of this gland in *Gracilinanus microtarsus*. The present histological observation of the ampullary was similar with Trautmann et al. [39] and Wrobel [41] that the gland consists of three layers: the tunica mucosa, tunica muscularis and tunica adventitia.

In all investigated bucks, the paired vesicular gland were located on the craniodorsal aspect of the urinary bladder and it could be easily identified by its appearance which looks like a cluster of grapes and also it's important to note that the left vesicular gland was enlarged and higher than the right one; similar findings were obtained by some authors [3, 12, 19]. The vesicular gland is the largest accessory sex gland in the bull [7, 12] and the spotted paca [5]. However, the vesicular gland was absent in the canines [12], *Gracilinanus microtarsus* [10] and some rodents [2, 20]. In the current histological study, the vesicular gland was a lobulated alveolar gland containing a secretory unit that lined by pseudo-stratified columnar epithelium, and the interlobular ductules were lined by the stratified epithelium, while the interlobular duct was lined by simple cuboidal epithelium; similar findings were obtained by some authors [3, 19, 27]. While it was lined by simple cuboidal epithelium as reported in the spotted paca [5], it was lined by a simple columnar epithelium as observed in Guinea pig [40], rat [35] and giant rat [21, 23].

Morphologically, the prostate gland may be single as present in our study and by some authors [12, 17–19, 26, 32] or paired as noted by Junqueira et al. [24]. In our work, we found that the single prostate gland has only the pars disseminate that is found in the pelvic urethra and surrounded by the urethral masculina; similar findings were obtained by some authors [12, 17, 18, 26, 32]. Pathak et al. [31] reported that there is an additional part named the corpus prostate present in some gaddi goats; however, this corpus prostate is not present in small ruminants in all published anatomical textbooks [11, 12, 18].

There is some variation in the portions of the prostate gland among animals species; the present study with and some other authors [12, 17, 18, 26, 32] noted the presence of only one portion called

disseminate part, while Gofur [19] in the Black Bengal buck mentioned that the single prostate gland has two portions: compact (external) and disseminate (internal) portion. On the other hand, Junqueira et al. [24] in rat noted that the paired prostate gland has a dorsal and ventral part. Also Neuhaus et al. [28] in the Guinea pig noted that the prostate gland has two portions: the large cranial lobe and the smaller caudal lobe. Moreover, Ojasti [30] in the capybara noted that the prostate gland consists of three parts: intermediate, dorsal and lateral lobes.

According to our histological studies, the prostate gland was enclosed by a connective tissue capsule, which was thin dorsally, thick laterally and reduced in thickness ventrally. The capsule was enveloped by a layer of skeletal muscle surrounded by a layer of skeletal muscle, similar to that reported by Gofur [19] and Pathak et al. [31]. In Guinea pig, the prostate is enveloped by a fibrous muscular layer [1] while in the spotted paca [5] this layer consists of smooth muscle fibre, similar to that observed in the prostate gland of the mouse [9, 25]. The present study noted that the prostatic acini were lined by simple cuboidal epithelium while in the spotted paca [5] it is simple columnar epithelium but pseudo-stratified in some regions.

Our study revealed that the paired bulbourethral gland is small in size similar to hazelnut, and lies dorsal to the pelvic urethra and more obvious as the gland surrounded by a white fibrous capsule; similar observations were noted by some authors [3, 7, 16, 19]. In the spotted paca, the bulbourethral gland presented at the terminal part of the rectum and dorsal to the urethra and caudal to the prostate gland [5]. The bulbourethral gland is absent in the canine and present in the feline, as noted by El-Hagri [12] and Bacha and Bacha [4]. The bulbourethral gland is surrounded by striated skeletal muscle, as noted by Borges et al. [5], Gude et al. [21] and Hebel and Stromberg [23]. Our work mentioned that the bulbourethral gland contains secretory units lined by the tall simple columnar epithelium of mucous type. The lining simple columnar epithelium was also noted by Hebel and Stromberg [23]. The bulbourethral gland appears to be covered mostly by the bulbospongiosus muscle and the gland itself is covered by a white fibrous capsule, similar to that noted by Budras et al. [7].

Conflict of interest: None declared

REFERENCES

1. Amiya PSH, Maiti BR. Quantitative studies of the reproductiveorgans of the male bandicoot rat: a common rodent pest. Anat Anzeiger. 1982; 151(5): 483–495.
2. Angulo J, Alvarez M. The genital tract of the male conga hutia, capromys pilorides (say). J Mammal. 1948; 29(3): 277, doi: 10.2307/1375394.
3. Archana P, Katiyar RS, Sharma DN, et al. Gerentological studies on the gross and histomorphology of the vesicular gland of gaddi goat (Copra hircus). Int J Morphol. 2009; 27(1), doi: 10.4067/s0717-95022009000100002.
4. Bacha Jr, Bacha LM. Color atlas of veterinary histology. John Wiley & Sons 2012.
5. Borges EM, Branco É, de Lima AR, et al. Morphology of accessory genital glands of spotted paca (Agouti paca Linnaeus, 1766). Anim Reprod Sci. 2014; 145(1-2): 75–80, doi: 10.1016/j.anireprosci.2013.12.014, indexed in Pubmed: 24461579.
6. Boukhliq R, El Al, Tibary A. Gross anatomy and ultrasonographic examination of the reproductive organs in rams and bucks. Revue Marocaine des Sciences Agronomiques et Vétérinaires. 2018; 6(2).
7. Budras KD, Habel RE, Wunsche A, Buda S. Bovine anatomy: An illustrated text. 1st ed. Schlutersche GmbH & Co. KG, Verlag und Druckerei, Hannover 2003: 289–291.
8. Budras KD, Sack WO, Rock S, Horowitz A, Berg R. Anatomy of the Horse, 6th ed. Schluetersche, Germany 2012.
9. Cagnon VH, Camargo AM, Rosa RM, et al. Ultrastructural study of the ventral lobe of the prostate of mice with streptozotocin induced diabetes (C57BL/6J). Tissue Cell. 2000; 32(4): 275–283, doi: 10.1054/tice.2000.0123, indexed in Pubmed: 11145010.
10. do Nascimento Lima JM, Santos AC, Viana DC, et al. Estudo morfológico dos órgãos genitais masculinos em Gracilinanus microtarsus. BJVRAS. 2013; 50(6): 447–456.
11. Dyce KM, Sack WO, Wensing CJG. Text book of Veterinary anatomy. WB Saunders Company, Philadelphia, London and Toronto 2010.
12. El-Hagri MAA. Splanchnology of Domestic Animals. 1st public organization for books and scientific publications, Giza: Cairo University Press. Springer, Berlin Heidelberg 1967: 23–30.
13. Eljarah A, Al-Zghoul MB, Jawasreh K, et al. Characterization of male reproductive anatomy of the endangered Arabian oryx (Oryx leucoryx). Theriogenology. 2012; 78(1): 159–164, doi: 10.1016/j.theriogenology.2012.01.032, indexed in Pubmed: 22444562.
14. Elshennawy M. Sheep development program in Egypt. In: Gabiña D. (ed.). Strategies for sheep and goat breeding (Cahiers Options Méditerraéennes; n. 11). CIHEAM, Zaragoza 1995: 27–32.
15. Fernandez D, Ferraz R, Melo A, et al. Análise histológica das glândulas uretrais da capivara (Hydrochoerus hydrochaeris). Pesq Vet Bras. 2010; 30(4): 373–377, doi: 10.1590/s0100-736x2010000400015.
16. Frandson RD, Wilke WL, Fails AD. Anatomy and physiology of farm animals. John Wiley & Sons 2009.
17. Garrett PD. Guide to ruminant anatomy based on the dissection of the goat. Low State University Press, AMES 1988.

18. Getty R. The Anatomy of the Domestic Animals. Vol. 1, 5th Ed. WB Saunders Company, Philadelphia, USA 1975.
19. Gofur M. Anatomy and histomorphometry of accessory reproductive glands of the Black Bengal buck. Eur J Anat. 2015; 19(2): 171–178.
20. Gottreich A, Hammel I, Yogev L, et al. Quantitative microscopic changes in the mole rat's accessory sex organs during an annual cycle. Anat Rec. 1996; 246(2): 231–237, doi: 10.1002/(SICI)1097-0185(199610)246:2<231::AID-AR10>3.0.CO;2-P, indexed in Pubmed: 8888965.
21. Gude WD, Cosgrove GE, Hirsch GP. Histological atlas of the laboratory mouse. Springer 1982: 17–19.
22. Haigh J. Reproductive anatomy and physiology of male wapiti and red deer. Current Therapy in Large Animal Theriogenology. 2nd Ed. Saunders Elsevier Inc, St. Louis, Missouri 2007: 932–936.
23. Hebel R, Stromberg MW. Anatomy and embryology of the laboratory rat. BioMed Verlag 1986.
24. Junqueira LCU, Martins EO, Luiz Carlos Uchôa Junqueira EO. Atlas de anatomia microscópica do rato. 1947.
25. Kawamura H, Nonogaki T, Yoshikawa K, et al. Morphological changes in mouse accessory sex glands following neonatal estrogen treatment. Ann Anat. 2000; 182(3): 269–274, doi: 10.1016/S0940-9602(00)80034-5, indexed in Pubmed: 10836100.
26. Kundu P. Anatomical studies on the accessory male sex glands (gross and microscopic) of the Indian goat (Jamunapari and cross Jamunapari). IJAH 1980: 151–153.
27. Menezes DJ, Assis Neto AC, Oliveira MF, et al. Morphology of the male agouti accessory genital glands (Dasyprocta prymnolopha Wagler, 1831). Pesq Vet Bras. 2010; 30(9): 793–797, doi: 10.1590/s0100-736x2010000900014.
28. Neuhaus J, Dorschner W, Mondry J, et al. Comparative anatomy of the male guinea-pig and human lower urinary tract: histomorphology and three-dimensional reconstruction. Anat Histol Embryol. 2001; 30(3): 185–192, indexed in Pubmed: 11447945.
29. Nomina Anatomica Veterinaria. 5th edition (revised version). Prepared by the International Committee on Veterinary Gross Anatomical Nomenclature (I.C.V.G.A.N.) and authorized by the General Assembly of the World Association of Veterinary Anatomists (W.A.V.A.) Knoxville, TN (U.S.A.) 2003 Published by the Editorial Committee Hannover (Germany), Columbia, MO (U.S.A.), Ghent (Belgium), Sapporo (Japan). Springer 2012.
30. Ojasti J. Estudio biológico del chigüire o capibara. Fondo Nacional de Investigaciones Agropecuarias Caracas 1973.
31. Pathak A, Katiyar RS, Sharma DN, et al. Gross Anatomical, Histological and Histochemical Studies on the Postnatal Development of the Prostate Gland of Gaddi Goat. Int J Morphol. 2012; 30(2): 731–739, doi: 10.4067/s0717-95022012000200063.
32. Pérez W, Vazquez N, Ungerfeld R. Gross anatomy of the male genital organs of the pampas deer (Ozotoceros bezoarticus, Linnaeus 1758). Anat Sci Int. 2013; 88(3): 123–129, doi: 10.1007/s12565-013-0171-4, indexed in Pubmed: 23381482.
33. Raghavan D. Anatomy the of ox. Indian Council of Agricultural Research, New Delhi 1964.
34. Rossi LF, Luaces JP, Aldana Marcos HJ, et al. Anatomy and histology of the male reproductive tract and spermatogenesis fine structure in the lesser anteater (Tamandua tetradactyla, Myrmecophagidae, Xenarthra): morphological evidences of reproductive functions. Anat Histol Embryol. 2013; 42(4): 247–256, doi: 10.1111/ahe.12008, indexed in Pubmed: 23072214.
35. Sprando RL, Collins TF, Black TN, et al. Light microscopic observations on the reproductive tract of the male sand rat, Psammomys obesus. Tissue Cell. 1999; 31(1): 99–115, doi: 10.1054/tice.1999.0003, indexed in Pubmed: 10368991.
36. Stewart D. Male genitalia of red deer (Cervus elaphus). NZVJ. 1983; 31(7): 122.
37. Suri S, Sudhakar L, Bhardwaj R. Seasonal variation in the histomorphology and histochemistry of ampulla of vas deferens of gaddi goat and gaddi sheep. Int J Morphol. 2008; 26(1), doi: 10.4067/s0717-95022008000100022.
38. Suvarna SK, Layton C, Bancroft JD. Bancroft's Theory and Practice of Histological Techniques, Expert Consult: Online and Print, 7: Bancroft's Theory and Practice of Histological Techniques. Elsevier, Churchill Livingstone 2013.
39. Trautmann A, Fiebiger J, Habel RE, Biberstein EL. Fundamentals of the histology of domestic animals. Comstock 1957.
40. Wagner JE. The biology of the guinea pig. Academic Press 2014.
41. Wrobel K. Male reproductive system. In textbook of veterinary histology. Dellmann H (ed.). DP Lea & Febiger, Philadelphia 1993.