


# The terminal branch of the posterior interosseous nerve: an anatomic and histologic study

T. Bonczar<sup>1</sup> , J.A. Walocha<sup>1</sup>, M. Bonczar<sup>2</sup>, E. Mizia<sup>1</sup>, M. Koziej<sup>1</sup>, P. Piekos<sup>1</sup>, M. Kujdowicz<sup>3</sup>

<sup>1</sup>Department of Anatomy, Jagiellonian University Medical College, Krakow, Poland

<sup>2</sup>Intermed Medical Clinic, Zabierzow, Poland

<sup>3</sup>Department of Pathology, Jagiellonian University Medical College, Krakow, Poland

[Received: 17 March 2020; Accepted: 2 April 2020]

**Background:** The aim of this study was to evaluate the terminal branch of the posterior interosseous nerve (PIN) by anatomically and histologically assessing the number, dimension, and area of its individual fascicles, by determining the dimension and area of the whole nerve itself, and by calculating the nerve density ratio (ratio of the sum of the areas of individual fascicles to the area of the whole nerve) of the terminal branch of the PIN.

**Materials and methods:** Twenty-eight terminal branches of the PIN nerve samples were collected from patients undergoing partial denervation of the wrist. The nerve samples were fixed in 10% buffered formalin and stained with haematoxylin and eosin to visualise their nerve bundles. Quantitative analysis of individual fascicles and the whole nerve itself were carried out.

**Results:** Ten nerve samples (35.7%) had one single fascicle (group 1) while the remaining 18 nerve samples (64.3%) contained 2–9 fascicles (group 2). The difference in the sum of the areas of individual fascicles between the two groups did not constitute a statistical difference. Statistically significant between-group differences ( $p < 0.05$ ) were seen in the area of whole nerve, the ratio of fascicle area to the nerve cross-sectional area and the cross-section maximum nerve length and width.

**Conclusions:** The number of nerve fascicles in the terminal branch of the PIN does not affect the overall size of the nerve. The majority of the volume of multi-fascicle nerves, therefore, primarily consists of the internal perineurium. However, due to the low number of nerves, this question cannot be clearly answered. This sets a further direction for further research on a larger group. (Folia Morphol 2021; 80, 1: 76–80)

**Key words:** terminal branch of the posterior interosseous nerve, wrist denervation, posterior interosseous nerve fascicles, nerve graft

## INTRODUCTION

The posterior interosseous nerve (PIN) is one of many nerves that innervate the dorsal wrist [2, 10, 11, 13–15, 22]. The PIN is always excised for both partial and complete wrist denervation as a palliative

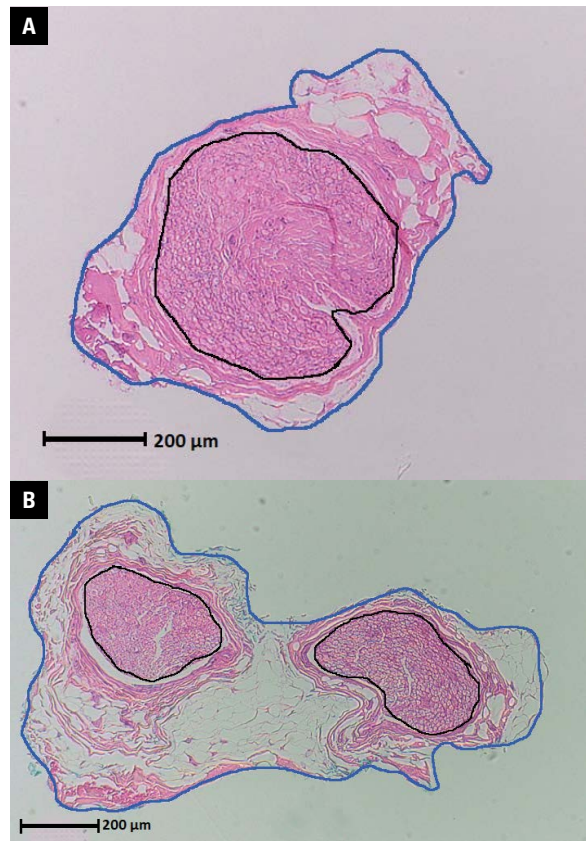
method of treatment of a variety of wrist pathologies [5, 11]. Due to its consistent anatomical location and dimensions, accessibility, limited functional deficit after excision [19], and adequate length for reanastomosis, the PIN can be used as a donor graft for digital

nerves injuries [1, 4, 9, 17, 18]. A recent publication has described the technique of thumb digital nerve reconstruction after the excision of a neuroma utilising an arterialised PIN graft [12]. The assessment of the usefulness of PIN as a nerve graft was based on the PIN's similar thickness to that of digital nerves. The purpose of this study was to accurately assess the structure of the terminal branches of PIN.

## MATERIALS AND METHODS

The study material consisted of 28 PIN collected from patients treated for wrist pain who underwent partial denervation of the wrist between January 2015 and September 2016. The cause of wrist pain in the studied patient population was either due to worsening of distal PIN syndrome, degenerative changes after a history of injury, progressing Kienböck's disease, and finally a long course of inflammatory changes. In some cases, the PIN was excised to prevent pain after ligamentous reconstruction of the wrist. Before every wrist denervation, all patients with a diagnosis of distal PIN syndrome had preoperative diagnostics of the PIN performed with ultrasound.

All patients signed a written consent for a PIN neurectomy and to participate in this study. The design of this study was approved by our Regional Ethical Review Board. Intraoperative photographs were taken for documentation. All operations were carried out by the same surgeon who is experienced in wrist surgery, under regional anaesthesia with 3.5× optical magnification. The longitudinal incision was cut 1 cm ulnar to Lister's tubercle. The extensor retinaculum was opened and the PIN was found proximal to or in the floor of the 4<sup>th</sup> dorsal compartment. The samples were then fixed in 10% buffered formalin and stayed fixed for 14 days. Then each sample underwent dehydration and paraffin embedding procedures. The paraffin cubes were cut with a microtome into 4 µm thick sections and stained with haematoxylin and eosin to visualise the nerve bundles. Quantitative analysis of individual fascicles and the whole nerve itself were carried out using the Olympus BX43 microscope. Photographic documentation was achieved using an Olympus SC-100 camera. The photographs were then analysed using Image J. The number of fascicles in each nerve, the surface area of each fascicle, and the thickness of the perineurium of each fascicle were evaluated. The surface area of the fascicle was calculated with the help of the Image J program using a variable scale of



**Figure 1.** Specimen with single fascicle (A) and two fascicles (B) — the black line surrounding the fascicle and the dark blue line around the whole nerve.

enlargement through a computer introduced fascicle contour (Fig. 1). Next the diameter of the each fascicle was measured. Finally, the longitudinal dimensions, transverse dimensions, and the cross-sectional area of the entire nerve were calculated and results of the measurements were recorded.

## Statistical analysis

The data was presented as percentages, mean values with corresponding standard deviations or median with quartiles. The Shapiro-Wilk test was used to determine if the quantitative data was normally distributed. The Student's t-tests and the Mann-Whitney U tests for statistical comparisons were additionally used. Statistical analyses were performed with STATISTICA v13.1 (StatSoft Inc., Tulsa, OK, USA). A p-value of less than 0.05 was considered to be statistically significant.

## RESULTS

The PIN was harvested from 28 patients — 15 males (53.6%) and 13 females (46.4%). Partial

**Table 1.** Causes of posterior interosseous nerve (PIN) excision

Cause of PIN neurectomy	Amount	Percentage
Dorsal PIN syndrome	13	46.4%
SLAC, SNAC	7	25%
SL reconstruction	4	14.3%
Kienböck's disease	3	10.7%
Rheumatoid arthritis	1	3.6%

SL — scapholunate; SLAC — scapholunate advanced collapse; SNAC — scaphoid non-union advanced collapse

denervation of the wrist was performed on the right wrist in 21 (75%) cases, on the left wrist in 7 (25%) cases, and in the dominant hand of the patient in 21 (75%) cases. The mean age of patients was  $36.2 \pm 15.3$  years (range 17–76 years). The causes of PIN excision are shown in Table 1.

Ten nerve samples (35.7%) had one single fascicle (group 1) while the remaining 18 nerve samples (64.3%) contained 2–9 fascicles (group 2). The number of multi-fascicle nerves was as follows: two-fascicles — 4, three-fascicle — 3, four-fascicle — 5, five-fascicle — 1, six-fascicle — 3 and eight and nine-fascicle nerves — 1, respectively. The mean values of selected parameters in mono-fascicles (group 1) and multi-fascicles nerves (group 2) are shown in Table 2. No statistical difference was found between the genders of the patients, between the sizes of the nerves, and between the numbers of fascicles. There

was no correlation between the age and the size of both the nerve and its fascicles. The sum of the areas of the individual fascicles in the single fascicle nerves (group 1) did not differ from the sum of the areas of the individual fascicles in the multi-fascicles nerves (group 2) ( $p = 0.15$ ). However, statistically significant differences ( $p < 0.05$ ) were seen between areas of whole nerve, that was larger in multi fascicles nerves (group 2). Percentage of fascicles to the nerve surface was significantly higher in the mono-fascicle nerves (group 1) than in the multi-fascicles group ( $p = 0.002$ ).

The average nerve density ratio (ratio of the sum of the areas individual fascicles to the area of the whole nerve) was 25.2%. The average sum of the areas of individual fascicles, the cross-sectional area of the whole nerve and nerve density ratio with standard deviation are given in Table 3.

## DISCUSSION

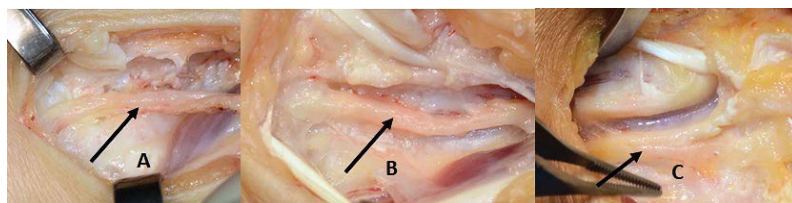
Many publications have shown similarities in the size [3, 6, 8, 21] and in the nerve density [17] of the PIN compared to digital nerves. However, to the knowledge of the authors, this is the first study that describes the anatomical structure of the PIN, taking into account the relationship between the size and number of individual fascicles to the size of the whole nerve. Reissis et al. (1992) [17] compared the usefulness of the PIN as a donor for digital nerve grafts to

**Table 2.** The mean values of selected parameters in mono-fascicles (group 1) and multi-fascicles nerves (group 2)

Parameter	Group	Number	Average	Median	Minimum	Maximum	Bottom quartile	Upper quartile	Standard deviation
Summed area of fascicles [mm <sup>2</sup> ]	1	10	0.19	0.19	0.12	0.27	0.16	0.21	0.05
Area of whole nerve [mm <sup>2</sup> ]	1	10	0.82	0.5	0.23	3.03	0.3	0.97	0.84
Percentage of fascicles to the nerve surface	1	10	36.1	38.2	6.3	69.6	27.8	45.2	17.15
Summed perineurium size [mm]	1	10	0.04	0.04	0.01	0.08	0.03	0.04	0.02
Summed area of fascicles [mm <sup>2</sup> ]	2	18	0.22	0.15	0.01	1.14	0.11	0.19	0.23
Area of whole nerve [mm <sup>2</sup> ]	2	18	3.20	1.55	0.18	10.64	0.72	5.32	3.28
Percentage of fascicles to the nerve surface	2	18	13.41	9.85	0.18	50	2.1	17.8	13.25
Summed perineurium size [mm]	2	18	0.1	0.1	0.04	0.3	0.06	0.1	0.07

**Table 3.** Measurements of 28 posterior interosseous nerve harvested during wrist reconstructive procedures or partial wrist denervation

Parameter	Number	Average	Median	Minimum	Maximum	Lower quartile	Upper quartile	Standard deviation
Summed area of fascicles [mm <sup>2</sup> ]	28	0.2	0.15	0.002	1.14	0.12	0.2	0.21
Area of whole nerve [mm <sup>2</sup> ]	28	2.36	0.88	0.18	10.64	0.52	2.98	2.89
Nerve density ratio [%]	28	21	17	1	68	6	34	18



**Figure 2.** Intraoperative photograph of the posterior interosseous nerve before excision. All nerves had similar dimensions regardless of their quantity of fascicles; **A.** Specimen no. 1 with 5 fascicles; **B.** Specimen no. 2 with 3 fascicles; **C.** Specimen no. 5 with 1 fascicle.

15 digital nerves in a microscopic study of 18 fresh terminal branches of the PIN. They defined the nerve density ratio of the PIN as the ratio of the density of neuronal tissue to the density of connective tissue. Their mean nerve density ratio was 90% which ranged from 88–94%. In this study, the results were different and the nerve density ratio, defined as the ratio of the sum of the areas of individual fascicles to the area of the whole nerve, had a mean of only 21% and ranged from 1.0–65%. It is difficult to explain such differences in this study and the study of Reissis et al. (1992) [17], but after using high microscopic magnification it was possible to measure each fascicle in more detail in this study. In addition, the nerves used for the study came from patients with wrist pathology and possible PIN irritation. Ultrasound has shown that nerve irritation causes hypoechoic swollen, mainly of connective tissue [7, 16]. Chevrollier et al. (2014) [3], in a retrospective single-centre study, evaluated emergent nerve grafting for proper palmar digital nerve defects [9]. However, the results of Chevrollier et al. (2014) [3] cannot be compared to the PIN measurements in this study, because of the 12 analysed cases of digital nerve defects, only one patient had the PIN used as a graft. Waters and Schwartz (1993) [20] showed the presence of nerves with a single fascicle in 15 cases (58%) after evaluating 26 PIN using a macroscopic examination at 3.5× magnification. With the use of microdissection without microscopic nerve evaluation, Waters and Schwartz (1993) [20] were able to show the presence of 1 to 5 (average 2) fascicles in the collected nerve samples. The data collected in this studied using high microscopic magnification and appropriate staining has shown that 64.3% of the nerve samples were multi-fascicle nerves. These results differ from previous studies.

This does not mean, however, that multi-fascicle nerves had a larger surface area due to their number of fascicles. On the contrary, the more fascicles the nerve contained, the smaller the fascicles measured. The nerves with more fascicles usually contained one

bigger fascicle with the rest being very small. In these nerves, the majority of the volume, therefore, primarily consisted of the internal perineurium.

## CONCLUSIONS

During surgery, it is impossible to quantitatively assess the PIN after it has been harvested as a nerve graft. Nerves with differing numbers of fascicles are similar in external dimensions (Fig. 2). However, it is crucial to highlight that proper PIN dimensions (the ratio of the nerve tissue to the area of the entire nerve) does not translate to good nerve quality by meaning the nerve density ratio. The number of nerve fascicles in the terminal branch of the PIN does not affect the overall size of the nerve. The majority of the volume of multi-fascicle nerves, therefore, primarily consists of the internal perineurium. However, due to the low number of nerves, this question cannot be clearly answered. This sets a further direction for further research on a larger group.

## REFERENCES

1. Badran H. Digital nerve grafts for insensitve finger tips of thumb and index fingers. *Plastic Reconstr Surg.* 1997; 99(1): 280, doi: [10.1097/00006534-199701000-00081](https://doi.org/10.1097/00006534-199701000-00081).
2. Bonczar T, Walocha JA, Bonczar M, et al. Assessing the innervation of the dorsal wrist capsule using modified Sihler's staining. *Folia Morphol.* 2020 [Epub ahead of print], doi: [10.5603/FM.a2020.0027](https://doi.org/10.5603/FM.a2020.0027), indexed in Pubmed: [32159843](https://pubmed.ncbi.nlm.nih.gov/32159843/).
3. Chevrollier J, Pedoutour B, Dap F, et al. Evaluation of emergency nerve grafting for proper palmar digital nerve defects: a retrospective single centre study. *Orthop Traumatol Surg Res.* 2014; 100(6): 605–610, doi: [10.1016/j.otsr.2014.05.018](https://doi.org/10.1016/j.otsr.2014.05.018), indexed in Pubmed: [25155205](https://pubmed.ncbi.nlm.nih.gov/25155205/).
4. Chong J. Digital nerve grafts with the lateral antebrachial cutaneous nerve. *Plastic Reconstr Surg.* 1977; 59(6): 875, doi: [10.1097/00006534-197706000-00063](https://doi.org/10.1097/00006534-197706000-00063).
5. Dellon AL. Partial dorsal wrist denervation: resection of the distal posterior interosseous nerve. *J Hand Surg Am.* 1985; 10(4): 527–533, doi: [10.1016/s0363-5023\(85\)80077-0](https://doi.org/10.1016/s0363-5023(85)80077-0), indexed in Pubmed: [4020064](https://pubmed.ncbi.nlm.nih.gov/4020064/).
6. Dellon A, Seif S. Anatomic dissections relating the posterior interosseous nerve to the carpus, and the etiology of dorsal wrist ganglion pain. *J Hand Surg.* 1978; 3(4): 326–332, doi: [10.1016/s0363-5023\(78\)80032-x](https://doi.org/10.1016/s0363-5023(78)80032-x).

7. Djurdjevic T, Loizides A, Löscher W, et al. High resolution ultrasound in posterior interosseous nerve syndrome. *Muscle Nerve*. 2014; 49(1): 35–39, doi: [10.1002/mus.23867](https://doi.org/10.1002/mus.23867), indexed in Pubmed: [23559033](https://pubmed.ncbi.nlm.nih.gov/23559033/).
8. Elgafy H, Ebraheim NA, Rezcallah AT, et al. Posterior interosseous nerve terminal branches. *Clin Orthop Relat Res*. 2000(376): 242–251, doi: [10.1097/00003086-200007000-00033](https://doi.org/10.1097/00003086-200007000-00033), indexed in Pubmed: [10906882](https://pubmed.ncbi.nlm.nih.gov/10906882/).
9. Elgafy H, Ebraheim NA, Yeasting RA. The anatomy of the posterior interosseous nerve as a graft. *J Hand Surg Am*. 2000; 25(5): 930–935, doi: [10.1053/jhsu.2000.16359](https://doi.org/10.1053/jhsu.2000.16359), indexed in Pubmed: [11040308](https://pubmed.ncbi.nlm.nih.gov/11040308/).
10. Ferreres A, Suso S, Ordi J, et al. Wrist denervation. *J Hand Surg*. 2016; 20(6): 761–768, doi: [10.1016/s0266-7681\(95\)80043-3](https://doi.org/10.1016/s0266-7681(95)80043-3).
11. Ferreres A, Foucher G, Suso S. Extensive denervation of the wrist. *Tech Hand Up Extrem Surg*. 2002; 6(1): 36–41, doi: [10.1097/00130911-200203000-00007](https://doi.org/10.1097/00130911-200203000-00007), indexed in Pubmed: [16520631](https://pubmed.ncbi.nlm.nih.gov/16520631/).
12. Foo A, Martin-Playa P, Sebastin Muttath SJ. Arterialized posterior interosseous nerve graft for digital neuroma. *Tech Hand Up Extrem Surg*. 2019; 23(4): 152–154, doi: [10.1097/BTH.0000000000000240](https://doi.org/10.1097/BTH.0000000000000240), indexed in Pubmed: [31157733](https://pubmed.ncbi.nlm.nih.gov/31157733/).
13. Fukumoto K, Kojima T, Kinoshita Y, et al. An anatomic study of the innervation of the wrist joint and Wilhelm's technique for denervation. *J Hand Surg*. 1993; 18(3): 484–489, doi: [10.1016/0363-5023\(93\)90096-l](https://doi.org/10.1016/0363-5023(93)90096-l).
14. Gregory T, Goutard M, Gregory J, et al. A cadaveric study of the posterior interosseous nerve and its branches at the level of the distal radius. *J Hand Surg Global Online*. 2019; 1(2): 70–73, doi: [10.1016/j.jhsg.2019.01.001](https://doi.org/10.1016/j.jhsg.2019.01.001).
15. Hofmeister EP, Moran SL, Shin AY. Anterior and posterior interosseous neurectomy for the treatment of chronic dynamic instability of the wrist. *Hand*. 2006; 1(2): 63–70, doi: [10.1007/s11552-006-9003-5](https://doi.org/10.1007/s11552-006-9003-5), indexed in Pubmed: [18780027](https://pubmed.ncbi.nlm.nih.gov/18780027/).
16. Kim Y, Ha DH, Lee SM. Ultrasonographic findings of posterior interosseous nerve syndrome. *Ultrasonography*. 2017; 36(4): 363–369, doi: [10.14366/usb.17007](https://doi.org/10.14366/usb.17007), indexed in Pubmed: [28494524](https://pubmed.ncbi.nlm.nih.gov/28494524/).
17. Reissis N, Stirrat A, Manek S, et al. The terminal branch of posterior interosseous nerve: a useful donor for digital nerve grafting. *J Hand Surg*. 1992; 17(6): 638–640, doi: [10.1016/0266-7681\(92\)90190-d](https://doi.org/10.1016/0266-7681(92)90190-d).
18. Stang F, Stollwerck P, Prommersberger KJ, et al. Posterior interosseous nerve vs. medial cutaneous nerve of the forearm: differences in digital nerve reconstruction. *Arch Orthop Trauma Surg*. 2013; 133(6): 875–880, doi: [10.1007/s00402-013-1731-8](https://doi.org/10.1007/s00402-013-1731-8), indexed in Pubmed: [23536007](https://pubmed.ncbi.nlm.nih.gov/23536007/).
19. Vanden Berge DJ, Kusnezov NA, Rubin S, et al. Outcomes following isolated posterior interosseous nerve neurectomy: a systematic review. *Hand*. 2017; 12(6): 535–540, doi: [10.1177/1558944717692093](https://doi.org/10.1177/1558944717692093), indexed in Pubmed: [28720049](https://pubmed.ncbi.nlm.nih.gov/28720049/).
20. Waters P, Schwartz JT. Posterior interosseous nerve: An anatomic study of potential nerve grafts. *J Hand Surg*. 1993; 18(4): 743–745, doi: [10.1016/0363-5023\(93\)90331-v](https://doi.org/10.1016/0363-5023(93)90331-v).
21. Wilgis E, Maxwell G. Distal digital nerve grafts: Clinical and anatomical studies. *J Hand Surg*. 1979; 4(5): 439–443, doi: [10.1016/s0363-5023\(79\)80038-6](https://doi.org/10.1016/s0363-5023(79)80038-6).
22. Zwart K, Roeling TAP, van Leeuwen WF, et al. An anatomical study to the branching pattern of the posterior interosseous nerve on the dorsal side of the hand. *Clin Anat*. 2020; 33(5): 678–682, doi: [10.1002/ca.23486](https://doi.org/10.1002/ca.23486), indexed in Pubmed: [31581304](https://pubmed.ncbi.nlm.nih.gov/31581304/).