

The variations and degenerative changes of sacroiliac joints in asymptomatic adults

Ö.F. Cihan¹ , M. Karabulut¹, V. Kiliçoğlu², N. Yavuz³

¹Department of Anatomy, Faculty of Medicine, Gaziantep University, Gaziantep, Turkey

²Department of Orthopaedic Surgery, Faculty of Medicine, Gaziantep University, Gaziantep, Turkey

³Department of Radiology, Faculty of Medicine, Gaziantep University, Gaziantep, Turkey

[Received: 6 July 2019; Accepted: 25 February 2020]

Background: The sacroiliac joint has a structure in which the direction of the load relative to the articular surface is irrational, as the joint surface is not perpendicular to the trunk load axis; it is likely to incur more degenerative changes than other weight-bearing joints.

Materials and methods: This retrospective study consisted of a total of 145 cases — 104 (71.7%) men and 41 (28.3%) women — who were referred to Gaziantep University Medical Faculty Radiology Department Polyclinic for pelvic computed tomography (CT) from 2013 to 2018. The mean age was 33.5 years (range: 18–60 years). Pelvis CT images were performed according to the exclusion criteria specified by the experienced orthopaedic surgeon. Patients were excluded from the study if they were younger than the age of 18, had a condition involving the sacroiliac joint, had an endocrine disorder, or had a history of a trauma affecting the pelvis CT examination.

Results: In this current study, six types of anatomic variations were detected. Iliosacral complex variation has been determined as the most common type of variation. The incidence of variations of sacroiliac joint in all cases was 28.9%. Degenerative changes were seen in 5.5% of patients fewer than 30 years of age. When it comes to the patients whose age range is 30–60, the percentage of the degenerative changes is 12.4%. In patients who were 30 years and older, the prevalence of degenerative changes increased progressively with increasing age.

Conclusions: In this study, it is thought that the knowledge of variations in normal population and degenerative changes will contribute to the better understanding of normal morphological structure of sacroiliac joint and to the anatomical literature. It's seen that there is not a statistically significant relationship between degenerative changes and anatomical variations. (Folia Morphol 2021; 80, 1: 87–96)

Key words: sacroiliac joint, degenerative changes, anatomical variants, accessory joint

INTRODUCTION

The sacroiliac joint (SJ) is the largest joint of the axial skeleton which is involved in a variety of pathological conditions that may affect individuals throughout their lives [23, 24, 36]. The joint has a synovial

portion and large ligamentous areas that are vertically orientated, which allow the entire body weight to be supported with an undulating surface [20, 24, 34]. It has a unique pattern of motion called nutation and counter-nutation. The sacrum essentially flexes and

extends. The normal motion is only 2.5° [16, 20, 29]. The emergence of a pronounced sexual dimorphism in joint structure occurs after puberty. These changes can progress into age-related degenerative processes, more in men than women, involving osteophyte formation and ankylosis [34].

Although some clinicians and researchers acknowledge that there is very limited movement in the SJ, and this movement decreases with aging due to degenerative changes, most physiotherapists, manual therapists and osteopaths have advocated the presence of a significant amount of movement in the SJ [12, 19, 35].

One possible cause of lower back pain is degeneration of the SJ [1, 2, 27, 37]. It has long been known that SJ degeneration is common [3, 6, 25, 26, 35]. The diagnosis of symptomatic SJ degeneration is difficult and based on a combination of patient history, clinical testing, diagnostic joint injections, and radiological examination. Among other radiological techniques, computed tomography (CT) is frequently used, but CT findings of SJ degeneration are also common in a normal population. A clear connection between CT findings and symptoms has not been established [5, 6, 10, 13, 18, 28, 33, 35]. Innovative progress has been made in the diagnosis of the SJ disorders following the use of imaging methods such as magnetic resonance imaging (MRI), and CT in particular [9, 15, 17].

Sacroiliac joints have a lot of structural variations and show some anatomical changes due to the age. Although the normal anatomy of the SJ has been meticulously discussed in the literature, there are only a few reports concerning the anatomical variants [4–6, 22] or the degenerative changes [1, 2, 6, 11, 26] on CT images.

Many studies have investigated accessory sacroiliac joints (ASJ) within the confines of the articulating area of the SJ [5, 8, 9, 14, 22, 30, 32]. Anatomical variants of SJs and the aetiology of the ASJ remain unclear. It is not certain if the ASJ is a congenital condition or if it is an acquired joint [8]. It is frequently found between the medial surface of the posterior superior iliac spine and the lateral crest of sacrum, opposite the second sacral foramen. Less commonly, it is found between the osseous projections at the iliac tuberosity and the lateral crest of sacrum, opposite the first sacral foramen [4, 5, 14, 22, 30, 32]. Comprehensive CT studies allow us to distinguish the normal and the pathologic appearance and they would be very useful

Table 1. Number of patients by age and gender

No. of patients	Age [years]				Total
	18–29	30–39	40–49	50–60	
Men	49	19	21	15	104
Women	25	5	4	7	41
Total	74	24	25	22	145

for the diagnosis of SJ diseases. Trotter [30] reported a similar increase associated with age. She concluded that the joints are acquired in most of the cases [30]. Prassopoulos et al. [22] reported that ASJs were more common in obese people over the age of 60 years, indicating that altered load-bearing stress at the SJs could lead secondarily to the formation of ASJs.

We reviewed the literature to determine underlying mechanism, symptomology, associated pathologies, and clinical importance of degenerative changes of the SJ. The purpose of the present study was to quantify degenerative changes and of the anatomical variations of the SJ in of asymptomatic patients evaluated with high-resolution CT scans. We hypothesized that SJ degeneration would be prevalent in asymptomatic individuals and that the prevalence would increase with age. The study was also to determine if there is a relationship between degenerative changes and anatomical variations.

MATERIALS AND METHODS

This retrospective study consisted of a total of 145 cases — 104 (71.7%) men and 41 (28.3%) women — who were referred to Gaziantep University Medical Faculty Radiology Department Polyclinic for pelvic CT from 2013 to 2018. The mean age was 33.5 ± 12.68 years (range: 18–60 years) (Table 1).

Pelvis CT images were performed according to the exclusion criteria specified by the experienced orthopaedic surgeon. Patients were excluded from the study if they were less than the age of 18, had a condition involving the SJ, had an endocrine disorder, or had a history of a trauma affecting the pelvis.

CT examination. The examinations were performed on CT scanner, one 32-slice scanner GE Healthcare Systems (USA) Lightspeed. CT images of all cases were obtained with the patients in the supine position. The images were reconstructed using a bone algorithm in axial and coronal directions with 7 mm thickness and 5 mm increment. After the SJ was scanned using these cross-sectional ranges,

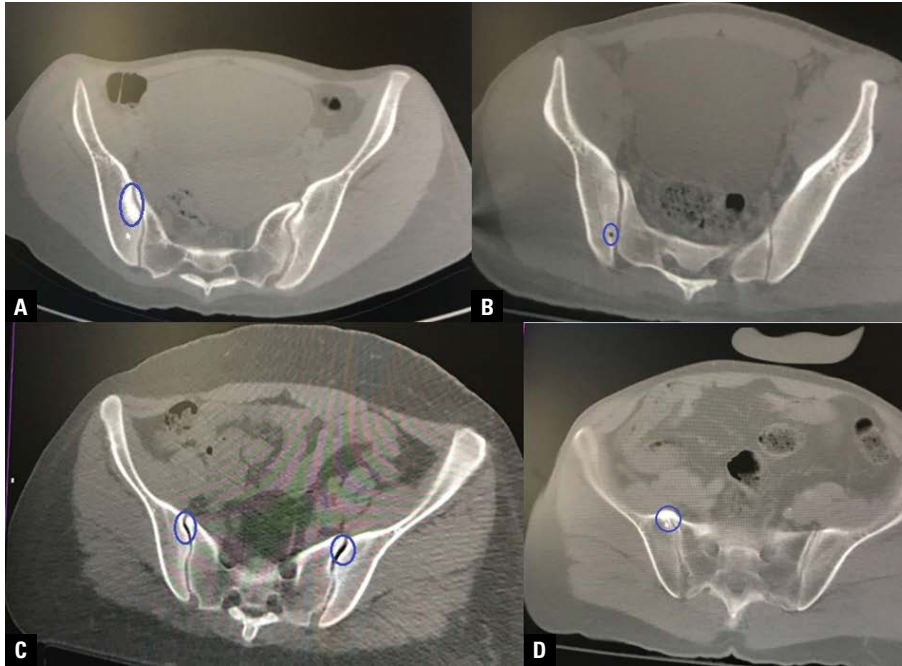


Figure 1. Degenerative changes in the periarticular tissues; **A.** Subchondral sclerosis; **B.** Subchondral cyst; **C.** Vacuum phenomenon; **D.** Ankylosis.

the images required for this current study were examined.

All patients were randomized prior to evaluation. Imaging review was performed in consensus by an orthopaedic surgeon, a radiologist and a PhD student (physiotherapist) in medical sciences (17 and 3 years of experience), blinded to clinical and other imaging findings. The patients were separated by gender and in age intervals of 18–29, 30–39, 40–49 and 50–60 years of age (Table 1).

There is the absence of a previously validated CT classification system for SJ degeneration [2, 6]. SJ degeneration was evaluated by adapting the scoring system described by Eno et al. [6]. Grading was performed according to a protocol designed for this purpose; subchondral sclerosis, vacuum phenomenon, subchondral cyst, joint space narrowing and ankylosis (Fig. 1) were assessed for each. Joints were classified as type 0 if there were no degenerative changes, as type 1 if there were degenerative changes, type 1 if anatomic variants are present and type 0 if anatomic variants are absent SJ. Degenerative changes were quantified in the overall patient population and by decade of life. Moreover, we analysed anatomical variants of the SJ, deviations from the usual appearance of the articular facets of the ilium and sacrum (Table 2).

Table 2. Grading protocol for sacroiliac joint degeneration and anatomical variants

Degenerative changes and anatomical variants	0	1
Subchondral cyst	None	Exist
Subchondral sclerosis	None	Minor or prominent
Vacuum phenomenon	None	Exist
Ankylosis	None	Exist
Joint space narrowing	Normal	Focal or general irregular
Anatomical variants	None	Exis

In addition, the SJ sections of 145 cases were reconstructed in three-dimensional format using the Horos v.3.0.1 software (<https://horosproject.org/>). The values obtained from the measurement of the SJ space on the narrowest and widest parts of the joint on the S1, S2 and S3 vertebra were averaged in the axial and coronal sections. Joint spacing of less than 2 mm indicated narrowing of the joint space [21].

Statistical analysis

The prevalence of degenerative changes was quantified in the overall patient population using Mann-Whitney U-test. Pearson and Spearman correlation analysis was used to determine the relationship between two quantitative variables. One-way

Table 3. Variations in appearance of normal sacroiliac joint on computed tomography examinations in relation to age, gender

No. of patients	Women (n = 41)	Men (n = 104)	18–29 (n = 74)		30–39 (n = 24)		40–49 (n = 25)		50–60 (n = 22)		Total (n = 145)
			Women	Men	Women	Men	Women	Men	Women	Men	
Accessory sacroiliac joint	3 (7.2%)	7 (7.8%)	2	1		2		3	1	1	10 (6.8%)
Iliosacral complex	6 (14.5%)	11 (10.7%)	3	4	2	1	1	3		3	17 (11.7%)
Bipartite iliac bony plate	6 (14.5%)	1 (1%)	4		1			1	1		7 (4.8%)
Crescent like iliac bony plate	—	1 (1%)		1							1 (0.6%)
Semicircular defects	1 (2.4%)	5 (4.9%)	1	1		1		2		1	6 (4.1%)
Ossification centres	—	1 (1%)						1			1 (0.6%)

ANOVA was used to compare variables with more than two groups. Student t-test was used to compare the variables which had only two groups. Analyses were made with statistical software SPSS (Windows version 22.0). $P < 0.05$ was considered statistically significant.

Ethics statement

This retrospective study was initiated after approval from the Clinical Trials Ethical Committee of Gaziantep University ethics committee and carried out in accordance with The Code of Ethics of the World Medical Association (Declaration of Helsinki). (Decision no: 2018/197).

RESULTS

In this study, six different variations were detected in the axial CT sections of the SJ and the distribution of the bilateral and unilateral views of these variations was examined by gender at Table 2. Accordingly, the most frequent variation was determined to be iliosacral complex variation (11 men, 10.7%) in men axial CT sections of the SJ. In addition, variations called accessory SJ (7 men, 7.8%), semicircular defects in iliac and sacral wings (5 men, 4.9%), bipartite iliac bony plate (1 man, 1%), crescent like iliac bony plate (1 man, 1%), and an ossification centres (1 man, 1%) were observed (Table 3).

In females, the most frequent variations were in the iliosacral complex (6 women, 14.5%), and the bipartite iliac bony plate (6 women, 14.5%). These variations were followed by accessory joints (3 women, 7.2%), and semicircular defects in the iliac and sacral wings (1 woman, 2.4%), respectively. Crescent like iliac bony plate or ossification centres variation was not detected in women (Table 3).

While the incidence of variation of SJ in all cases in this study was 28.9%, the incidence of ASJ was 6.8%. The incidence of accessory SJ was detected to be 7.8% in men and 7.2% in women. The ASJ

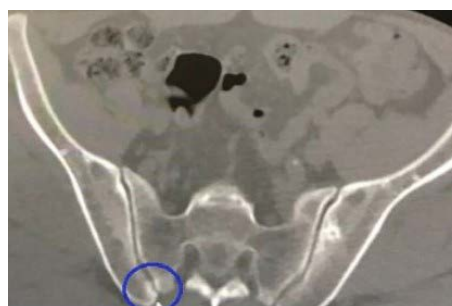

Figure 2. Image of right accessory sacroiliac joints at the S2 vertebra level on the axial computed tomography section in a 56-year-old man patient. A protrusion, extending from the iliac surface towards the sacral surface is observed.

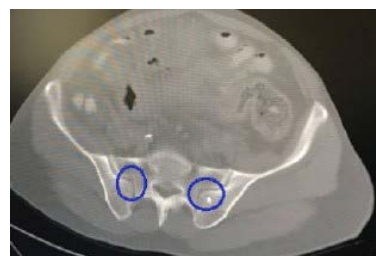

Figure 3. Axial computed tomography section image of the bilateral iliosacral complex at the S2 vertebra level in a 60-year-old man patient. A protrusion and matching cavity is observed on the iliac surface.

was observed to be unilateral in 9 (12.6%) cases and bilateral in 1 (2.4%) case. This variation was determined to form a process from the iliac surface towards the sacral surface in the posterior aspect of the SJ (Fig. 2).

In addition, a total of 17 (11.7%) patients, 11 (10.7%) men and 6 (14.5%) women, were detected to have iliosacral complex variation. The iliosacral complex was unilateral in 12 (17.5%) patients and bilateral in 5 (7.7%) patients. In conclusion, it was detected to be in the form of a tubercle in the facies auricularis of the ilium and a cavity formation in the facies auricularis of the sacrum (Fig. 3).

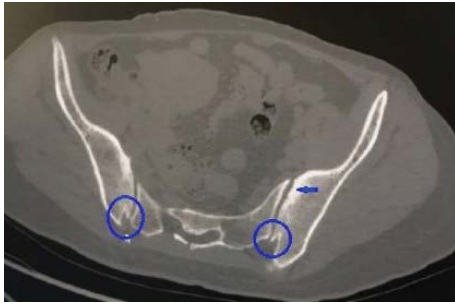

Figure 4. Axial computed tomography section image of the bilateral bipartite iliac bony plate variation (circled) at the S3 vertebral level in a 33-year-old woman patient. The blue arrow indicates subchondral sclerosis at the S1 vertebral level.

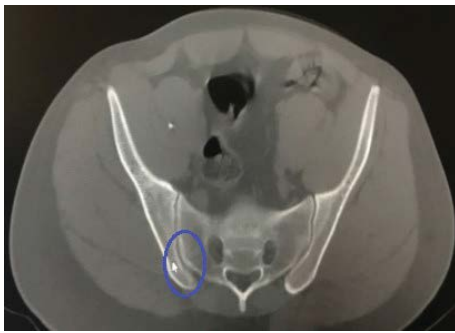

Figure 5. Unilateral axial computed tomography section image of the crescent like iliac bony plate variation at the S2 vertebral level in a 26-year-old man patient.

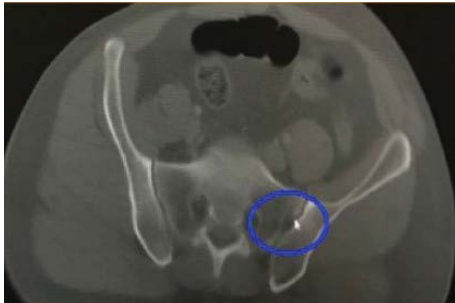

Figure 6. Axial computed tomography section image of the semicircular defects variation at the S1 vertebral level in the sacral bony in a 40-year-old man patient.

In addition, the bipartite iliac bony plate variation was determined in a total of 7 (4.8%) patients, 1 (1%) man and 6 (14.5%) women. The bipartite iliac bony plate was observed to be unilateral in 4 (10.7%) patients and bilateral in 3 (4.8%) patients. As a result of this observation, the variation is characterized by a two-part shape, unlike the normal appearance of the ilium, as well as being mostly detected at the

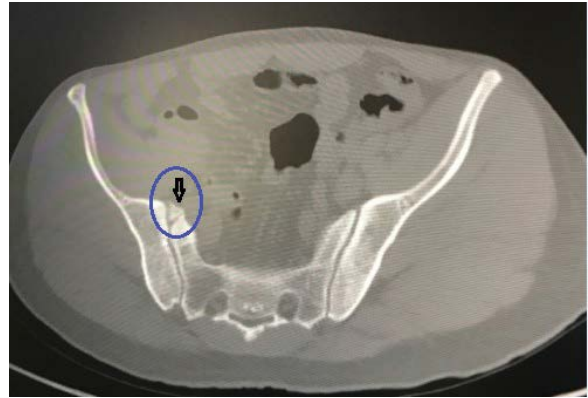


Figure 7. Axial computed tomography section image of the unilateral ossification centre at the S2 vertebral level in the anterior section of the joint space in a 44-year-old man patient.

S2 and S3 vertebral levels in the posterior aspect of the joint (Fig. 4).

In addition, while the crescent like iliac bony plate variation was observed in 1 (1%) man unilaterally, no such variation was observed in women. This formation is characterised by the lunate appearance of the ilium's facies auricularis and the convexity of the sacral surface corresponding to this part. The variation is localised at the S1 vertebral level in the posterior aspect of the joint (Fig. 5).

The variation called semicircular defects was seen in a total of 6 (4.1%) people, 5 (4.9%) men and 1 (2.4%) woman, in the iliac and sacral wings. This variation was observed at the S1 vertebral level in the posterior aspect of the joint, unilaterally in 2 (3%), and bilaterally in 3 (4.3%) patients (Fig. 6).

An ossification centre variation was observed unilaterally in 1 (1%) man. The variation was found to be localised in the anterior aspect of the joint at the S2 vertebral level (Fig. 7).

In our study, total degenerative changes in the SJ were found to be 26 (17.9%) case. The degenerative changes in the present study were also observed in the anterior aspect of the joint and mostly localised in ilium. When degenerative changes in periarticular tissues of SJ were examined; subchondral sclerosis (4.1%), ankylosis (0.7%), vacuum phenomenon (6.8%), subchondral cyst (4.1%) and joint space narrowing (2.1%) were observed (Fig. 1, Table 4).

Degenerative changes were also related to age. Degenerative changes were seen in 5.5% of patients under 30 years of age. When it comes to the patients whose age range is 30–60, the percentage of the degenerative changes is 12.4%. In patients who were

Table 4. Degenerative changes according to age and gender

No. of patients	18–29 (n = 74)		30–39 (n = 24)		40–49 (n = 25)		50–60 (n = 22)		Total (n = 145)
	Women	Men	Women	Men	Women	Men	Women	Men	
Subchondral cyst		4		1				1	6 (4.1%)
Subchondral sclerosis		2				2	1	1	6 (4.1%)
Vacuum phenomenon	1	1	1			2	3	2	10 (6.8%)
Ankylosis						1			1 (0.7%)
Joint space narrowing				1				2	3 (2.1%)
Total	8 (5.51%)		3 (2.07%)		5 (3.44%)		10 (6.89%)		26 (17.91%)

Table 5. Evaluation of joint space by genders in coronal and axial computed tomography sections (mm)

Sacral vertebra level of joint space	Coronal			Axial		
	Men (n = 104)	Women (n = 41)	P	Men (n = 104)	Women (n = 41)	P
Right S1 vertebra level	2.24 ± 0.81	2.18 ± 1.06	0.190	2.16 ± 0.58	2.02 ± 0.57	0.147
Right S2 vertebra level	2.08 ± 0.7	2.1 ± 1	0.887	2.2 ± 0.69	2.2 ± 1.05	0.317
Right S3 vertebra level	2.06 ± 0.64	1.92 ± 0.74	0.657	2.4 ± 0.89	2.46 ± 1.23	0.807
Left S1 vertebra level	2.33 ± 0.8	2.18 ± 0.74	0.292	2.14 ± 0.69	2.1 ± 0.71	0.724
Left S2 vertebra level	2.1 ± 0.77	2.01 ± 0.68	0.772	2.3 ± 0.77	2.28 ± 0.94	0.521
Left S3 vertebra level	2.14 ± 0.68	2.03 ± 0.76	0.261	2.54 ± 0.98	2.47 ± 1.11	0.634

30 years and older, the prevalence of degenerative changes increased progressively with increasing age. Significant differences were found when degenerative changes were evaluated according to age in Table 4. A logistic regression model calculating the increased probability of the presence of SJ degeneration revealed a progressive increase of 2.78 (95% confidence interval: 1.06–7.25) per year of life in the odds of having SJ degeneration. Separate logistic regression model SJ degeneration estimated a 2.78 increase per year of life, peaking at 6.6 in the fifth decade of life.

According to the correlations analysis results, it's seen that there is not a statistically significant relationship between degenerative changes and anatomical variations ($p = 0.137$).

Besides, in this present study, the joint spaces of a total of 145 patients including men and women were measured in the axial and coronal CT sections at the S1, S2 and S3 vertebra levels. According to the measurement, the mean value of the joint space was found to be over 2 mm in both genders and no significant difference was found between the genders (Table 5).

In addition, the mean values of the joint spaces at the S1, S2 and S3 vertebra levels on both sides were found to be over 2 mm in 108 cases with no variation. However, as a result of the measurement

in the axial and coronal CT sections, it was observed that the mean values of the joint space in the joints with variation were less than 2 mm at the S1, S2 and S3 vertebra levels. For all measurements, the values in the joints with variation showed a significant decrease compared to the invisible variation (Table 6).

DISCUSSION

Researchers stated that the synovial part of the SJ had a relatively vertical orientation in CT sections, and the ligamentous part of the joint showed a more oblique orientation [18, 28]. Prassopoulos et al. [22] observed that each SJ has its own subtle characteristics, and no patient in their series exhibited exactly the same SJ appearance as another. Slight differences in orientation and shape of the SJ existed between individuals. The SJ has a structure in which the direction of the load relative to the articular surface is irrational; as the joint surface is not perpendicular to the trunk load axis, it is likely to incur more degenerative changes than other weight-bearing joints [28]. In the present study, although the SJ has a general morphology, each joint was detected to have a unique appearance. Differences in appearance were accentuated by the various degrees and types of degenerative alterations that did not affect in a similar way asymptomatic

Table 6. Evaluation of joint space measurements of joints with and without variation in the axial and axial computed tomography sections (mm)

Sacral vertebra level of joint space	Without variation (n = 108)		With variation (n = 37)		P
	Axial	Coronal	Axial	Coronal	
Right S1 vertebra level	2.35 ± 0.39	2.52 ± 0.78	1.47 ± 0.56	1.29 ± 0.42	0.001
Right S2 vertebra level	2.5 ± 0.59	2.41 ± 0.55	1.35 ± 0.72	1.04 ± 0.47	0.001
Right S3 vertebra level	2.68 ± 0.62	2.32 ± 0.41	1.64 ± 1.41	1.08 ± 0.43	0.001
Left S1 vertebra level	2.38 ± 0.45	2.6 ± 0.57	1.4 ± 0.76	1.29 ± 0.48	0.001
Left S2 vertebra level	2.53 ± 0.49	2.39 ± 0.53	1.59 ± 1.14	1.11 ± 0.42	0.001
Left S3 vertebra level	2.78 ± 0.68	2.41 ± 0.46	1.74 ± 1.39	1.18 ± 0.48	0.001

adults of the same age and gender, and even the two SJs of the same individual. Although the normal anatomy of the SJ has been meticulously discussed in the literature, there are only a few studies concerning the anatomical variants [4, 5, 22] and degenerative changes [1, 2, 6, 7, 28, 38] of the SJ.

The ASJ is the most frequent anatomical variant of the SJ [8, 30]. A frequency of 3.6–50% of ASJ has been described through different studies, including CT scans evaluations [4, 5, 8, 22, 30–32]. Ehara et al. [5] identified the ASJ on 13 (13%) of 100 CT scans of the pelvis and in 9 (16%) of 56 dried skeletons. Prassopoulos et al. [22] in a study that examined the type and prevalence of anatomical variants of the SJ in patients without SJ disease on CT exam identified an ASJ in 19.1% of the 534 CT scans studied. Demir et al. [4], in their study including 400 patients, observed that ASJ was seen between the iliac and sacral articular surfaces in the posterior aspect of the SJ. They detected ASJ in 15.8% of women and in 19.1% of men. They reported the incidence of ASJ as 17.5% in all cases [4]. Valojerdy et al. [32] studied dried bone specimens and identified the ASJ in 18% of their 153 specimens. Although the numbers of Whites and Blacks in the age wise samples in Trotter's study [30] were markedly different, she reported occurrences of ASJs in the two races at 40% and 21%, respectively. In another study of Trotter [31] 50.5% of 485 white people's skeletons and 20.7% of 473 black people's skeletons showed one or more accessory sacroiliac articular facets. Several studies have contributed to our understanding of the prevalence of ASJs. Fortin et al. [8] reported a 3.6% incidence of ASJ from post SJ arthrography CT scans of 559 chronic SJ pain patients. The authors point out that there could be two important reasons why this study detected far fewer ASJs than previously reported studies involving samples of

SJ chronic pain patients. According to Fortin et al. [8], previous authors could have reported "interlocking articulations" present within the SJ as ASJs. Also point out that a focal area of degenerating ankylosis within the main SJ could have been misinterpreted as congenital ASJs in those populations. Although the ASJ is not a rare variant, it might not be very common since normal joint structure or degenerative changes in the SJ could masquerade as accessory joints [8]. In the present study, the incidence of ASJ was detected as 7.8% in men and 7.2% in women. While the incidence of SJ variants in all cases in the study was 28.9%, the incidence of ASJ was 6.8%. The contrasting findings between the current and previous reports may be attributed to a difference in patient population base because the subjects of our studies were asymptomatic adults and cases' mean age of the subjects in this study (33.5 years) is lower. Walker [36] had reported that there are evident discrepancies in the ASJ prevalence rates reported from different studies, possibly because of different imaging protocols or over- or underdetection of conditions due to overlapping normal joint structure or degenerative changes masquerading as accessory joints.

Prassopoulos et al. [22] detected iliosacral complex in a total of 31 (5.8%) cases in their study. Demir et al. [4] reported that they detected iliosacral complex in a total of 38 (9.5%) cases in their study. Prassopoulos et al. [22] reported in their study that iliosacral complex is more common in women. In this study, however, iliosacral complex was found in 17 (11.7%) cases and this variation was observed in men more frequently — 11 (10.7%) men.

Demir et al. [4] reported in their study that the bipartite iliac bony plate was not observed bilaterally and it was localized in the posterior aspect of the joint in 22 (5.5%) cases, and they observed that it was

more common in men. Prassopoulos et al. [22] found in their study that the bipartite iliac bony plate was localised in the posterior aspect of the joint in a total of 22 (4.1%) cases, unilaterally in 6 (1.1%) cases, and bilaterally in 16 (3.0%) cases. Prassopoulos et al. [22] reported that the bipartite iliac bony plate is more common in women. In the present study, the bipartite iliac bony plate was observed in the posterior aspect of the joint in a total of 7 (4.8%) cases, unilaterally in 4 (10.7%) cases and bilaterally in 3 (4.8%) cases. In addition, the bipartite iliac bony plate was seen more commonly in women, with 6 (14.5%) female patients compared to 1 (1%) male patient, which supports the study of Prassopoulos et al. [22].

Prossopoulos et al. [22] found crescent-like iliac bony plate variation in 20 (3.7%) cases. Demir et al. [4] found crescent-like iliac bony plate in 14 (3.5%) cases in their study. In this current study, unilateral crescent like iliac bony plate variation was observed in 1 (1%) men patient while it was not observed in women patients.

Prossopoulos et al. [22] reported in their study that they detected semicircular defect in the sacral and iliac bones in a total of 16 (3%) cases. Demir et al. [4] reported in their study that they detected semicircular defect in the sacral and iliac bones in a total of 19 (4.8%) cases. In this present study, the semicircular defect in sacral and iliac bones was observed in a total of 6 (4.1%) cases.

Prossopoulos et al. [22] reported that the ossification centres in the sacral wings in a total of 3 (0.6%) cases, 2 (0.9%) men and 1 (0.3%) woman. Demir et al. [4] reported in their study that they observed ossification centres in the sacral wings in a total of 4 (1.0%) cases, 1 (0.5%) man and 3 (1.5%) women. In this present study, while no ossification centres in the sacral wings was observed in women, it was detected a total of 1 (0.6%) case.

In concordance with other reports, SJ degeneration is common in non-symptomatic adults in the early decades of life and increases with age [2, 6, 28, 35]. Past studies have shown that degeneration of the SJ is more prevalent in the elderly population, but these changes tend to plateau in the higher age groups [1, 2, 6, 28, 38]. Given the high prevalence of pain-free SJ degeneration, physicians must be cautious in attributing low back pain to degenerative changes of the SJ seen on cross-sectional imaging [2, 6]. For this study a system was designed including established characteristics of subchondral sclerosis, vacuum phe-

nomenon, subchondral cyst, joint space narrowing and ankylosis. There are a number of limitations of this study. One of these limitations is related to age; in our study, the patient population was composed of asymptomatic adults aged 18–60 years. Eno et al. [6] examined SJs in patients aged 0 to 99 years, Bäcklund et al. [2] 20–70+ years of age, Asada et al. [1] 50–70+ years of age, Shibata et al. [28] 20–70+ years of age, Yagan et al. [38] 55 years and over, and Faglia et al. [7] aged 15 to 83 years. Further studies [2, 6, 7] were found that degenerative changes increased with age in asymptomatic patient groups similar to age group of this research. However, previous studies [1, 2, 6, 7, 28, 38] showed that the prevalence of degenerative changes in non-asymptomatic and 60+ age group was very high compared to our study.

Postacchini et al. [21] measured the SJ space in the axial and coronal CT sections on both sides, at the S1, S2 and S3 vertebral levels in their study. As a result of their measurements, they defined a joint space under 2 mm as narrowing of the joint space. In their study, Demir et al. [4] reported that the SJ space was less than 2 mm in the joints with variation. Ehara et al. [5] and Hadley [14] reported in their studies that narrowing of the joint space was observed in the joints with variation. However, the researchers did not provide a numeric value on the subjects. In this present study, the SJ space was measured in the axial and coronal CT sections on the right and left sides, at the S1, S2 and S3 vertebral levels. According to the measurements, while the joint space was over 2 mm in the people without variation in their joints, it was detected to be over 2 mm in the joints with variation. This study supports the studies related to the measurement of joint space of SJ.

CONCLUSIONS

This study was carried out to contribute to the knowledge of anatomical variations in the normal population, to understand the normal morphological structure of SJ, and to the anatomical literature and radiologists to evaluate and interpret CT images. The prevalence of SJ degeneration in asymptomatic adults is high and increases significantly with age. It's seen that there is not a statistically significant relationship between degenerative changes and anatomical variants.

REFERENCES

1. Asada M, Tokunaga D, Arai Y, et al. Degeneration of the sacroiliac joint in hip osteoarthritis patients: a three-dimensional image analysis. *J Belg Soc Radiol.* 2019;

- 103(1): 36, doi: [10.5334/jbsr.1648](https://doi.org/10.5334/jbsr.1648), indexed in Pubmed: [31149653](https://pubmed.ncbi.nlm.nih.gov/31149653/).
2. Bäcklund J, Clewett Dahl E, Skorpil M. Is CT indicated in diagnosing sacroiliac joint degeneration? *Clin Radiol*. 2017; 72(8): 693.e9–693.e13, doi: [10.1016/j.crad.2017.03.006](https://doi.org/10.1016/j.crad.2017.03.006), indexed in Pubmed: [28388969](https://pubmed.ncbi.nlm.nih.gov/28388969/).
 3. Cohen AS, McNeill JM, Calkins E, et al. The “normal” sacroiliac joint. Analysis of 88 sacroiliac roentgenograms. *Am J Roentgenol Radium Ther Nucl Med*. 1967; 100(3): 559–563, indexed in Pubmed: [6028970](https://pubmed.ncbi.nlm.nih.gov/6028970/).
 4. Demir M, Mavi A, Gümüşburun E, et al. Anatomical variations with joint space measurements on CT. *Kobe J Med Sci*. 2007; 53(5): 209–217, indexed in Pubmed: [18204297](https://pubmed.ncbi.nlm.nih.gov/18204297/).
 5. Ehara S, el-Khoury GY, Bergman RA. The accessory sacroiliac joint: a common anatomic variant. *Am J Roentgenol*. 1988; 150(4): 857–859, doi: [10.2214/ajr.150.4.857](https://doi.org/10.2214/ajr.150.4.857), indexed in Pubmed: [3258099](https://pubmed.ncbi.nlm.nih.gov/3258099/).
 6. Eno JJT, Boone CR, Bellino MJ, et al. The prevalence of sacroiliac joint degeneration in asymptomatic adults. *J Bone Joint Surg Am*. 2015; 97(11): 932–936, doi: [10.2106/JBJS.N.01101](https://doi.org/10.2106/JBJS.N.01101), indexed in Pubmed: [26041855](https://pubmed.ncbi.nlm.nih.gov/26041855/).
 7. Faflija CP, Prassopoulos PK, Daskalogiannaki ME, et al. Variation in the appearance of the normal sacroiliac joint on pelvic CT. *Clin Radiol*. 1998; 53(10): 742–746, doi: [10.1016/s0009-9260\(98\)80316-4](https://doi.org/10.1016/s0009-9260(98)80316-4), indexed in Pubmed: [9817091](https://pubmed.ncbi.nlm.nih.gov/9817091/).
 8. Fortin JD, Ballard KE. The frequency of accessory sacroiliac joints. *Clin Anat*. 2009; 22(8): 876–877, doi: [10.1002/ca.20772](https://doi.org/10.1002/ca.20772), indexed in Pubmed: [19173249](https://pubmed.ncbi.nlm.nih.gov/19173249/).
 9. Friedman L, Silberberg PJ, Rainbow A, et al. A limited, low-dose computed tomography protocol to examine the sacroiliac joints. *Can Assoc Radiol J*. 1993; 44(4): 267–272, indexed in Pubmed: [8348354](https://pubmed.ncbi.nlm.nih.gov/8348354/).
 10. Gilula LA, Murphy WA, Taylor CC, et al. Computed tomography of the osseous pelvis. *Radiology*. 1979; 132(1): 107–114, doi: [10.1148/132.1.107](https://doi.org/10.1148/132.1.107), indexed in Pubmed: [451181](https://pubmed.ncbi.nlm.nih.gov/451181/).
 11. Gohil I, Vilensky JA, Weber EC. Vacuum phenomenon: Clinical relevance. *Clin Anat*. 2014; 27(3): 455–462, doi: [10.1002/ca.22334](https://doi.org/10.1002/ca.22334), indexed in Pubmed: [24288359](https://pubmed.ncbi.nlm.nih.gov/24288359/).
 12. Grieve EF. Mechanical dysfunction of the sacro-iliac joint. *Int Rehabil Med*. 1983; 5(1): 46–52, doi: [10.3109/096388288309166940](https://doi.org/10.3109/096388288309166940), indexed in Pubmed: [6885271](https://pubmed.ncbi.nlm.nih.gov/6885271/).
 13. Ha KY, Lee JS, Kim KW, et al. Degeneration of sacroiliac joint after instrumented lumbar or lumbosacral fusion: a prospective cohort study over five-year follow-up. *Spine (Phila Pa 1976)*. 2008; 33(11): 1192–1198, doi: [10.1097/BRS.0b013e318170fd35](https://doi.org/10.1097/BRS.0b013e318170fd35), indexed in Pubmed: [18469692](https://pubmed.ncbi.nlm.nih.gov/18469692/).
 14. Hadley LA. Accessory sacroiliac articulations with arthritic changes. *Radiology*. 1950; 55(3): 403–409, doi: [10.1148/55.3.403](https://doi.org/10.1148/55.3.403), indexed in Pubmed: [14781347](https://pubmed.ncbi.nlm.nih.gov/14781347/).
 15. Kanberoglu K, Mihmanli I, Kurugoglu S, et al. Bone marrow changes adjacent to the sacroiliac joints after pelvic radiotherapy mimicking metastases on MRI. *Eur Radiol*. 2001; 11(9): 1748–1752, doi: [10.1007/s003300100819](https://doi.org/10.1007/s003300100819), indexed in Pubmed: [11511897](https://pubmed.ncbi.nlm.nih.gov/11511897/).
 16. Kibsgård TJ, Røise O, Stuesson B, et al. Radiostereometric analysis of movement in the sacroiliac joint during a single-leg stance in patients with long-lasting pelvic girdle pain. *Clin Biomech (Bristol, Avon)*. 2014; 29(4): 406–411, doi: [10.1016/j.clinbiomech.2014.02.002](https://doi.org/10.1016/j.clinbiomech.2014.02.002), indexed in Pubmed: [24602677](https://pubmed.ncbi.nlm.nih.gov/24602677/).
 17. Kozin F, Carrera GF, Ryan LM, et al. Computed tomography in the diagnosis of sacroiliitis. *Arthritis Rheum*. 1981; 24(12): 1479–1485, doi: [10.1002/art.1780241205](https://doi.org/10.1002/art.1780241205), indexed in Pubmed: [6976786](https://pubmed.ncbi.nlm.nih.gov/6976786/).
 18. Lawson TL, Foley WD, Carrera GF, et al. The sacroiliac joints: anatomic, plain roentgenographic, and computed tomographic analysis. *J Comput Assist Tomogr*. 1982; 6(2): 307–314, indexed in Pubmed: [6210717](https://pubmed.ncbi.nlm.nih.gov/6210717/).
 19. Lee D. *The Pelvic Girdle*. Churchill Livingstone. Longman Group, New York 1989.
 20. Polly DW. The Sacroiliac Joint. *Neurosurg Clin N Am*. 2017; 28(3): 301–312, doi: [10.1016/j.nec.2017.03.003](https://doi.org/10.1016/j.nec.2017.03.003), indexed in Pubmed: [28600004](https://pubmed.ncbi.nlm.nih.gov/28600004/).
 21. Postacchini R, Trasimeni G, Ripani F, et al. Morphometric anatomical and CT study of the human adult sacroiliac region. *Surg Radiol Anat*. 2017; 39(1): 85–94, doi: [10.1007/s00276-016-1703-0](https://doi.org/10.1007/s00276-016-1703-0), indexed in Pubmed: [27324173](https://pubmed.ncbi.nlm.nih.gov/27324173/).
 22. Prassopoulos PK, Faflija CP, Voloudaki AE, et al. Sacroiliac joints: anatomical variants on CT. *J Comput Assist Tomogr*. 1999; 23(2): 323–327, doi: [10.1097/00004728-199903000-00029](https://doi.org/10.1097/00004728-199903000-00029), indexed in Pubmed: [10096348](https://pubmed.ncbi.nlm.nih.gov/10096348/).
 23. Rana SH, Farjoodi P, Haloman S, et al. Anatomic evaluation of the sacroiliac joint: a radiographic study with implications for procedures. *Pain Physician*. 2015; 18(6): 583–592, indexed in Pubmed: [26606010](https://pubmed.ncbi.nlm.nih.gov/26606010/).
 24. Rebello da Veiga T, Custódio da Silva A, Gomes da Silva RT, et al. Intra-observer reliability in three-dimensional kinematic analysis of sacroiliac joint mobility. *J Phys Ther Sci*. 2015; 27(4): 1001–1004, doi: [10.1589/jpts.27.1001](https://doi.org/10.1589/jpts.27.1001), indexed in Pubmed: [25995542](https://pubmed.ncbi.nlm.nih.gov/25995542/).
 25. Resnick D, Niwayama G, Goergen TG. Comparison of radiographic abnormalities of the sacroiliac joint in degenerative disease and ankylosing spondylitis. *Am J Roentgenol*. 1977; 128(2): 189–196, doi: [10.2214/ajr.128.2.189](https://doi.org/10.2214/ajr.128.2.189), indexed in Pubmed: [401599](https://pubmed.ncbi.nlm.nih.gov/401599/).
 26. Resnick D, Niwayama G, Goergen TG, et al. Degenerative disease of the sacroiliac joint. *Invest Radiol*. 1975; 10(6): 608–621, doi: [10.1097/00004424-197511000-00008](https://doi.org/10.1097/00004424-197511000-00008), indexed in Pubmed: [1201940](https://pubmed.ncbi.nlm.nih.gov/1201940/).
 27. Shaffrey CI, Smith JS. Stabilization of the sacroiliac joint. *Neurosurg Focus*. 2013; 35(2 Suppl): Editorial, doi: [10.3171/2013.V2.FOCUS13273](https://doi.org/10.3171/2013.V2.FOCUS13273), indexed in Pubmed: [23829837](https://pubmed.ncbi.nlm.nih.gov/23829837/).
 28. Shibata Y, Shirai Y, Miyamoto M. The aging process in the sacroiliac joint: helical computed tomography analysis. *J Orthop Sci*. 2002; 7(1): 12–18, doi: [10.1007/s776-002-8407-1](https://doi.org/10.1007/s776-002-8407-1), indexed in Pubmed: [11819126](https://pubmed.ncbi.nlm.nih.gov/11819126/).
 29. Stuesson B, Uden A, Vleeming A. A radiostereometric analysis of movements of the sacroiliac joints during the standing hip flexion test. *Spine (Phila Pa 1976)*. 2000; 25(3): 364–368, doi: [10.1097/00007632-200002010-00018](https://doi.org/10.1097/00007632-200002010-00018), indexed in Pubmed: [10703111](https://pubmed.ncbi.nlm.nih.gov/10703111/).
 30. Trotter M. Accessory sacroiliac articulations in east african skeletons. *Am J Phys Anthropol*. 1964; 22(2): 137–141, doi: [10.1002/ajpa.1330220213](https://doi.org/10.1002/ajpa.1330220213), indexed in Pubmed: [14243699](https://pubmed.ncbi.nlm.nih.gov/14243699/).
 31. Trotter M. Accessory sacro-iliac articulations. *Am J Phys Anthropol*. 1937; 22(2): 247–261, doi: [10.1002/ajpa.1330220205](https://doi.org/10.1002/ajpa.1330220205).

32. Valoerdy MR, Hogg DA. Anatomical note: The occurrence of accessory sacroiliac joints in man. *Clin Anat.* 1990; 3(4): 257–260, doi: [10.1002/ca.980030403](https://doi.org/10.1002/ca.980030403).
33. van der Linden S, Valkenburg HA, Cats A. Evaluation of diagnostic criteria for ankylosing spondylitis. A proposal for modification of the New York criteria. *Arthritis Rheum.* 1984; 27(4): 361–368, doi: [10.1002/art.1780270401](https://doi.org/10.1002/art.1780270401), indexed in Pubmed: [6231933](https://pubmed.ncbi.nlm.nih.gov/6231933/).
34. Vleeming A, Van Wingerden JP, Dijkstra PF, et al. Mobility in the sacroiliac joints in the elderly: a kinematic and radiological study. *Clin Biomech (Bristol, Avon).* 1992; 7(3): 170–176, doi: [10.1016/0268-0033\(92\)90032-Y](https://doi.org/10.1016/0268-0033(92)90032-Y), indexed in Pubmed: [23915725](https://pubmed.ncbi.nlm.nih.gov/23915725/).
35. Vogler JB, Brown WH, Helms CA, et al. The normal sacroiliac joint: a CT study of asymptomatic patients. *Radiology.* 1984; 151(2): 433–437, doi: [10.1148/radiology.151.2.6709915](https://doi.org/10.1148/radiology.151.2.6709915), indexed in Pubmed: [6709915](https://pubmed.ncbi.nlm.nih.gov/6709915/).
36. Walker JM. The sacroiliac joint: a critical review. *Phys Ther.* 1992; 72(12): 903–916, doi: [10.1093/ptj/72.12.903](https://doi.org/10.1093/ptj/72.12.903), indexed in Pubmed: [1454866](https://pubmed.ncbi.nlm.nih.gov/1454866/).
37. Whang P, Cher D, Polly D, et al. Sacroiliac joint fusion using triangular titanium implants vs. Non-Surgical management: six-month outcomes from a prospective randomized controlled trial. *Int J Spine Surg.* 2015; 9: 6, doi: [10.14444/2006](https://doi.org/10.14444/2006), indexed in Pubmed: [25785242](https://pubmed.ncbi.nlm.nih.gov/25785242/).
38. Yagan R, Khan MA, Marmolya G. Role of abdominal CT, when available in patients' records, in the evaluation of degenerative changes of the sacroiliac joints. *Spine (Phila Pa 1976).* 1987; 12(10): 1046–1051, doi: [10.1097/00007632-198712000-00017](https://doi.org/10.1097/00007632-198712000-00017), indexed in Pubmed: [3502035](https://pubmed.ncbi.nlm.nih.gov/3502035/).