

# An odontometric study of tooth dimension in diastematic dentition

A. Sękowska<sup>1</sup>, R. Chałas<sup>2</sup>

<sup>1</sup>Department of Jaw Orthopaedics, Medical University of Lublin, Poland

<sup>2</sup>Department of Oral Medicine, Medical University of Lublin, Poland

[Received: 15 August 2019; Accepted: 10 September 2019]

**Background:** One of the causes of the maxillary midline diastema (MMD) may be discrepancy between teeth and maxilla dimension. That can relate to two situations: when teeth have correct size but maxilla is too large or maxilla bone is in the proper size but teeth have reduced dimensions (microdontia). The present study has been conducted to investigate the differences in the linear dimensions of upper central and lateral incisors and canines in diastematic dentition and to compare them with the control group without diastema.

**Materials and methods:** The study was conducted on Caucasian individuals ( $n = 102$ ) divided into two groups: study group with MMD ( $n = 50$ ) and control group without MMD ( $n = 52$ ). The following measurements were done by digital calliper on their plaster models: 1. Width in the widest mesiodistal portion for upper right and left central incisors, lateral incisors and canines. 2. Length in the longest apico-coronal portion for the same teeth.

**Results:** Statistical analysis showed that comparisons of widths of left canines were significant. In the study group widths of left canines were lower than in the control group. Statistically significant differences in the length were observed for central incisors and canines in both sides. All measurements were lower in the diastema group of patients.

**Conclusions:** Patients with diastema were characterised by incorrect tooth dimensions. The central incisors and upper canines were shorter in this group. Aesthetic closing of the diastema requires not only widening the crowns of the front teeth but also their elongation. (Folia Morphol 2020; 79, 3: 604–609)

**Key words:** maxillary midline diastema (MMD), length of incisors, width of incisors, length of canines, width of canines

## INTRODUCTION

Odontometric data using tooth dimensions have been implemented in various studies of populations in order to determine gender, ethnicity, geographical factors and other variations. Such data include tooth size and morphology, which can also vary in the spaced dentition. When it comes to the primary and

mixed dentitions, anterior spaces are common and considered as normal phenomenon. In the permanent dentition, however, reported incidence ranges from 3.7% [33] to 36.8% [26] in different populations. This incidence is higher in the case of black individuals than among white or yellow population groups. Maxillary midline diastema (MMD) — the anterior

space between upper central incisors is a common aesthetic concern of dental patients, as it may disrupt their dentofacial harmony. Moreover, diastemas in different places, i.e. between lateral incisors and canines or canines and premolars in upper and lower dental arch are also frequently observed [12].

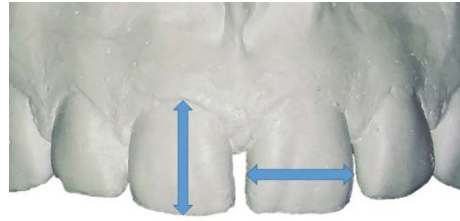
Among many theories concerning the aetiology of MMD, the one about discrepancy between teeth and maxilla dimension is often cited. This can relate to two situations: when teeth have correct size but maxilla is too large [30] or maxilla bone is in the proper size but teeth have reduced dimensions (microdontia). Both cases may cause the formation of diastema and even polydiastema [4, 20, 25]. The microdontia most frequently concerns the lateral maxillary incisors which have either reduced dimensions or a crown with an incorrect structure in the peg-shaped lateral incisor [21]. They cause the gaps mainly in lateral incisors area; however, through the migration of the central incisors they may also become the cause of the central diastema. Similarly, through tooth migration, multiple diastemas are created in cases of hypodontia, i.e. a congenital lack of a tooth bud or loss of lateral incisors in the jaw [16]. The formation of gaps in the anterior part of the dental arch is influenced not only by the anterior teeth, but also by the loss of support in the lateral sections, extraction or agenesis of the premolars. Some investigators have also suggested that improper frenum attachment of upper lip, which is adhered to papilla or penetrating to papilla between central incisors, may contribute to diastema development [1, 11].

The measurement of teeth proportions in patients with MMD is important in their treatment planning. Incorrect size or shape of teeth is an indication to the aesthetic restoration of upper incisors [3, 8, 10, 14, 22, 28]. Depending on the aetiology, the treatment may also take place in a different way, i.e. orthodontic treatment [13, 17, 24] or surgical treatment [32, 34] of diastema.

Preliminary studies on the width/length ratio of upper anterior teeth were done in the past only in a pilot group of patients [30]. The present study, therefore, has been conducted to investigate the differences in the linear dimensions of upper central and lateral incisors and canines in diastematic dentition and to compare them with the control group without diastema.

## MATERIALS AND METHODS

The study was conducted in the Department of Jaw Orthopaedics on diagnostic orthodontic plaster



**Figure 1.** Measurement of length and width of teeth crown.

models. The subjects ( $n = 102$ ) were divided into two groups: study group with MMD ( $n = 50$ ) and control group without MMD ( $n = 52$ ). All patients were Caucasians. Both groups were close in age to each other. Mean age in the study group was  $24.00 \pm 6.26$  years and in the control group  $22.45 \pm 5.28$  years. The majority of the groups consisted of women (78.8% in the group with MMD and 86% in the group without MMD). The occlusion status was similar in both groups. The first Angle's class (proper occlusion) was dominant (96.2% in the study group and 76% in the control group). The permanent dentition (DS4M2) according to Björk, that means Dental Stage 4 — fully erupted canines and premolars, and M2 — fully erupted second molars, was also prevalent [5]. The exclusion criteria were individuals with severe malocclusion, craniofacial diseases, hypodontia or microdontia of teeth and periodontal disease.

The digital calliper accurate to 0.01 mm was used for the following measurements:

- width in the widest mesiodistal portion for upper right (R), and left (L) central incisors (CI), lateral incisors (LI) and canines (C) (Fig. 1);
- length in the longest apico-coronal portion for the same teeth (Fig. 1).

All the participants were informed about the study, and consent was obtained from all of them. The Bioethics Committee of the Medical University of Lublin approved the research (No. KE-0254/29/2014).

All the measurements were tabulated in Microsoft Excel and statistical analysis in programme Statistica 10 was done to compare the dimensions of teeth. The results were presented in Tables 1, 2 and 3.

## RESULTS

Measurements of the width of investigated teeth are illustrated in Table 1. Descriptive statistics showed that the mean width of the right medial incisor in the group of diastema patients was  $8.44 \pm 0.49$  mm and in the group of patients without diastema this

**Table 1.** Mean widths of upper anterior teeth in groups with and without maxillary midline diastema (MMD)

Tooth	Mean	SD	V%	Minimum	Q1	Median	Q3	Maximum
<b>Study group with MMD</b>								
RCI	8.44	0.49	5.76	7.14	8.06	8.49	8.75	9.67
LCI	8.42	0.54	6.36	7.10	8.11	8.41	8.75	9.54
RLI	6.47	0.59	9.20	4.15	6.13	6.50	6.91	7.38
LLI	6.46	0.60	9.25	5.11	6.08	6.50	6.80	7.99
RC	7.61	0.43	5.70	6.40	7.28	7.63	7.93	8.76
LC	7.58	0.47	6.24	6.72	7.32	7.51	7.74	9.58
<b>Control group without MMD</b>								
RCI	8.50	0.43	5.11	7.79	8.16	8.54	8.75	9.55
LCI	8.47	0.43	5.06	7.32	8.15	8.46	8.73	9.40
RLI	6.62	0.64	9.71	4.64	6.30	6.63	7.05	7.88
LLI	6.61	0.56	8.49	5.15	6.20	6.64	6.99	7.61
RC	7.72	0.43	5.60	6.79	7.47	7.69	8.11	8.56
LC	7.75	0.41	5.25	6.95	7.40	7.75	8.11	8.52

RCI — right central incisor; LCI — left central incisor; RLI — right lateral incisor; LLI — left lateral incisor; RC — right canine; LC — left canine; SD — standard deviation

**Table 2.** Mean lengths of upper anterior teeth in groups with and without maxillary midline diastema (MMD)

Tooth	Mean	SD	V%	Minimum	Q1	Median	Q3	Maximum
<b>Study group with MMD</b>								
RCI	9.16	0.98	10.68	7.14	8.56	9.13	9.75	11.50
LCI	9.17	0.91	9.91	6.51	8.61	9.22	9.77	11.48
RLI	7.71	0.87	11.26	5.63	7.09	7.64	8.37	9.48
LLI	7.83	0.94	11.94	5.80	7.09	7.88	8.50	9.56
RC	8.63	0.90	10.37	7.07	8.02	8.54	9.18	11.41
LC	8.66	0.97	11.23	6.91	7.98	8.45	9.50	11.35
<b>Control group without MMD</b>								
RCI	9.64	1.14	11.85	7.36	8.82	9.54	10.34	12.18
LCI	9.80	1.14	11.68	7.71	9.00	9.86	10.65	12.28
RLI	7.86	1.08	13.75	6.14	7.17	7.75	8.35	10.44
LLI	8.19	1.16	14.22	6.18	7.37	8.20	8.75	12.01
RC	9.30	1.17	12.59	7.72	8.35	9.27	9.92	12.48
LC	9.34	1.04	11.14	7.46	8.66	9.22	10.03	11.92

RCI — right central incisor; LCI — left central incisor; RLI — right lateral incisor; LLI — left lateral incisor; RC — right canine; LC — left canine; SD — standard deviation

measurement was  $8.50 \pm 0.43$  mm. In the MMD group the mean width of the left medial incisor was  $8.42 \pm 0.54$  mm and in the group without MMD it was  $8.47 \pm 0.43$  mm. The mean width of the right and left lateral incisors was accordingly in the study group  $6.47 \pm 0.59$  mm and  $6.46 \pm 0.60$  mm, and in the control group  $6.62 \pm 0.64$  mm and  $6.61 \pm 0.56$  mm. The mean width of the right canine in the group of patients with diastema was  $7.61 \pm 0.43$  mm and left canine was  $7.58 \pm 0.47$  mm. In the group of

patients without diastema RC was  $7.72 \pm 0.43$  mm width and LC  $7.75 \pm 0.41$  mm. Statistical analysis showed that comparison of widths of all anterior teeth released significant differences only for LC. In the study group widths of LC were lower than in control group (Table 3).

Measurements of the length of teeth are presented in Table 2. Descriptive statistics showed that the mean length of the right medial incisor in the group of diastema patients was  $9.16 \pm 0.98$  mm and in the group

**Table 3.** Statistical analysis of width and length of upper anterior teeth

Tooth	Test	P	Test F (p)
<b>Width</b>			
RCI	t-student	0.4573	0.4352
LCI	t-student	0.5885	0.1215
RLI	U Mann-Whitney	0.1721	
LLI	t-student	0.1981	0.6594
RC	t-student	0.1971	0.9872
LC	U Mann-Whitney	<b>0.0336</b>	
<b>Length</b>			
RCI	t-student	<b>0.0237</b>	0.2735
LCI	t-student	<b>0.0026</b>	0.1051
RLI	U Mann-Whitney	0.8408	
LLI	U Mann-Whitney	0.1987	
RC	U Mann-Whitney	<b>0.0043</b>	
LC	t-student	<b>0.001</b>	0.6326

RCI — right central incisor; LCI — left central incisor; RLI — right lateral incisor; LLI — left lateral incisor; RC — right canine; LC — left canine

of patients without diastema this measurement was  $9.64 \pm 1.14$  mm. In the MMD group the mean width of the left central incisor was  $9.17 \pm 0.91$  mm and in the group without MMD it was  $9.80 \pm 1.14$  mm. The mean length of the right and left lateral incisors was accordingly in the study group  $7.71 \pm 0.87$  mm and  $7.83 \pm 0.94$  mm, and in the control group  $7.86 \pm 1.08$  mm and  $8.19 \pm 1.16$  mm. The mean length of the RC in the group of patients with diastema was  $8.63 \pm 0.90$  mm and LC was  $8.66 \pm 0.97$  mm. In the group of patients without diastema RC was  $9.30 \pm 1.17$  mm length and LC  $9.34 \pm 1.04$  mm.

Statistically significant differences concerning length were observed in the case of central incisors and canines in both sides. These odontometric measurements were lower in diastematic dentition (Table 3).

## DISCUSSION

Maintaining the right dimensions of the width, length and width/length ratio of the upper front teeth is important in achieving the aesthetic appearance after composite or prosthetic reconstructions [9]. In cases with diastema where widening of incisors was required also lengthen of teeth should be planned to achieve proper width/length ratio [7, 10, 15, 27]. This was confirmed in our results where lengths of central incisors and canines were significantly shorter

in the investigated diastematic group in comparison with the control group.

A study performed by Gillen et al. [15], which was conducted on randomly selected diagnostic models of adult patients, showed that the length of central incisors and canines was almost the same. Central incisors and canines were longer than the maxillary lateral incisors. These results were similar to the study group but slightly differ from the results obtained in the control group, where central incisors were the longest, canines slightly shorter and lateral incisors the shortest. Magne et al. [23] obtained the same relationship of the length of the upper front teeth as in our control group.

According to the width of upper anterior teeth in both investigated groups, the following relationship was observed: the central incisors were the widest teeth compared to lateral incisors and canines. This relationship was confirmed by many different authors [18, 23, 31] who reported that central incisors were wider than lateral incisors by 25% and 10% wider than canines [15].

In many publications the results of the study of the teeth size in groups with crowding in comparison with normal occlusion were presented. Most of them concluded that the size of teeth affects the formation of crowding, and in crowded groups the teeth are larger [2, 19, 29]. Moreover, comparison of groups with crowding with normal occlusion and with diastemas showed the superiority of dental material correlated with the occurrence of crowded teeth [6]. In the study group with diastema differences in the width of upper front teeth were observed but statistically significant difference was only for the width of the LC. The results of teeth width in diastema group in the Bugaighis's study were almost the same as the results of width in the study group [6].

The results of own research indicate that patients with diastema have incorrect proportions of crowns of the anterior teeth; therefore, it should be taken under attention in the treatment planning because orthodontic closure of diastema alone will not give a proper aesthetic effect. In such cases composite or porcelain reconstruction of the teeth crowns in order to improve their proportion is indicated. Another option is a surgical correcting of the gingiva and giving the right shape to the gum garland and line. All these procedures may be required to obtain the harmonic and aesthetic smile of the patient [8, 10].

## CONCLUSIONS

Patients with diastema were characterised by incorrect tooth dimensions. The upper central incisors and canines were shorter in comparison to the control group. Aesthetic closing of the diastema requires not only widening the crowns of the front teeth but also their elongation. Future studies on varied and bigger diastematic population groups might further establish the usefulness of odontometric measurements of maxillary anterior teeth i.e. in gender determination.

## REFERENCES

- Agarwal A, Gokhal ST, Bhattacharya HSA. Two way periodontal approach for preventing relapse in midline diastema cases. *Indian J Dent Sci.* 2014; 6(3): 71–73.
- Agenter MK, Harris EF, Blair RN. Influence of tooth crown size on malocclusion. *Am J Orthod Dentofacial Orthop.* 2009; 136(6): 795–804, doi: [10.1016/j.ajodo.2007.12.030](https://doi.org/10.1016/j.ajodo.2007.12.030), indexed in Pubmed: [19962602](https://pubmed.ncbi.nlm.nih.gov/19962602/).
- Ahmed KE, Murbay S. Survival rates of anterior composites in managing tooth wear: systematic review. *J Oral Rehabil.* 2016; 43(2): 145–153, doi: [10.1111/joor.12360](https://doi.org/10.1111/joor.12360), indexed in Pubmed: [26440584](https://pubmed.ncbi.nlm.nih.gov/26440584/).
- Bhattacharya P, Raju PS, Bajpai A. Prognosis v/s etiology: midline papilla reconstruction after closure of median diastema. *Ann Essences Dent.* 2011; 3(1): 37–40, doi: [10.5368/aedj.2011.3.1.1.7](https://doi.org/10.5368/aedj.2011.3.1.1.7).
- Bjork A, Krebs A, Solow B. A method for epidemiological registration of malocclusion. *Acta Odontol Scand.* 1964; 22(2): 27–41.
- Bugaighis I, Elorfi S. An odontometric study of tooth size in normal, crowded and spaced dentitions. *J Orthod Sci.* 2013; 2(3): 95–100, doi: [10.4103/2278-0203.119681](https://doi.org/10.4103/2278-0203.119681), indexed in Pubmed: [24987648](https://pubmed.ncbi.nlm.nih.gov/24987648/).
- Bulwin M, Dudzińska-Filkiewicz A, Filkiewicz Z, et al. Licówki porcelanowe wykonywane w systemie IPS. *e max Press Ma.* 2015; 25(8/7): 60–63.
- Chalas R, Orłowski M, Sękowska A. Usefulness of composite restoration in direct esthetic closure of midline gap. *Pol J Public Health.* 2014; 124(2): 89–92, doi: [10.2478/pjph-2014-0020](https://doi.org/10.2478/pjph-2014-0020).
- da Cunha LF, Kintopp Cd, Baechtold MS, et al. Premium protocol for planning a periodontal-restorative approach: Conservative, predictable, and reproducible. *Quintessence Int.* 2017; 48(7): 549–554, doi: [10.3290/j.qi.a38265](https://doi.org/10.3290/j.qi.a38265), indexed in Pubmed: [28512651](https://pubmed.ncbi.nlm.nih.gov/28512651/).
- De Araujo EM, Fortkamp S, Baratieri LN. Closure of diastema and gingival recontouring using direct adhesive restorations: a case report. *J Esthet Restor Dent.* 2009; 21(4): 229–240, doi: [10.1111/j.1708-8240.2009.00267.x](https://doi.org/10.1111/j.1708-8240.2009.00267.x), indexed in Pubmed: [19689720](https://pubmed.ncbi.nlm.nih.gov/19689720/).
- Delli K, Livas C, Sculean A, et al. Facts and myths regarding the maxillary midline frenum and its treatment: a systematic review of the literature. *Quintessence Int.* 2013; 44(2): 177–187, doi: [10.3290/j.qi.a28925](https://doi.org/10.3290/j.qi.a28925), indexed in Pubmed: [23444184](https://pubmed.ncbi.nlm.nih.gov/23444184/).
- Erdemir U, Yildiz E. *Esthetic and Functional Management of Diastema: A Multidisciplinary Approach.* Springer International Publishing; 2015.
- Fernandes de Morais J, de Freitas MR, Freitas K, et al. Maxillary incisors mesiodistal angulation changes in patients with orthodontically treated anterior superior diastemas. *Dental Press J Orthod.* 2012; 17(4): 65–71, doi: [10.1590/s2176-94512012000400015](https://doi.org/10.1590/s2176-94512012000400015).
- Frese C, Schiller P, Staehle HJ, et al. Recontouring teeth and closing diastemas with direct composite buildups: a 5-year follow-up. *J Dent.* 2013; 41(11): 979–985, doi: [10.1016/j.jdent.2013.08.009](https://doi.org/10.1016/j.jdent.2013.08.009), indexed in Pubmed: [23954577](https://pubmed.ncbi.nlm.nih.gov/23954577/).
- Gillen RJ, Schwartz RS, Hilton TJ, et al. An analysis of selected normative tooth proportions. *Int J Prosthodont.* 1994; 7(5): 410–417, indexed in Pubmed: [7802908](https://pubmed.ncbi.nlm.nih.gov/7802908/).
- Gkantidis N, Kolokitha OE, Topouzelis N. Management of maxillary midline diastema with emphasis on etiology. *J Clin Pediatr Dent.* 2008; 32(4): 265–272, doi: [10.17796/jcpd.32.4.j087t33221771387](https://doi.org/10.17796/jcpd.32.4.j087t33221771387), indexed in Pubmed: [18767455](https://pubmed.ncbi.nlm.nih.gov/18767455/).
- Greinke M. Diastema i wędzidełko wargi górnej w aspekcie leczenia ortodontycznego. *Mag Stomatol.* 2013; 23(12): 86–89.
- Hasanreisoglu U, Berksun S, Aras K, et al. An analysis of maxillary anterior teeth: facial and dental proportions. *J Prosthet Dent.* 2005; 94(6): 530–538, doi: [10.1016/j.prosdent.2005.10.007](https://doi.org/10.1016/j.prosdent.2005.10.007), indexed in Pubmed: [16316799](https://pubmed.ncbi.nlm.nih.gov/16316799/).
- Hashim HA, Al-Ghamdi S. Tooth width and arch dimensions in normal and malocclusion samples: an odontometric study. *J Contemp Dent Pract.* 2005; 6(2): 36–51, indexed in Pubmed: [15915203](https://pubmed.ncbi.nlm.nih.gov/15915203/).
- Huang WJ, Creath CJ. The midline diastema: a review of its etiology and treatment. *Pediatr Dent.* 1995; 17(3): 171–179, indexed in Pubmed: [7617490](https://pubmed.ncbi.nlm.nih.gov/7617490/).
- Jaija AM, El-Beialy AR, Mostafa YA. Revisiting the Factors Underlying Maxillary Midline Diastema. *Scientifica (Cairo).* 2016; 2016: 5607594, doi: [10.1155/2016/5607594](https://doi.org/10.1155/2016/5607594), indexed in Pubmed: [27239374](https://pubmed.ncbi.nlm.nih.gov/27239374/).
- Lenhard M. Closing diastemas with resin composite restorations. *Eur J Esthet Dent.* 2008; 3(3): 258–268, indexed in Pubmed: [19655542](https://pubmed.ncbi.nlm.nih.gov/19655542/).
- Magne P, Gallucci G, Belser U. Anatomic crown width/length ratios of unworn and worn maxillary teeth in white subjects. *J Prosthet Dent.* 2003; 89(5): 453–461, doi: [10.1016/s0022-3913\(03\)00125-2](https://doi.org/10.1016/s0022-3913(03)00125-2).
- Morais JF, Freitas MR, Freitas KM, et al. Postretention stability after orthodontic closure of maxillary interincisor diastemas. *J Appl Oral Sci.* 2014; 22(5): 409–415, doi: [10.1590/1678-77520130472](https://doi.org/10.1590/1678-77520130472), indexed in Pubmed: [24918661](https://pubmed.ncbi.nlm.nih.gov/24918661/).
- Oesterle LJ, Shellhart WC. Maxillary midline diastemas: a look at the causes. *J Am Dent Assoc.* 1999; 130(1): 85–94, doi: [10.14219/jada.archive.1999.0033](https://doi.org/10.14219/jada.archive.1999.0033), indexed in Pubmed: [9919036](https://pubmed.ncbi.nlm.nih.gov/9919036/).
- Onyeaso C. Prevalence of malocclusion among adolescents in Ibadan, Nigeria. *Am J Orthod Dentofac Orthop.* 2004; 126(5): 604–607, doi: [10.1016/j.ajodo.2003.07.012](https://doi.org/10.1016/j.ajodo.2003.07.012).
- Osmólska-Bogucka AE, Siemińska-Piekarczyk B. Maxillary median diastema – review of the literature. *Dent Med Probl.* 2015; 52(3): 341–344.
- Papathanasiou A, Asikis C. Life-Changing diastema closure direct composite restorations with minimal intervention. *J Cosmet Dent.* 2015; 31(1): 46–56.
- Puri N, Pradhan KL, Chandna A, et al. Biometric study of tooth size in normal, crowded, and spaced permanent dentitions. *Am J Orthod Dentofacial Orthop.* 2007; 132(3):

- 279.e7–279.14, doi: [10.1016/j.ajodo.2007.01.018](https://doi.org/10.1016/j.ajodo.2007.01.018), indexed in Pubmed: [17826594](https://pubmed.ncbi.nlm.nih.gov/17826594/).
30. Sękowska A, Dunin-Wilczyńska I, Chałas R. The size of anterior teeth in patients with gaps in the upper dental arch. *Folia Morphol.* 2015; 74(4): 493–496, doi: [10.5603/FM.2015.0113](https://doi.org/10.5603/FM.2015.0113), indexed in Pubmed: [26620511](https://pubmed.ncbi.nlm.nih.gov/26620511/).
31. Sterrett JD, Oliver T, Robinson F, et al. Width/length ratios of normal clinical crowns of the maxillary anterior dentition in man. *J Clin Periodontol.* 1999; 26(3): 153–157, doi: [10.1034/j.1600-051x.1999.260304.x](https://doi.org/10.1034/j.1600-051x.1999.260304.x), indexed in Pubmed: [10100040](https://pubmed.ncbi.nlm.nih.gov/10100040/).
32. Suter VGA, Heinzmann AE, Grossen J, et al. Does the maxillary midline diastema close after frenectomy? *Quintessence Int.* 2014; 45(1): 57–66, doi: [10.3290/j.qi.a30772](https://doi.org/10.3290/j.qi.a30772), indexed in Pubmed: [24392496](https://pubmed.ncbi.nlm.nih.gov/24392496/).
33. Thilander B, Pena L, Infante C, et al. Prevalence of malocclusion and orthodontic treatment need in children and adolescents in Bogota, Colombia. An epidemiological study related to different stages of dental development. *Eur J Orthod.* 2001; 23(2): 153–167, doi: [10.1093/ejo/23.2.153](https://doi.org/10.1093/ejo/23.2.153), indexed in Pubmed: [11398553](https://pubmed.ncbi.nlm.nih.gov/11398553/).
34. Wheeler B, Carrico CK, Shroff B, et al. Management of the Maxillary Diastema by Various Dental Specialties. *J Oral Maxillofac Surg.* 2018; 76(4): 709–715, doi: [10.1016/j.joms.2017.11.024](https://doi.org/10.1016/j.joms.2017.11.024), indexed in Pubmed: [29245001](https://pubmed.ncbi.nlm.nih.gov/29245001/).