

# Position and size of massa intermedia in Serbian brains

M.N. Pavlović<sup>1</sup>, I.D. Jovanović<sup>1</sup>, S.Z. Ugrenović<sup>1</sup>, A.V. Kostić<sup>2</sup>, B.K. Kundalić<sup>1</sup>, V.R. Stojanović<sup>1</sup>, S. Vlajković<sup>1</sup>, M.M. Trandafilović<sup>1</sup>, J.R. Čukuranović-Kokoris<sup>1</sup>, M.M. Antić<sup>1</sup>

<sup>1</sup>Medical Faculty, University of Nis, Serbia and Montenegro

<sup>2</sup>Neurosurgery Clinic, Clinical Centre Nis, Serbia and Montenegro

[Received: 24 November 2018; Accepted: 28 February 2019]

**Background:** *Massa intermedia*, a midline bar-shaped structure, connects two thalami across the third ventricle in 70–80% of healthy humans. It has become clinically important since its absence was comprehended as a midline malformation of the brain and brought in connection with schizophrenia indicating that some symptoms could be a consequence of disturbed neuron chains underlying the mechanisms of attention and processing of information. The aim of the investigation was to find out the incidence, position, and size of *massa intermedia* in the brains of the Serbian population.

**Materials and methods:** Our investigation was performed on 41 brains of adult Serbian cadavers using a macro dissection method.

**Results:** *Massa intermedia* was present in 80.49% of cases, in 1 case it was double. In most of the cases it was located in the superior quadrants of the lateral wall of the third ventricle, the larger part being in the anterosuperior one. Some other combinations were also present. The horizontal diameter of the cross-section was larger than vertical and was not in correlation with the length of the third ventricle. The average cross-sectional area was 29.58 mm<sup>2</sup>, significantly larger in females.

**Conclusions:** *Massa intermedia* is present in most of the investigated brains, usually connecting the anterior-superior quadrants of the lateral walls of the third ventricle. Different in shape and size its cross-section is a horizontal ellipse, significantly larger in females. The cross-sectional area and the size of the third ventricle are not in correlation. (Folia Morphol. 2020; 79, 1: 21–27)

**Key words:** *adhesio interthalamica*, human brains, cadaver, incidence, position, thalamus

## INTRODUCTION

Medial surfaces of the right and left thalami are usually connected with a flattened bar of neural substance marked as *massa intermedia* (MI) (also referred to as the interthalamic adhesion s. *commissura cinerea* s. *commissura grisea*). It spans the third ventricle behind the interventricular foramen. In the lower mammals, MI is quite a big structure, while in

humans its length is about 1 cm. *Massa intermedia* is absent in 15–25 of healthy humans [4] and seems to be more frequently absent in males than in females [14, 19]. In rare cases, it can be even double [14, 31]. It contains commissural fibers and neurons [14, 21]. *Massa intermedia* appears during early development of the embryo, when the thalami, while increasing in size, gradually approach and eventually meet one an-

other over a variable area, between the 13<sup>th</sup> and 14<sup>th</sup> week of gestation. The area of connection prolongs in a bar, interthalamic adhesion, under the pressure of cerebrospinal fluid collected in the third ventricle [7].

Massa intermedia was reported to be more often absent in schizophrenia compared with healthy subjects [19, 25, 27], possibly reflecting its neurodevelopmental pathology. Namely, some studies have found the connection between midline cerebral malformations (cavum septipelucidi, agenesis of the corpus callosum, the absence of MI) and schizophrenia, indicating that some symptoms of schizophrenia may develop as a result of lesions of the midline neural circuits which moderate attention and processing of information [19, 25].

The aim of our study was to determine the incidence, size and position of MI in Serbian brains. We also wanted to find out if there was some relation between the sizes of MI and the third ventricle.

## MATERIALS AND METHODS

The investigation was performed on the brains of 41 adult persons (19 males and 22 females, aged 33–95 years), who had died accidentally, without data or signs of visible neuropathological changes. The brains were removed by standard autopsy technique. A sagittal slice, which included interhemispheric fissure and 1 cm of the brain tissue on each side, was taken from each brain. The slices were fixed in 10% neutral formaldehyde for a period of 3 weeks. After that, a sagittal section of each fixed slice was performed through the interhemispheric fissure, corpus callosum and third ventricle, between the thalami. On that occasion, MI, that had connected the thalami, was cut.

First of all, we determined if MI was present or not. All the cases were photographed. The cases without MI as well as one case with two MIs were excluded from the further procedure.

The size of MI in our investigation referred to the size of the midsagittal sectional area of MI only, not to the length of the same structure, which was not always easy to measure. To assess the size of the cross-section of MI, its horizontal (H) and vertical diameters (V) were measured, and the cross-sectional area (S) was calculated.

The cross-sectional area of MI was compared with the distance between the anterior and posterior cerebral commissures (CA-CP distance), in order to find out whether the size of MI depended on the length of the third ventricle.

In order to make the position of MI more obvious, the coordinate system was constructed on the lateral wall of the third ventricle, on each photo. The X-axis of the system passed through anterior and posterior cerebral commissures; the ordinate intercepted the midpoint of that distance.

## Statistical analysis

Data are presented as mean  $\pm$  standard deviation or frequency, with  $p \leq 0.05$  indicating statistical significance. Comparisons between groups were made using the Mann-Whitney test and the  $\chi^2$  test, for nominal variables and for categorical data, respectively. All analyses were performed using the SPSS 14.0 software.

## RESULTS

Massa intermedia was found in 33 out of 41 brains (80.49%) (Fig. 1A), in 15 out of 19 male (78.95%) and in 18 out of 22 female brains (81.82%). In 8 out of all cases (19.51%) MI was absent (Fig. 1B), in 4 (21.05%) male and 4 (18.18%) female brains. There was no significant relationship between the incidence of MI and gender ( $p = 0.869$ ) (Table 1). In 32 out of 33 cases MI was single (96.97%), in 1 (3.03%) case it was double (Fig. 1C).

Massae intermediae were of different shapes and sizes (Fig. 1D–G).

The horizontal diameter of MI was between 2.50 and 12.00 mm (average  $8.27 \pm 2.21$  mm), and in all cases, it was longer than the vertical one which was between 1.50 and 6.00 mm, (average  $4.14 \pm 1.03$  mm).

Average cross-sectional area (S) of MI was  $29.81 \pm 12.49$  mm<sup>2</sup>. The largest S was 56.50 mm<sup>2</sup> (Fig. 1D); the smallest 3.53 mm<sup>2</sup> (Fig. 1E). In the case of the largest S left and right thalami were so close that their medial surfaces were touching one another. Most of the S were between 20.00 and 40.00 mm<sup>2</sup>, almost equally distributed between 20.00 and 30.00 mm<sup>2</sup> and 30.00 and 40.00 mm<sup>2</sup>. The average S of MI in females was significantly larger than in males,  $34.13 \pm 11.57$  mm<sup>2</sup> vs.  $24.12 \pm 11.34$  mm<sup>2</sup> ( $p = 0.021$ ) (Fig. 2A).

The average distance between CA and CP was  $25.94 \pm 2.33$  mm. The longest MI is presented on the Figure 1G. There was no significant correlation between the length of the third ventricle (CA-CP distance) and the cross-sectional area of MI ( $r = 0.31$ ,  $p = 0.866$ ) (Table 2).

When present, MI was mostly located in the anterosuperior quadrant. In only 2 (5.13%) cases it was entirely located in the anterosuperior quadrant and in both cases it was rather small MI (Fig. 1H). In 16 (41.02%) cases, it was mainly located in the an-



**Figure 1.** Massa intermedia (MI) in Serbian brains — appearance: **A.** Single MI; **B.** Absence of MI; **C.** Double MI in a 56-year-old female; different shapes and sizes of MI; **D.** Large MI in a 51-year-old female; **E.** Tiny MI in an 81-year-old male; **F.** Large but short MI in a 76-year-old female; **G.** Long MI in an 80-year-old female; position of MI; **H.** MI located in the anterosuperior quadrant; **I.** MI located mainly in the anterosuperior, partly in posterosuperior quadrant; **J.** MI equally located in the anterosuperior and posterosuperior quadrant; **K.** MI located in all four quadrants, mostly in anterosuperior.

**Table 1.** The incidence of massa intermedia (MI)

	Presence of MI	Absence of MI
Male	15 (78.95%)	4 (21.05%)
Female	18 (81.82%)	4 (18.18%)
Total	33 (80.49%)	8 (19.51%)

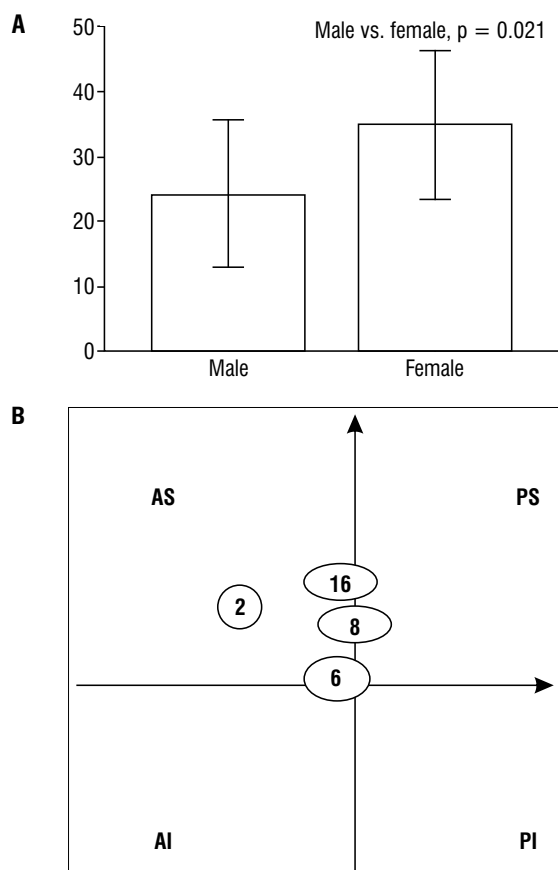
terosuperior quadrant; its caudal part exceeded the posterosuperior quadrant (Fig. 1D). In 11 (28.21%) cases MI was equally located in the anterosuperior and posterosuperior quadrants (Fig. 1J), and in 10 (25.64%) cases it was located almost in the centre of the lateral wall of the third ventricle (Fig. 1K). Distribution of all MI was presented in the Figure 2B.

## DISCUSSION

Massa intermedia, which links the two thalami across the third ventricle of the brain, appears between 13<sup>th</sup> and 14<sup>th</sup> week of development [7]. This

link between the two thalami is well developed in mammals, but variable in size among individuals and missing in about 20% of human brains [4]. It contains commissural fibres that connect some nuclei of the left and right thalami, as well as the neurons grouped into its proper nuclei [14, 21]. The precise role of the MI is not known but it is believed that, along with other midline structures, MI participates in the formation of the central neural circuits that underlie attention and information processing [25]. It also participates in the modulation of electrocortical activities across the hemispheres. On that basis, it gains clinical importance in the propagation of epileptic discharges to the temporal limbic regions [12, 30].

There are very limited data about MI in certain populations in the literature. In our research, MI was absent in 19.51% of Serbian brains. The absence of MI was found in only 11.6% of Korean brains [20]. Even less, the absence of MI has recorded in 5.8% of



**Figure 2.** Surface area and distribution of massa intermedia (MI); **A.** Surface area of MI in male and female; **B.** Distribution of positions of MI; AS — anterosuperior quadrant; PS — posterosuperior quadrant; AI — anteroinferior quadrant; PI — posteroinferior quadrant.

**Table 2.** Morphological parameters indicating the size of massa intermedia (MI) and third ventricle

	Mean $\pm$ SD	Min–max
Horizontal diameter of MI [mm]	8.27 $\pm$ 2.21	2.5–12.00
Vertical diameter of MI [mm]	4.14 $\pm$ 1.03	1.50–6.00
Surface area of MI [mm <sup>2</sup> ]	29.81 $\pm$ 12.49	3.53–56.50
CA-CP distance [mm]	25.94 $\pm$ 2.33	22.0–31.00

CA-CP distance — distance between the anterior and posterior cerebral commissures; max — maximum; min — minimum; SD — standard deviation

Japanese brains [24]. The great difference between our results may be a racial difference but also a result of a relatively small number of samples. The absence of MI in 19.51% of Serbian brains is in line with most of the literature findings [4, 22]. Some authors have found a smaller percentage of the absence of MI [10, 11, 20]. The largest percentage of the absence of MI

was around 22% [14] and the smallest, of 8.7% [23] found in an magnetic resonance imaging (MRI) study. It was proposed that absence of MI may be related to neurodevelopmental alterations in the growing process of surrounding structures during early gestation [32]. Developmental risk factors as maternal viral infection or malnutrition in that period may have their effect on the susceptibility to schizophrenia [26, 32].

Some authors proposed that patients without MI might have reduced competition between lateralised functions of the two hemispheres, or might have greater resistance to neurological impairment. Patients without MI showed poorer scores on some neuropsychological tasks. While it is difficult to establish the meaning of cognitive deficits in relation to MI absence, these findings could be possibly related to thalamic alterations followed with an absent MI [30].

Sexual dimorphism of MI is already recorded. Our investigation showed fewer women with absence of MI (18.18%) than men (21.05%); however, the difference was not significant. The far larger difference in absence of MI between female and male was found by Nopoulos et al. (2001) [19] and Ceyhan et al. (2008) [6] (13.56% vs. 32.08%; 6.0% vs. 23.1%). Allen and Gorski (1991) [2] also reported that women are more likely to have MI than men. The more frequent absence of MI in males than in females in most studies suggests an important structural difference in connection of two hemispheres as an underlying factor for gender-related difference of cognitive function [11, 13].

Cases of double MI also occurred. It was not always clear whether this was indeed a double MI or fenestration on it [3, 14, 31]. In our study, we found one case of the double MI, which makes 3% of our Serbian brains. Variability in size and shape of the MI is well known to brain surgeons who are dealing with endoscopic ventriculostomy.

Massa intermedia, or rather its absence, has gained importance in the last decade, as some studies have linked its absence with malformations of midline structures of the brain, such as cavum septipellucidum, cavum vergae, agenesis of corpus callosum, enlargement of third ventricle etc. Although its function in humans is not clear, animal studies have shown that MI is involved in the regulation of dopamine release of the basal ganglia [27]. It is believed that these conditions cause schizophrenia because of disruption of neural circuits that mediate attention and information processing [9, 18, 25] which might be core

components of the vulnerability to schizophrenia. In that context, the absence of MI would be considered an early sign of risk factors that could be associated with the future manifestation of schizophrenia [10, 20, 25, 27]. Starting from this background, some authors have carried out research in healthy subjects and patients with schizophrenia. However, results were conflicting. Using MRI some of them have found out that a larger number of schizophrenic persons than healthy people miss MI [10, 19, 25, 27, 29]. Additionally, the results of studies of Erbagci et al. (2002) [10], Shimizu et al. (2008) [24] and Haghiri et al. (2013) [11] did not show the difference between male and female patients. On the contrary, de Souza Crippa et al. (2006) [8] found that absent MI is equally common among patients and controls, more prevalent in male than in female patients with schizophrenia. Interestingly, schizophrenia patients without MI also had a smaller bilateral amygdala [28] and thalami [24].

However, there are differences in the results obtained with MRI studies and post-mortem studies. Namely, in a combined study Snyder et al. (1998) [25], using MRI as a method, came to similar results in terms of the absence of MI in schizophrenic patients and healthy people, while in postmortal study they found a higher percentage of absence of MI in schizophrenics than in healthy controls. It is possible that MRI does have some methodological limitations since MI is a small structure [24], or differences may appear due to the fact that all researchers use a relatively small number of cases. On the other hand, some other authors did not find any difference in the presence or absence of MI in healthy and schizophrenic people in the research based on MRI technique [5, 17, 24].

In our research, MI was located either completely or predominantly in the anterior upper quadrant (74.36%), which is consistent with the findings of Malobabić et al. (1987) [14]. In the rest of the cases (25.64%) MI was located in the middle of the lateral wall.

In a limited number of cases, we found a huge variety of MI area size. Average cross-sectional area of MI was  $29.81 \pm 12.49 \text{ mm}^2$ . The largest surface area was  $56.50 \text{ mm}^2$  and the smallest  $3.53 \text{ mm}^2$ . It is much more than in the findings of Malobabić et al. [14] who had investigated 50 brains and recorded an average area of  $13.1 \text{ mm}^2$ . Even larger MI was found by Nayak and Soumya (2010) [17], with a horizontal diameter as long as 30 mm compared to the largest one in our research which was 12 mm.

Comparing the surface area of MI in males and females, most of the authors have found larger area size of MI in females than in males [2, 6], despite the fact that male brain was larger than female. We also found a difference between the cross-sectional area in males and females. In females, it was  $34.13 \pm 11.57 \text{ mm}^2$ , while in males it was significantly smaller,  $24.12 \pm 11.34 \text{ mm}^2$ . It is not known when the sexual differentiation occurs. It is believed that morphological brain differences can cause functional sex differences in cognitive functions and cerebral lateralisation [2].

We did not measure the length of MI because of the difficult access. The other researchers who investigated MI also did not report on its length, presumably for the same reason. It is easier to measure the length of MI using MRI. It was found that the length of MI was around 3.00 mm and it was not significantly longer in men than in women [19]. However, other investigators reported MI to be shorter in males [27, 29]; so, the results were conflicting. It has been stated that prolonged MI is found in Chiari II malformation and hydrocephalus associated with myeloschisis [16, 31].

We didn't find a correlation between the cross-sectional size of MI and the length of the third ventricle. No previous studies have found a relationship between the development of MI and the size of the thalami or brain weight [1, 13]. The total volumes of the third ventricle also didn't differ in healthy subjects or schizophrenic patients and regarding the presence or absence of MI respectively [10].

In the already small number of studies of MI, it is seldom spoken about the age changes. In the publication about duplication of MI, Tubbs et al. (2004) [31] quotes Rosales et al. (1968) [22] that MI is subjected to atrophy with age and that in older people it can disappear [15, 25]. Sen et al. (2005) [23] also stated that it is the longest after 60 years of age.

As previously stated, we did not measure the lengths of MIs but obviously the longest one belonged to a person who was 80 years old. Perhaps the general atrophy of the brain in the old age causes enlargement of the ventricles increasing the distance between the thalami which leads to the prolongation of the MI. It is more obvious in the persons with pronounced atrophy.

Finally, in spite of still obscure function of the MI, knowing its morphology, position and variability are of special interest in neurosurgery [5]. Although modern imaging methods enable exploration of MI,

the combination with post mortal morphological and pathohistological methods is still the most secure in gaining more detailed knowledge about this structure.

## CONCLUSIONS

Massa intermedia is present in 80.49% of Serbian brains, more often in the female (81.82%) than in male (78.95%) brains. It is most commonly found in the anterior upper quadrant, above the line connecting the anterior and posterior cerebral commissures and in front of the vertical passing through its middle. Massa intermedia in all Serbian brains had a cross-section in the shape of a horizontal ellipse, its cross-sectional area being  $28.7 \pm 12.2 \text{ mm}^2$ . The surface area of MI was significantly larger in the females than in the males. There was no significant correlation between the MI size area and the length of the third ventricle.

## Acknowledgements

This paper was supported by the Internal Projects of Medical Faculty of Niš No. 15 and No. 22 and by the Ministry of Science and Technological Development of the Republic of Serbia (TR 31060 and 41018).

## REFERENCES

- Agarwal N, Rambaldelli G, Perlini C, et al. Microstructural thalamic changes in schizophrenia: a combined anatomic and diffusion weighted magnetic resonance imaging study. *J Psychiatry Neurosci*. 2008; 33(5): 440–448, indexed in Pubmed: [18787663](#).
- Allen LS, Gorski RA. Sexual dimorphism of the anterior commissure and massa intermedia of the human brain. *J Comp Neurol*. 1991; 312(1): 97–104, doi: [10.1002/cne.903120108](#), indexed in Pubmed: [1744245](#).
- Baydin S, Gungor A, Baran O, et al. The double massa intermedia. *Surg Neurol Int*. 2016; 7: 30, doi: [10.4103/2152-7806.179383](#), indexed in Pubmed: [27127695](#).
- Carpenter MB. *Thalamus in: core text of neuroanatomy*. 4th ed. Williams&Wilkins, Baltimore 1996: 49–50.
- Cataltepe O. Endoscopic third ventriculostomy: indications, surgical technique, and potential problems. *Turk Neurosurg*. 2002; 12: 65–73.
- Ceyhan M, Adapinar B, Aksaray G, et al. Absence and size of massa intermedia in patients with schizophrenia and bipolar disorder. *Acta Neuropsychiatr*. 2008; 20(4): 193–198, doi: [10.1111/j.1601-5215.2008.00296.x](#), indexed in Pubmed: [25385654](#).
- Collins P. Embriology and development. In: Williams PL (ed.) *Gray's anatomy*. 38th ed. Churchill Livingstone, London 1995: 91–328.
- Di Rocco C. Massa intermedia: mental development. *Childs Nerv Syst*. 2005; 21(12): 1013–1017, doi: [10.1007/s00381-005-1265-7](#), indexed in Pubmed: [16249940](#).
- de Souza Crippa JA, Zuairi AW, Busatto GF, et al. Cavum septum pellucidum and adhesio interthalamica in schizophrenia: an MRI study. *Eur Psychiatry*. 2006; 21(5): 291–299, doi: [10.1016/j.eurpsy.2005.09.010](#), indexed in Pubmed: [16406503](#).
- Erbađci H, Yildirim H, Herken H, et al. A magnetic resonance imaging study of the adhesio interthalamica in schizophrenia. *Schizophr Res*. 2002; 55(1-2): 89–92, doi: [10.1016/s0920-9964\(01\)00199-2](#), indexed in Pubmed: [11955967](#).
- Haghir H, Mokhber N, Azarpazhooh MR, et al. A magnetic resonance imaging study of adhesio interthalamica in clinical subtypes of schizophrenia. *Indian J Psychiatry*. 2013; 55(2): 135–139, doi: [10.4103/0019-5545.111450](#), indexed in Pubmed: [23825846](#).
- Hirayasu Y, Wada JA. N-methyl-D-aspartate injection into the massa intermedia facilitates development of limbic kindling in rats. *Epilepsia*. 1992; 33(6): 965–970, doi: [10.1111/j.1528-1157.1992.tb01745.x](#), indexed in Pubmed: [1464279](#).
- Ligier Y, Ratib O, Logean M, et al. Osiris: a medical image-manipulation system. *MD Comput*. 1994; 11(4): 212–218, indexed in Pubmed: [8072405](#).
- Malobabić S, Puskas L, Blagotić M. Size and position of the human adhaesio interthalamica. *Gegenbaurs Morphol Jahrb*. 1987; 133(1): 175–180, indexed in Pubmed: [3569816](#).
- Meisenzahl EM, Frodl T, Zetzsche T, et al. Adhesio interthalamica in male patients with schizophrenia. *Am J Psychiatry*. 2000; 157(5): 823–825, doi: [10.1176/appi.ajp.157.5.823](#), indexed in Pubmed: [10784480](#).
- Mori H, Oi S, Nonaka Y, et al. Ventricular anatomy of hydrocephalus associated with myeloschisis and endoscopic third ventriculostomy. *Childs Nerv Syst*. 2008; 24(6): 717–722, doi: [10.1007/s00381-007-0547-7](#), indexed in Pubmed: [18188572](#).
- Nayak SB, Soumya KV. Unusually large interthalamic adhesion and its clinical importance. *Int J Anat Var*. 2010; 3: 174–175.
- Nopoulos P, Swayze V, Flaum M, et al. Cavum septi pellucidi in normals and patients with schizophrenia as detected by magnetic resonance imaging. *Biol Psychiatry*. 1997; 41(11): 1102–1108, doi: [10.1016/S0006-3223\(96\)00209-0](#), indexed in Pubmed: [9146821](#).
- Nopoulos PC, Rideout D, Crespo-Facorro B, et al. Sex differences in the absence of massa intermedia in patients with schizophrenia versus healthy controls. *Schizophr Res*. 2001; 48(2-3): 177–185, doi: [10.1016/s0920-9964\(00\)00067-0](#), indexed in Pubmed: [11295371](#).
- Park K, Lee H, Chung I, et al. A morphologic study of interthalamic adhesions in Korean brains. *Clini Anat*. 1993; 6(1): 33–36, doi: [10.1002/ca.980060106](#).
- Puskas L, Malobabić S, Puskas N, et al. Specific circular organization of the neurons of human interthalamic adhesion and of periventricular thalamic region. *Int J Neurosci*. 2005; 115(5): 669–679, doi: [10.1080/00207450590524340](#), indexed in Pubmed: [15823931](#).
- Rosales RK, Lemay MJ, Yakovlev PI. The development and involution of massa intermedia with regard to age and sex. *J Neuropathol Exp Neurol*. 1968; 27(1): 166, indexed in Pubmed: [5301516](#).

23. Sen F, Ulabay H, Ozeksi P, et al. Morphometric measurements of the thalamus and interhemispheric adhesion by MR imaging. *Neuroanat.* 2005; 4: 10–12.
24. Shimizu M, Fujiwara H, Hirao K, et al. Structural abnormalities of the adhesio interthalamica and mediodorsal nuclei of the thalamus in schizophrenia. *Schizophr Res.* 2008; 101(1-3): 331–338, doi: [10.1016/j.schres.2007.12.486](https://doi.org/10.1016/j.schres.2007.12.486), indexed in Pubmed: [18242957](https://pubmed.ncbi.nlm.nih.gov/18242957/).
25. Snyder PJ, Bogerts B, Wu H, et al. Absence of the adhesio interthalamica as a marker of early developmental neuropathology in schizophrenia: an MRI and postmortem histologic study. *J Neuroimaging.* 1998; 8(3): 159–163, doi: [10.1111/jon199883159](https://doi.org/10.1111/jon199883159), indexed in Pubmed: [9664852](https://pubmed.ncbi.nlm.nih.gov/9664852/).
26. Susser E, Brown AS, Klonowski E, et al. Schizophrenia and impaired homocysteine metabolism: a possible association. *Biol Psychiatry.* 1998; 44(2): 141–143, doi: [10.1016/s0006-3223\(97\)00427-7](https://doi.org/10.1016/s0006-3223(97)00427-7), indexed in Pubmed: [9646897](https://pubmed.ncbi.nlm.nih.gov/9646897/).
27. Takahashi T, Suzuki M, Zhou SY, et al. Prevalence and length of the adhesio interthalamica in schizophrenia spectrum disorders. *Psychiatry Res.* 2008; 164(1): 90–94, doi: [10.1016/j.psychres.2008.03.001](https://doi.org/10.1016/j.psychres.2008.03.001), indexed in Pubmed: [18790617](https://pubmed.ncbi.nlm.nih.gov/18790617/).
28. Takahashi T, Suzuki M, Nakamura K, et al. Association between absence of the adhesio interthalamica and amygdala volume in schizophrenia. *Psychiatry Res.* 2008; 162(2): 101–111, doi: [10.1016/j.psychres.2007.04.005](https://doi.org/10.1016/j.psychres.2007.04.005), indexed in Pubmed: [18226506](https://pubmed.ncbi.nlm.nih.gov/18226506/).
29. Trzesniak C, Kempton MJ, Busatto GF, et al. Adhesio interthalamica alterations in schizophrenia spectrum disorders: a systematic review and meta-analysis. *Prog Neuropsychopharmacol Biol Psychiatry.* 2011; 35(4): 877–886, doi: [10.1016/j.pnpbp.2010.12.024](https://doi.org/10.1016/j.pnpbp.2010.12.024), indexed in Pubmed: [21300129](https://pubmed.ncbi.nlm.nih.gov/21300129/).
30. Trzesniak C, Linares IM, Coimbra ÉR, et al. Adhesio interthalamica and cavum septum pellucidum in mesial temporal lobe epilepsy. *Brain Imaging Behav.* 2016; 10(3): 849–856, doi: [10.1007/s11682-015-9461-x](https://doi.org/10.1007/s11682-015-9461-x), indexed in Pubmed: [26497889](https://pubmed.ncbi.nlm.nih.gov/26497889/).
31. Tubbs RS, Smyth MD, Oakes WJ, et al. Duplication of the massa intermedia in a child. *Pediatr Neurosurg.* 2004; 40(1): 42–43, doi: [10.1159/000076578](https://doi.org/10.1159/000076578), indexed in Pubmed: [15007230](https://pubmed.ncbi.nlm.nih.gov/15007230/).
32. Wright P, Takei N, Rifkin L, et al. Maternal influenza, obstetric complications, and schizophrenia. *Am J Psychiatry.* 1995; 152(12): 1714–1720, doi: [10.1176/ajp.152.12.1714](https://doi.org/10.1176/ajp.152.12.1714), indexed in Pubmed: [8526235](https://pubmed.ncbi.nlm.nih.gov/8526235/).