

Concurrent lumbosacral and sacrococcygeal fusion: a rare aetiology of low back pain and coccygodynia?

S. Kapetanakis¹, G. Gkasdaris¹, P. Pavlidis², P. Givissis³

¹Spine Department and Deformities, Interbalkan European Medical Centre, Thessaloniki, Greece

²Laboratory of Forensic Sciences, School of Medicine, Democritus University of Thrace, Alexandroupolis, Greece

³First Orthopaedic Department of Aristotle University of Thessaloniki, Papanikolaou Hospital, Exohi, Thessaloniki, Greece

[Received: 26 May 2017; Accepted: 27 July 2017]

Sacrum is a triangular bone placed in the base of the spine and formed by the synostosis of five sacral vertebrae (S1–S5). Its upper part is connected with the inferior surface of the body of L5 vertebra forming the lumbosacral joint, while its lower part is connected with the base of the coccyx forming the sacrococcygeal symphysis, an amphiarthrodial joint. The existence of four pairs of sacral foramina in both anterior and posterior surface of the sacrum is the most common anatomy. Nevertheless, supernumerary sacral foramina are possible to be created by the synostosis of lumbosacral joint or sacrococcygeal symphysis. We present a case of an osseous cadaveric specimen of the sacrum belonging to a 79-year-old Caucasian woman. A rare variation of the anatomy of the sacrum is reported; in which, the simultaneous fusion of the sacrum with both the L5 vertebra and the coccyx has created six pairs of sacral foramina. This variation should be taken into serious consideration, especially in the domain of radiology, neurosurgery, orthopaedics and spine surgery, because low back pain, coccygodynia and other neurological symptoms may emerge due to mechanical compression. (Folia Morphol 2018; 77, 2: 397–399)

Key words: sacralisation, fusion, lumbar vertebra, coccyx, low back pain, coccygodynia

INTRODUCTION

The sacrum represents a pyramidal bone typically created by the synostosis of 5 independent sacral vertebrae [1, 3, 7]. Beginning from the age of puberty, the fusion takes place on the inferior part and continues to the superior one, leaving no residual intervertebral sacral disks during the first years of the fourth decade of human life [7]. In the most common and typical anatomy of the bone, 4 articulations are included: 2 sacroiliac joints, the lumbosacral joint and the sacrococcygeal symphysis, while 4 pairs of sacral

foramina are formed on both anterior and posterior surface of the bone [1, 3, 8].

Both the lumbosacral joint and the sacrococcygeal symphysis are related to a great amount of variations, due to a possible synostosis of the bones from which the articulation is constituted [2, 3, 5, 7]. The authors report a rare variation in which there is a concurrent synostosis of the sacral bone with the last lumbar vertebra (L5) and the coccyx. Although the cases in the literature describing synostosis of the lumbosacral joint or the sacrococcygeal symphysis,

Address for correspondence: S. Kapetanakis, MD, PhD, Orthopaedic Surgeon-Spine Surgeon, Assistant Professor in Medical School, Democritus University of Thrace, Alexandroupolis, Greece; Spine Department and Deformities, Interbalkan European Medical Centre, Thessaloniki, Greece, Postal Code: 68100, tel: +306972707384, fax: +302541067200, e-mail: stkapetanakis@yahoo.gr

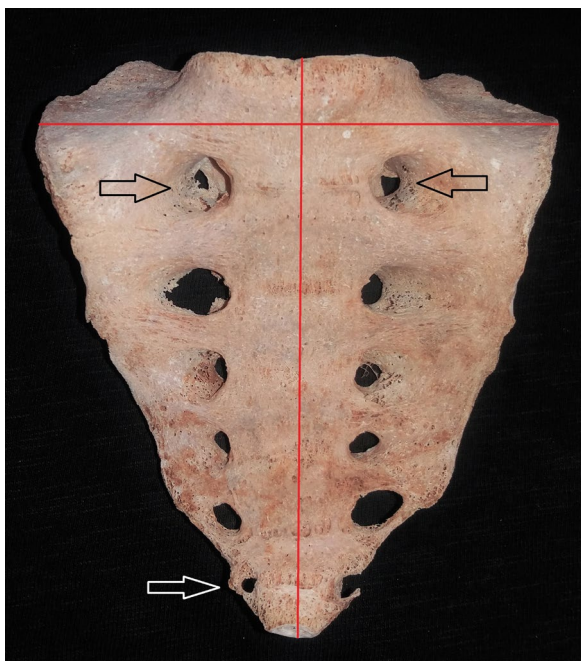


Figure 1. Anterior surface of the sacrum. A concurrent synostosis of the upper surface of the base of sacrum with the lower surface of the body of L5 and the sacral apex with the upper surface of the body of C1, creating a total of six sacral foramina can be noticed. With the red lines, we indicate the measurements of the straight length and the maximum width of the sacrum. The supernumerary foramina are also indicated (black arrows for the two superior and white arrow for the inferior right).



Figure 2. Posterior surface of the sacrum. Dual sacral-coccygeal (white arrows) and sacral-lumbar (black arrow) fusions are observed. The unilateral sacral cornua-coccygeal cornua fusion is indicated with the small white arrow and the unilateral sacrum-transverse process of coccyx fusion is indicated with the big white arrow. The posterior right side of the sacrum appears slightly damaged.

separately, with or without the existence of supernumerary sacral foramina are abundant, the presence of both of them is a rare finding. The significance of this case is dual: the 2 synostoses and the existence of 6 sacral foramina. Coccygodynia and symptoms due to neurological or biomechanical malfunction could possibly be explained by the presence of this anatomical variation [2].

CASE REPORT

Several dried human adult sacra were examined as part of a procedure of classifying the bones of our Anatomy Department. During the procedure a rare and interesting enough anatomical variation of the sacral bone was observed. Specifically, the appearance of a simultaneous synostosis of the upper surface of the base of sacrum with the lower surface of the body of L5 and the sacral apex with the upper surface of the body of C1, creating a total of 6 sacral foramina was noticed. Dual sacral-coccygeal fusion (unilateral sacral cornua-coccygeal cornua and unilateral sacrum-transverse progress of coccyx fusion)

and sacral-lumbar fusion was observed (Figs. 1, 2). The skeletal specimen belonged to a cadaver of a 79-year-old Caucasian woman. The straight length of the sacrum in total, from the superior surface of the L5 to the inferior surface of the C1 was 114.42 mm. The maximum width, measured on the level of L5 between the two sacral wings, was 111.32 mm. The maximum diameters of the supernumerary sacral foramina were 11.46 mm for the superior right one, 10.91 mm for the superior left one and 4.37 mm for the inferior right one (Fig. 1). The inferior left sacral foramen was incomplete, but the sharpness of the edge of the coccygeal transverse process, contributes to accept the possibility that the missing osseous part, which hypothetically forms the foramen, would be complete in vivo. Also, the coccyx was slightly laterally deviated to the right. Measurements were made by using a sliding digital calliper.

DISCUSSION

In case of a synostosis between the L5 and sacra, the fusion may include vertebral body, transverse

process and inferior articular process of L5 with the sacrum. These fusions can exist with various combinations, it can be unilateral or bilateral and supernumerary sacral foramina may exist [3]. In case of a synostosis between sacrum and coccyx, the fusion may include the sacral and coccygeal cornua or the coccygeal transverse processes and the sacrum, and it can be unilateral or bilateral in both cases [2]. Coccygeal sacralisation is defined as unilateral or bilateral fusion of the transverse processes of the first coccygeal segment to the inferolateral angle of the sacrum, forming 6 sacral segments [4]. Tague has noted the existence of dual sacral-coccygeal fusion and sacral-lumbar fusion in 0.5% of males [9]. Lee et al. [2] observed that unilateral sacral cornua-coccygeal cornua and unilateral, or even more bilateral, sacrum-transverse process of coccyx fusions are less common variations of the sacrococcygeal region. These findings, under the suspicion of bilateral transverse process fusions and the existence of female gender, make our case unique and noteworthy.

Lumbosacral transitional anomalies, sacralisation, structural anomalies at the lumbosacral facet joints are some of the referred mechanics-based aetiologies that may cause low back pain, while a rigid coccyx with a predominant tip, coccygeal hypermobility and morphological abnormalities around the neural course are some of the mechanical causes of coccygodynia [2, 3, 10]. Several studies have recently examined the sacrococcygeal morphology and its linkage with coccygodynia [2, 4, 9–12]. Based on this data, we could make the hypothesis that the fusions of our case and the possible narrowing of the supernumerary sacral foramina could lead to neural compression mechanisms and the corresponding symptoms.

Accurate knowledge of the anatomy of the sacral region may be crucial in some cases for the accuracy of the diagnosis or an operation in the area. Radiologists should be aware of this case while patients with pain in lumbosacral area are often referred by the doctors for magnetic resonance imaging in order to establish an accurate diagnosis [6]. Surgeons of this region must also be knowledgeable, as the variation of the anatomy of the area can make an iliosacral screw fixation a less safe procedure [7].

REFERENCES

1. Esses SI, Botsford DJ, Huler RJ, et al. Surgical anatomy of the sacrum. A guide for rational screw fixation. *Spine (Phila Pa 1976)*. 1991; 16(6 Suppl): S283–S288, indexed in Pubmed: 1862426.
2. Lee JY, Gil YC, Shin KJ, et al. An Anatomical and Morphometric Study of the Coccyx Using Three-Dimensional Reconstruction. *Anat Rec (Hoboken)*. 2016; 299(3): 307–312, doi: 10.1002/ar.23300, indexed in Pubmed: 26643406.
3. Mahato NK. Pedicular anatomy of the first sacral segment in transitional variations of the lumbo-sacral junction. *Spine (Phila Pa 1976)*. 2011; 36(18): E1187–E1192, doi: 10.1097/BRS.0b013e318206bdf7, indexed in Pubmed: 21343846.
4. Marwan YA, Al-Saeed OM, Esmaeel AA, et al. Computed tomography-based morphologic and morphometric features of the coccyx among Arab adults. *Spine (Phila Pa 1976)*. 2014; 39(20): E1210–E1219, doi: 10.1097/BRS.0000000000000515, indexed in Pubmed: 25208043.
5. Matveeva N, Papazova M, Zhivadinovik J, et al. Morphologic characteristics of sacra associated with assimilation of the last lumbar vertebra. *Folia Morphol*. 2016; 75(2): 196–203, doi: 10.5603/FM.a2015.0081, indexed in Pubmed: 26383506.
6. Milicić G, Krolo I, Vrdoljak J, et al. Using magnetic resonance imaging to identify the lumbosacral segment in children. *Coll Antropol*. 2006; 30(1): 55–58, indexed in Pubmed: 16617576.
7. Miller A, Routt M. Variations in Sacral Morphology and Implications for Iliosacral Screw Fixation. *Am Acad Orthop Surg*. 2012; 20(1): 8–16, doi: 10.5435/00124635-201201000-00002.
8. Postacchini R, Trasimeni G, Ripani F, et al. Morphometric anatomical and CT study of the human adult sacroiliac region. *Surg Radiol Anat*. 2017; 39(1): 85–94, doi: 10.1007/s00276-016-1703-0, indexed in Pubmed: 27324173.
9. Tague RG. Fusion of coccyx to sacrum in humans: prevalence, correlates, and effect on pelvic size, with obstetrical and evolutionary implications. *Am J Phys Anthropol*. 2011; 145(3): 426–437, doi: 10.1002/ajpa.21518, indexed in Pubmed: 21541925.
10. Woon JTK, Maigne JY, Perumal V, et al. Magnetic resonance imaging morphology and morphometry of the coccyx in coccydynia. *Spine (Phila Pa 1976)*. 2013; 38(23): E1437–E1445, doi: 10.1097/BRS.0b013e3182a45e07, indexed in Pubmed: 23917643.
11. Woon JTK, Perumal V, Maigne JY, et al. CT morphology and morphometry of the normal adult coccyx. *Eur Spine J*. 2013; 22(4): 863–870, doi: 10.1007/s00586-012-2595-2, indexed in Pubmed: 23192732.
12. Yoon MG, Moon MS, Park BK, et al. Analysis of sacrococcygeal morphology in Koreans using computed tomography. *Clin Orthop Surg*. 2016; 8(4): 412–419, doi: 10.4055/cios.2016.8.4.412, indexed in Pubmed: 27904724.