

An arthroscopic evaluation of the anatomical “critical zone”

N. Naidoo¹, L. Lazarus², S.A. Osman³, K.S. Satyapal²

¹College of Medicine, Mohammed Bin Rashid University of Medicine and Health Sciences, Dubai Healthcare City, Dubai, United Arab Emirates

²Department of Clinical Anatomy, School of Laboratory Medicine and Medical Sciences, College of Health Sciences, University of KwaZulu-Natal, Westville Campus, Durban, South Africa

³Orthopaedic Surgeon, Suite 11 Medical Centre East, Entabeni Hospital, Durban, South Africa

[Received: 31 March 2016; Accepted: 24 May 2016]

Background: The “critical zone”, a region of speculated vascularity, is situated approximately 10 mm proximal to the insertion of the supraspinatus tendon. Despite its obvious role as an anatomical landmark demarcator, its patho-anatomic nature has been identified as the source of rotator cuff pathology. Although many studies have attempted to evaluate the vascularity of this region, the architecture regarding the exact length, width and shape of the critical zone, remains unreported. This study aimed to determine the shape and morphometry of the “critical zone” arthroscopically.

Materials and methods: The sample series, which was comprised of 38 cases ($n = 38$) specific to pathological types, employed an anatomical investigation of the critical zone during routine real-time arthroscopy. Demographic representation: i) sex: 19 males, 19 females; ii) age range: 18–76 years; iii) race: white ($n = 29$), Indian ($n = 7$) and coloured ($n = 2$).

Results: The incidence of shape and the mean lengths and widths of the critical zone were determined in accordance with the relevant demographic factors and patient history. Although the cresenteric shape was predominant, hemispheric and sail-shaped critical zones were also identified. The lengths and widths of the critical zone appeared markedly increased in male individuals. While the increase in age may account for the increased incidence of rotator cuff degeneration due to poor end-vascular supply, the additional factors of height and weight presented as major determinants of the increase in size of the critical zone.

Conclusions: In addition, the comparisons of length and width with each other and shape yielded levels of significant difference, therefore indicating a directly proportional relationship between the length and width of the critical zone. This detailed understanding of the critical zone may prove beneficial for the success of post-operative rotator cuff healing. (Folia Morphol 2017; 76, 2: 277–283)

Key words: critical zone, shape, length, width

INTRODUCTION

The recognition of shoulder pathogenesis as the third most common cause of musculoskeletal diseases in society, has led to the focus of intrinsic patho-anatomic entities which are considered to result in rotator cuff degeneration [13, 24]. These intrinsic patho-anatomic entities are reported to include age, morphology, morphometry, sex and patient history [24].

The rotator cuff, which functions as a composite anatomical musculo-tendinous hood, stabilizes the humeral head in the normal articulated position at the glenoid fossa during abduction and flexion [15, 19, 21–23]. It is classically comprised of four muscles and the underlying fibrous capsule of the glenohumeral joint [21–23]. These four muscles are the supraspinatus, infraspinatus, teres minor and subscapularis, the former three of which are situated posteriorly, with the latter located anteriorly [17, 21, 22, 23].

Subsequently, the “critical zone”, a region of speculated vascularity within the rotator cuff complex, has become a growing area of interest due to its predisposition to tears and lesions [4, 21, 24]. Codman and Akerson [5] identified this region within the surface of the central aspect of the supraspinatus tendon, approximately 10 mm from the insertion of the supraspinatus tendon at the antero-medial aspect of the superior facet of the greater humeral tuberosity [9]. Since it is speculated to be an area of diminished vascularity, it is often referred to as the “watershed” region [1–3, 5–8, 10–12, 16, 20, 21, 24].

The critical zone has also been considered to depict an important anatomical landmark as it not only demarcates the osseous arcuate branch of the anterior circumflex humeral artery from the muscular subscapular and suprascapular arteries, but also the anterior from the posterior vessels [3, 11, 16, 20, 23]. Although Ling et al. [11] found that older patients presented with greater lengths and widths of the critical zone, there appears to be no apparent blueprint with regard to the shape and size of the critical zone.

Furthermore, Rathburn and Macnab [20] stated that the nature of the critical zone is associated with the advancement into the golden years, rather than indicating a pathological state of itself. While age-related changes regarding the shape and dimensions of the critical zone are not completely described in the literature, Ling et al. [11] attributed an increase in morphometry to poor end-arterial supply and atherosclerosis.

Thus, the aim of this study was to determine the shape and morphometry of the “critical zone” at arthroscopy.

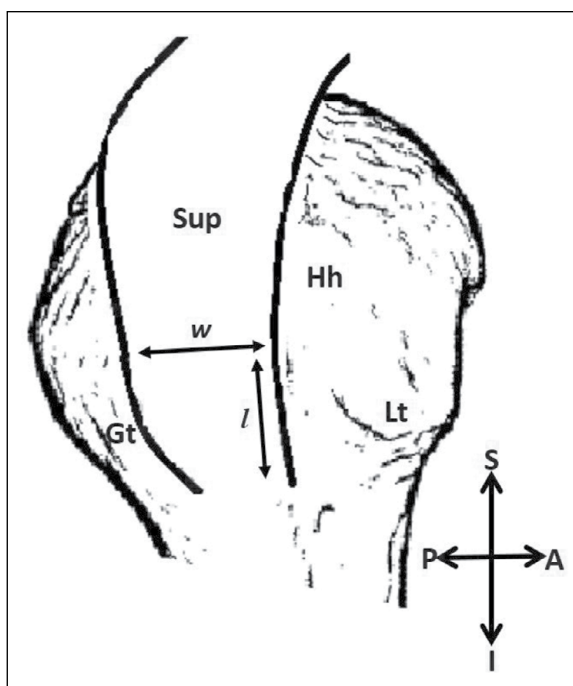


Figure 1. Supero-lateral view of length and width measurements of the critical zone; A — anterior; Gt — greater humeral tubercle; Hh — humeral head; I — inferior; l — length; Lt — lesser humeral tubercle; P — posterior; S — superior; Sup — supraspinatus muscle-tendon complex; w — width.

MATERIALS AND METHODS

During routine arthroscopy, the length, width and shape of the critical zone were investigated and recorded (Fig. 1). This study was conducted through the assistance and expertise of an orthopaedic surgeon based at Life Entabeni Hospital in KwaZulu-Natal, South Africa. It complied with the standards of good practice as per the institutional ethical authority (Ethical Clearance Approval Number: BE280/13) and was in accordance with the protocol of the hospital management.

The sample series was comprised of 38 cases ($n = 38$) (sex: 19 males, 19 females) with an age range of 18–76 years, belonging to the white ($n = 29$), Indian ($n = 7$) and coloured ($n = 2$) ethnic groups.

As it was hypothesized that body height and body weight influence the morphology and dimensions of the critical zone, both these parameters were noted.

Patient history was specific to nine groups of pathological types, viz. acromioclavicular joint (ACJ) dislocation; calcific tendinitis; calcification; frozen shoulder; impingement; instability; labral tear; rotator cuff tear; and subscapularis tear. These pathological types were included as they are known to arise from extrinsic and/or intrinsic factors that may affect the shape and

Table 1. Incidence of shape and mean length and width of the critical zone within the demographic distribution

Parametr		Sex		Race			Height	Weight	Age [years]	Length (mm)	Width (mm)
		Male	Female	White	Indian	Coloured					
Shape (%)	Crescent	44.7	44.7	71.1	15.8	2.6	1.7 ± 0.2	78.7 ± 19.4	50.3 ± 13.4	2.4 ± 0.2	1.5 ± 0.2
	Hemispheric	2.6	0	2.6	0	0	1.9 ± 0.0	95.0 ± 0.0	75.0 ± 0.0	2.8 ± 0.0	1.8 ± 0.0
	Sail-shaped	2.6	5.3	2.6	2.6	2.6	1.6 ± 0.1	73.0 ± 19.1	44.3 ± 12.5	2.1 ± 0.3	1.1 ± 0.3
P		0.51		0.18			0.37	0.62	0.15	0.01*	0.01*
Length (mm)		2.5 ± 1.0	2.2 ± 0.2	2.4 ± 0.2	2.3 ± 0.2	2.4 ± 0.1	–	–	–	–	–
P		0.00*		0.863			0.00*	0.01*	0.05*	–	–
Width (mm)		1.5 ± 0.2	1.3 ± 0.2	1.4 ± 0.2	1.5 ± 0.1	1.4 ± 0.2	–	–	–	–	–
P		0.01*		0.776			0.00*	0.04*	0.49	–	–

*Significant p value

Table 2. Incidence of shape and mean length and width of the critical zone for specific pathological types of patient history

Patient history	Shape (%)			P	Length (mm)	P	Width (mm)	P
	Crescentic	Hemispheric	Sail-shaped					
Acromioclavicular joint dislocation	2.6	0	0		2.4 ± 0.0		1.4 ± 0.0	
Calcific tendinitis	5.3	0	0		2.4 ± 0.1		1.4 ± 0.2	
Calcification	5.3	0	2.6		2.2 ± 0.2		1.5 ± 0.1	
Frozen shoulder	15.8	0	0		2.3 ± 0.2		1.3 ± 0.2	
Impingement	31.6	2.6	2.6	0.98	2.4 ± 0.3	0.93	1.48 ± 0.3	0.85
Instability	10.5	0	0		2.3 ± 0.1		1.5 ± 0.3	
Labral tear	2.6	0	0		2.5 ± 0.0		1.5 ± 0.0	
Rotator cuff tear	13.6	0	2.6		2.4 ± 0.3		1.4 ± 0.1	
Subscapularis tear	2.6	0	0		2.4 ± 0.0		1.5 ± 0.0	

surface area of the critical zone. Furthermore, some of these pathological types may present as the premature stages of the ensuing condition of other types, i.e. instability arising from a traumatic injury may cause impingement due to the misalignment and narrowing of the subacromial space, to eventually lead to rotator cuff tear.

The statistical analysis, which accounted for the demographic distribution and the relevant parameters, was performed using SPSS version 22.0 (SPSS Inc., Chicago, Illinois, USA). A p value of < 0.05 was considered to be statistically significant.

RESULTS

The shape, length and width of the critical zone according to demographic distribution and patient history are displayed in Tables 1 and 2, respectively.

Shape of the critical zone

Three distinctive shapes of the critical zone were identified, viz. crescentic; hemispheric and sail-shaped (Fig. 2A–C).

All three shapes of the critical zone were observed in male individuals (crescentic 44.7%; hemispheric 2.6%; sail-shaped 2.6%); however, the morphology of female individuals yielded crescent (44.7%) and sail-shaped (5.3%) only (Fig. 2A–C, Table 1).

Crescentic and sail-shaped critical zones were observed among all three ethnic groups (white: crescentic 71.1%; sail-shaped 2.6%; Indian: crescent 15.8%; sail-shaped 2.6%; coloured: crescentic 2.6%; sail-shaped 2.6%) (Fig. 2A–C; Table 1). In addition, hemispheric (2.6%) critical zones were identified within the white race group (Fig. 2A–C, Table 1).

The mean heights, relevant to the specific shape of the critical zone were recorded: crescentic (1.7 ± 0.2 m);

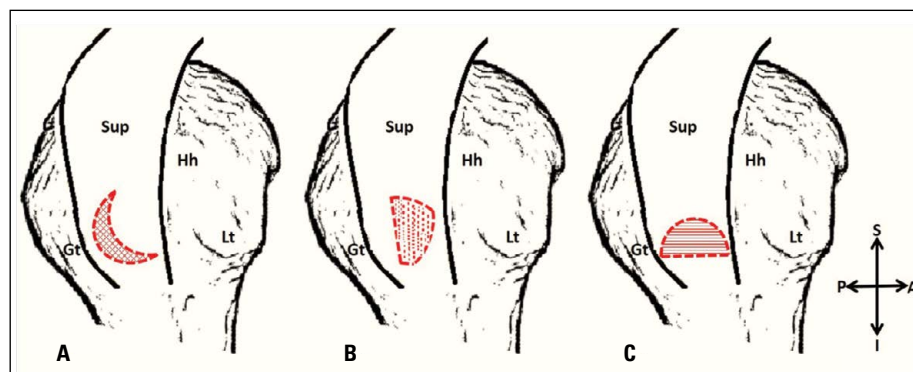


Figure 2. Supero-lateral view of the shapes of the critical zone: **A.** Crescentic; **B.** Sail-shaped; **C.** Hemispheric; A — anterior; Gt — greater humeral tubercle; Hh — humeral head; I — inferior; Lt — lesser humeral tubercle; P — posterior; S — superior; Sup — supraspinatus muscle-tendon complex.

hemispheric (1.9 ± 0.0 m); sail-shaped (1.6 ± 0.1 m) (Fig. 2A–C, Table 1).

The mean weights for the crescentic, hemispheric and sail-shaped critical zones were 78.7 ± 19.4 kg, 95.0 ± 0.0 kg and 73.0 ± 19.1 kg, respectively (Fig. 2A–C, Table 1).

In accordance with the relevant shapes of the critical zone, the mean ages of the individuals were estimated to be 50.3 ± 13.4 years (crescentic); 75.0 ± 0.0 years (hemispheric) and 44.3 ± 12.5 year (sail-shaped) (Fig. 2A–C, Table 1).

The mean lengths of the crescentic, hemispheric and sail-shaped critical zones were 2.4 ± 0.2 mm, 2.8 ± 0.0 mm and 2.1 ± 0.3 mm, respectively (Table 1). The comparison of length with shape yielded a statistically significant p value of 0.01 (Table 1).

The mean widths specific to the shapes of the critical zone were 1.5 ± 0.2 mm (crescentic), 1.8 ± 0.0 mm (hemispheric) and 1.1 ± 0.3 mm (sail-shaped) (Table 1). A statistically significant p value (0.01) was recorded for the comparison of width with shape (Table 1).

Although all pathological types displayed crescentic critical zones (ACJ dislocation [2.6%]; calcific tendinitis [5.3%]; calcification [5.3%]; frozen shoulder [15.8%]; impingement [31.6%]; instability [10.5%]; labral tear [2.6%]; rotator cuff tear [13.6%]; subscapularis tear [2.6%]), hemispheric and sail-shaped critical zones were seen in one (impingement [2.6%]) and three (calcification [2.6%]; impingement [2.3%]; rotator cuff tear [2.6%]) pathological types, respectively (Table 2).

Length of the critical zone

The mean length of the critical zone was recorded to be 2.5 ± 1.0 mm and 2.2 ± 0.2 mm in males and females, respectively (Table 1). The comparison of length with sex yielded a statistically significant p value of 0.00 (Table 1).

The ethnic distribution of the mean length was 2.4 ± 0.2 mm (white); 2.3 ± 0.2 mm (Indian) and 2.4 ± 0.1 mm (coloured) (Table 1).

The correlation of length with height (0.00), weight (0.01), age (0.05) and width (0.00) yielded statistically significant p values (Table 1).

The mean length according to each pathological type was documented, viz. ACJ dislocation (2.4 ± 0.0 mm); calcific tendinitis (2.4 ± 0.1 mm); calcification (2.2 ± 0.2 mm); frozen shoulder (2.3 ± 0.2 mm); impingement (2.4 ± 0.3 mm); instability (2.3 ± 0.1 mm); labral tear (2.50 ± 0.00 mm); rotator cuff tear (2.4 ± 0.3 mm); subscapularis tear (2.4 ± 0.0 mm) (Table 2).

Width of the critical zone

Male and female individuals presented with mean widths of 1.5 ± 0.2 mm and 1.3 ± 0.2 mm, respectively (Fig. 3, Table 1). A statistically significant p value of 0.01 was recorded for the comparison of width with sex (Table 1).

The mean widths for white, Indian and coloured individuals were recorded to be 1.4 ± 0.2 mm; 1.5 ± 0.1 mm and 1.4 ± 0.2 mm, respectively (Fig. 3, Table 1).

The comparison of width with height and weight yielded statistically significant p values of 0.00 and 0.04, respectively (Table 1).

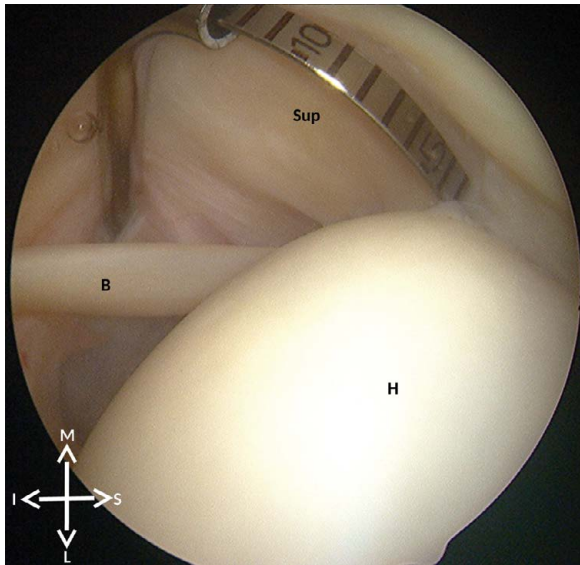


Figure 3. Superior view of left critical zone width measurement; B — tendon of long head of biceps brachii; H — humeral head; L — lateral; M — medial; I — inferior; S — superior; Sup — supraspinatus muscle-tendon complex.

The mean width specific to each pathological type was recorded, viz. ACJ dislocation (1.40 ± 0.00 mm); calcific tendinitis (1.35 ± 0.21 mm); calcification (1.47 ± 0.06 mm); frozen shoulder (1.30 ± 0.15 mm); impingement (1.48 ± 0.26 mm); instability (1.53 ± 0.32 mm); labral tear (1.50 ± 0.00 mm); rotator cuff tear (1.43 ± 0.12 mm); subscapularis tear (1.50 ± 0.00 mm) (Fig. 3, Table 2).

DISCUSSION

Although this study focused on a generally unfrequented region in terms of anatomical study, it is an area bearing much clinical relevance. In addition, no other known study has collectively documented the shape, length and width of the critical zone with consideration of demographic factors, body height, body weight and specific pathological types.

Crescentic critical zones appeared to be equally prevalent in both male and female individuals; however, hemispheric and sail-shaped critical zones were predominantly found in males and females, respectively (Table 1). Hemispheric and crescentic critical zones were most common in white individuals, while sail-shaped critical zones were equally prevalent among all three ethnic groups (Table 1). Hemispheric critical zones presented with the highest mean body height of 1.9 ± 0.0 m (Table 1).

Similarly, the mean body weight was greatest in individuals presenting with hemispheric critical zones (Table 1).

Individuals with hemispheric critical zones had the highest mean age of 75.0 ± 0.0 years (Table 1). Hemispheric critical zones displayed the largest mean length of 2.8 ± 0.0 mm (Table 1). It may be postulated from the statistically significant p value recorded for comparison of length with shape, that a greater length is typical for the hemispheric critical zone (Table 1). Consequently, the mean width was greatest for the hemispheric critical zones (Table 1). The statistically significant p value of 0.01 may indicate that hemispheric critical zones generally present with markedly increased widths (Table 1).

Despite the presence of crescentic critical zones among all pathological types, crescentic and hemispheric critical zones were predominantly observed within the impingement group, with the former presenting with a distinctively high incidence (Table 2). Sail-shaped critical zones were equally prevalent in the calcification, impingement and rotator cuff groups (Table 2). As a result, the impingement group appeared to be the common pathological type to all three shapes of the critical zone. Although the development of rotator cuff tears may arise independently or from the combined interaction of the calcification and impingement types, both rotator cuff tears and calcification arise from intrinsic and extrinsic factors [19]. On the contrary, impingement has an extrinsic basis arising from structural narrowing or acute changes in movement and posture [19]. It may thus be postulated that variation in the shapes of the critical zone are related to extrinsic factors rather than intrinsic ones.

The mean length of the critical zone, which was higher in male individuals, yielded a statistically significant p value for the comparison of length with sex, thus suggesting that an increased length is a common finding in male individuals (Table 1). Coloured individuals presented with an increased mean length of 2.4 ± 0.1 mm (Table 1).

Although Ling et al. [11] stated that the increased morphometric aspects of the critical zone, which result from increasing age, may account for the incidence in rupture, tendinitis and calcification of the rotator cuff complex in individuals older than 50 years of age, the present study revealed statistically significant differences for the correlation of length with body height, body weight, age and width

(Table 1). While the increase in age may be linked to poor end-arterial supply and atherosclerosis, it may be postulated that the additional factors of height, weight and width of the current study are major determinants of an increase in the size of the critical zone (Table 1) [11].

Since the glenoid labrum presents as a fibro-cartilaginous tissue around the glenoid rim, it acts as a static stabilizer of the glenohumeral joint [14]. In the present study, the pathological type of labral tear yielded the highest mean length of 2.5 ± 0.0 mm (Table 2). Despite serving as an attachment site for the glenohumeral capsule, the glenoid labrum provides no attachment to the supraspinatus muscle-tendon complex, hence the supraspinatus tendon is unaffected by labral tears [14]. This may explain the increased mean length observed in the labral tear group. However, given the fact that labral tears are extrinsic in nature arising from traumatic injury and/or repetitive "over-head" throwing activities, it has been found that the same mechanisms causing rotator cuff injury may also result in tearing of the glenoid labrum [14].

Male individuals presented with larger mean widths of 1.5 ± 0.2 mm (Table 1). The gender differences in bone geometry, which result in males having larger, heavier bones and thus larger surface areas at the proximal end of the humerus, may account for the statistically significant difference recorded for the comparison of width with sex (Table 1) [18]. Therefore, it may be suggested that larger widths of the critical zone are generally seen in male individuals (Table 1).

A distinctly increased mean width of the critical zone was identified in individuals of Indian ethnicity (Table 1).

The comparison of width with body height and body weight yielded statistically significant differences, thus indicating that the increased width of the critical zone is determined by the latter two factors (Table 1).

The highest mean width of 1.5 ± 0.3 mm was observed within the instability group (Table 2). As instability arises primarily from the extrinsic factor of traumatic injury, it may be verified that a decrease in morphometry of the critical zone is due to intrinsic factors such as degeneration.

CONCLUSIONS

Crescentic critical zones appeared to be the predominant shape, with the hemispheric shape being rarely present. Male individuals generally present with larger lengths and widths of the critical zone. The increase in morphometry of the critical

zone, specifically length and width, was seen to be greatly influenced by body height, body weight and age. Furthermore, the comparisons of length and width with each other and shape revealed levels of significant difference, thus suggesting a directly proportional relationship between the length and width of the critical zone. In addition, the provision of a concise patient history may be informative of the anatomical nature of the critical zone, from which a specific pathological type may be deduced. As a result, the anatomical status of the critical zone may prove beneficial in operative preparation and postoperative prognosis.

REFERENCES

1. Adler RS, Fealy S, Rudzki JR, et al. Rotator cuff in asymptomatic volunteers: contrast-enhanced US depiction of intratendinous and peritendinous vascularity. *Radiology*. 2008; 248(3): 954–961, doi: [10.1148/radiol.2483071400](https://doi.org/10.1148/radiol.2483071400), indexed in Pubmed: [18647848](https://pubmed.ncbi.nlm.nih.gov/18647848/).
2. Brooks CH, Revell WJ, Heatley FW. A quantitative histological study of the vascularity of the rotator cuff tendon. *J Bone Joint Surg Br*. 1992; 74(1): 151–153, indexed in Pubmed: [1732247](https://pubmed.ncbi.nlm.nih.gov/1732247/).
3. Chansky HA, Iannotti JP. The vascularity of the rotator cuff. *Clin Sports Med*. 1991; 10(4): 807–822, indexed in Pubmed: [1934098](https://pubmed.ncbi.nlm.nih.gov/1934098/).
4. Chung CB, Steinbach LS. *MRI of the Upper Extremity: Shoulder, Elbow, Wrist and Hand*. Philadelphia, Lippincott Williams & Wilkins 2010.
5. Codman EA, Akerson IB. The pathology associated with rupture of the supraspinatus tendon. *Ann Surg*. 1931; 93(1): 348–359, indexed in Pubmed: [17866481](https://pubmed.ncbi.nlm.nih.gov/17866481/).
6. Determe D, Rongières M, Kany J, et al. Anatomic study of the tendinous rotator cuff of the shoulder. *Surg Radiol Anat*. 1996; 18(3): 195–200, indexed in Pubmed: [8873333](https://pubmed.ncbi.nlm.nih.gov/8873333/).
7. Herberts P, Kadefors R, Andersson G, et al. Shoulder pain in industry: an epidemiological study on welders. *Acta Orthop Scand*. 1981; 52(3): 299–306, indexed in Pubmed: [7282323](https://pubmed.ncbi.nlm.nih.gov/7282323/).
8. Kane SM, Dave A, Haque A, et al. The incidence of rotator cuff disease in smoking and non-smoking patients: a cadaveric study. *Orthopedics*. 2006; 29(4): 363–366, indexed in Pubmed: [16628997](https://pubmed.ncbi.nlm.nih.gov/16628997/).
9. Kovacevic D, Rodeo SA. Biological augmentation of rotator cuff tendon repair. *Clin Orthop Relat Res*. 2008; 466(3): 622–633, doi: [10.1007/s11999-007-0112-4](https://doi.org/10.1007/s11999-007-0112-4), indexed in Pubmed: [18264850](https://pubmed.ncbi.nlm.nih.gov/18264850/).
10. Levy O, Relwani J, Zaman T, et al. Measurement of blood flow in the rotator cuff using laser Doppler flowmetry. *J Bone Joint Surg Br*. 2008; 90(7): 893–898, doi: [10.1302/0301-620X.90B7.19918](https://doi.org/10.1302/0301-620X.90B7.19918), indexed in Pubmed: [18591599](https://pubmed.ncbi.nlm.nih.gov/18591599/).
11. Ling SC, Chen CF, Wan RX. A study on the vascular supply of the supraspinatus tendon. *Surg Radiol Anat*. 1990; 12(3): 161–165, indexed in Pubmed: [1705053](https://pubmed.ncbi.nlm.nih.gov/1705053/).

12. Lohr JF, Uhthoff HK. The microvascular pattern of the supraspinatus tendon. *Clin Orthop Relat Res.* 1990(254): 35–38, indexed in Pubmed: [2323147](#).
13. Matthews TJW, Hand GC, Rees JL, et al. Pathology of the torn rotator cuff tendon. Reduction in potential for repair as tear size increases. *J Bone Joint Surg Br.* 2006; 88(4): 489–495, doi: [10.1302/0301-620X.88B4.16845](#), indexed in Pubmed: [16567784](#).
14. Modarresi S, Motamedi D, Jude CM. Superior labral anteroposterior lesions of the shoulder: part 1, anatomy and anatomic variants. *AJR Am J Roentgenol.* 2011; 197(3): 596–603, doi: [10.2214/AJR.10.7236](#), indexed in Pubmed: [21862801](#).
15. Morag Y, Jacobson J, Miller B, et al. MR imaging of rotator cuff injury: what the clinician needs to know. *RadioGraphics.* 2006; 26(4): 1045–1065, doi:[10.1148/rg.264055087](#).
16. Mosely HF, Goldie I. The arterial pattern of rotator cuff of the shoulder. *J Bone Joint Surg.* 1963; 45B(4): 780–789.
17. Muscolino JE. *The Muscular System Manual: The Skeletal Muscles of the Human Body.* 3rd Ed. Missouri, Mosby Inc 2010: pp134–143.
18. Nieves JW, Formica C, Ruffing J, et al. Males have larger skeletal size and bone mass than females, despite comparable body size. *J Bone Miner Res.* 2005; 20(3): 529–535, doi: [10.1359/JBMR.041005](#), indexed in Pubmed: [15746999](#).
19. Page P. Shoulder muscle imbalance and subacromial impingement syndrome in overhead athletes, *Int J Sports Phys Ther.* 2011; 6(1): 51–58.
20. Rathbun JB, Macnab I. The microvascular pattern of the rotator cuff. *J Bone Joint Surg Br.* 1970; 52(3): 540–553, indexed in Pubmed: [5455089](#).
21. Rockwood CA, Frederick JR, Matsen A, et al. *The Shoulder.* 3rd Ed. USA, Elsevier. 2004: pp. 75–80.
22. Sinnatamby CS. *Last's Anatomy: Regional & Applied.* 11th Ed. New York, Churchill Livingstone. 2006: pp.444-445, 63, 72–76–76.
23. Standing S. *Gray's Anatomy: The Anatomical Basis of Clinical Practice.* 40th Ed. Spain, Elsevier Ltd. 2008: pp. 830–832, 838–840, 841–845.
24. Seitz AL, McClure PW, Finucane S, et al. Mechanisms of rotator cuff tendinopathy: intrinsic, extrinsic, or both? *Clin Biomech (Bristol, Avon).* 2011; 26(1): 1–12, doi: [10.1016/j.clinbiomech.2010.08.001](#), indexed in Pubmed: [20846766](#).