

# Anthropometric measurements of the orbita and gender prediction with three-dimensional computed tomography images

V. Kaplanoglu<sup>1</sup>, H. Kaplanoglu<sup>2</sup>, U. Toprak<sup>1</sup>, İ.S. Parlak<sup>1</sup>, İ.G. Tatar<sup>2</sup>, M. Deveer<sup>3</sup>, B. Hekimoglu<sup>2</sup>

<sup>1</sup>Department of Radiology, Ankara Numune Training and Research Hospital, Ankara, Turkey

<sup>2</sup>Department of Radiology, Diskapi Yildirim Beyazit Training and Research Hospital, Ankara, Turkey

<sup>3</sup>Department of Radiology, Mugla Sitki Kocman University School of Medicine, Mugla, Turkey

[Received 12 September 2013; Accepted 25 October 2013]

**Background:** The aim of the study was to investigate the orbital anthropometric variations in the normal population using three-dimensional computed tomography (3D-CT) images and to define the effects of age and gender on orbital anthropometry.

**Materials and methods:** Three-dimensional orbita CT of 280 patients, obtained for various reasons, were retrospectively evaluated in 772-bed referral and tertiary-care hospital between April 2011 and June 2012. Using 3D images, orbital width, height, biorbital-interorbital diameter and orbital index were measured. Measurements were obtained comparing right and left sides and male to female. The relation of the results with age and gender was analysed.

**Results:** Right orbit was found to be wider than left ( $p < 0.0001$ ). Male patients had wider ( $p < 0.0001$ ) and higher ( $p = 0.0001$ ) orbits. Right orbital index was found to be smaller than the left one ( $p = 0.005$ ). No differences were found between the genders in terms of right and left orbital indexes ( $p > 0.05$ ). Biorbital ( $p < 0.0001$ ) and interorbital ( $p = 0.01$ ) widths were found to be higher in males. There was no relation between the age change and the parameters defined ( $p > 0.05$ ).

**Conclusions:** No relation was found between age and orbital measurements. It was concluded that orbital images obtained with 3D-CT may be used as a method for gender evaluation. (Folia Morphol 2014; 73; 2: 149–152)

**Key words:** orbital anthropology, gender prediction, 3D-CT images

## INTRODUCTION

Orbits have been used in race and gender prediction of individuals for more than a century [10]. Understanding human anatomy, proportions, mechanical functions and racial variations concerning the ocular anatomy are of vital importance when treating or clinically evaluating patients [2]. Anthropometry helps to understand anatomic structures and forms

the technique of expressing quantitatively the form of the human body and skeleton. Anthropometric studies are an integral part of craniofacial surgery and 'syndromology' [9].

Differences amongst species provide an important point of view to the forensic anthropometry in the process of individualisation. Human skull and cranium are anthropometric tools of utmost

importance in forensic researches and in analysing ethnic and racial relations. In 1875, Paul Broca found the orbital index by measuring orbital height and width in order to evaluate the orbital size and shape as a quantity [9]. According to this index, Piquet categorised shape of the orbita as high, medium, low or "hypsiconch, mesoconch, and chamaeconch" consequently [8]. These categories are related to racial features. The orbital shape and size show differences in different races, ethnic groups and genders.

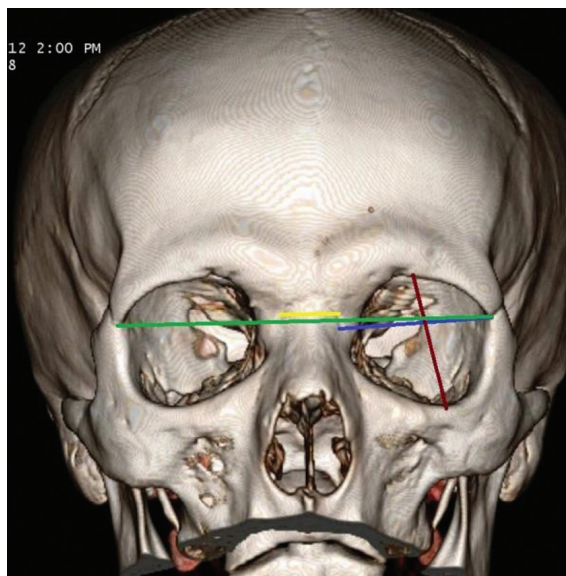
Patnaik et al. [7] calculated the orbital index and showed the relation between width and height of the orbit and defined 3 orbital categories: **megaseme (large)** — the orbital index is 89 or over; this type is seen in the yellow race except the Eskimos [9]; **mesoseme (medium)** — the orbital index ranges between 89 and 83; this type is found in the Caucasian race [9]; **microseme (small)** — the orbital index is 83 or less; this type is found in the black race [9].

Studies of this field are generally conducted on cadavers. In addition, in orbital cavity studies, anterior and lateral skull radiographs are often used [1, 2]. Furthermore, in the last years, development of 3D-CT has been used in the measurement of the orbita [3, 4]. Weiss et al. [11] stated that computed tomography (CT) is the best way to evaluate the orbital cavity because of the complex anatomy of the ocular and ethmoidal region. Three-dimensional (3D)-CT is a perfect method to obtain an objective result. This technique provides a sophisticated examination possibility of the orbital cavity.

The aim of this anthropometric study was to research the anthropometric variations of the orbita in the normal population using 3D-CT images, measure the orbital height, width and index using the method designed by Broca and also measure bi-interorbital dimensions.

## MATERIALS AND METHODS

Our research was accepted by our hospitals' local ethical committee (ethical committee no: 2012/03/25). 3D-CT's of 280 patients, obtained for various reasons, were retrospectively evaluated in 772-bed referral and tertiary-care hospital between April 2011 and June 2012. Patients with previous facial surgeries or severe trauma, and those younger than 20 years of age were excluded from the study. CT machine with 4 detectors (Philips Marconi MX8000) (tube voltage, 120 kVp; 150 mAs; FOV, 180 mm; 0875 pitch) was used. Section width was



**Figure 1.** Three-dimensional reformatted computed tomography image of orbits; blue line — orbital width; dark red line — orbital height; green line — biorbital width; yellow line — interorbital width.

2 mm, section interval 1 mm, coronal reformatted images with 0.625 sectional width were obtained. 3D images were reconstructed from coronal images and the measurements were evaluated on a digital monitor. All images included in the study were evaluated and interpreted by the same radiologist. Measurements were performed manually on a digital monitor. Standard anatomical points were determined and used for the measurement of the orbital width, height, biorbital-interorbital diameter and the orbital index.

**Orbital width** — laterally curved distance between the dacryon (the point where frontal, lacrimal and maxillary bones intersect and the medial margin of the orbit is formed) and ectoconchion (the point of intersection of the anterior surface of the lateral limit of orbita; the line divides the orbit along its axis into 2 parts) (Fig. 1) [5]; **orbital height** — distance between the superior and inferior orbital margins; it is perpendicular to its width and similarly divides the orbita into 2 parts (Fig. 1) [5]; **orbital index** — orbital height/orbital width  $\times$  100 [9]; **biorbital width** — distance between left and right ectoconchion (Fig. 1) [5]; **interorbital width** — distance between right and left dacryon (Fig. 1) [5]. Measurements were performed on coronal plane using 3D images reconstructed from orbital images. The relation of age and gender with the results was analysed.

**Table 1.** Dispersion of orbital width and height according to left/right sides and genders

Gender	Right width	Right height	Left width	Left height
Female	44.6 ± 2.1	37.7 ± 2.3	44.2 ± 2.2	37.7 ± 2.3
Male	46.1 ± 2.2	38.8 ± 2.9	45.8 ± 2.3	38.8 ± 3.0
Total	45.3 ± 2.3	38.2 ± 2.7	45 ± 2.4	38.2 ± 2.7

**Table 2.** Distribution of orbital indexes according to left/right sides and genders

Gender	Right orbital index	Left orbital index	Total orbital index
Female	84.7 ± 5.9	85.3 ± 6.2	85 ± 6.05
Male	84.2 ± 6.5	85.0 ± 7.3	84.6 ± 6.9
Total	84.5 ± 6.2	85.2 ± 6.7	84.8 ± 6.4

### Statistical analysis

All statistical analyses were performed using the SPSS 17.0 version software for Windows (Statistical package for Social Sciences Inc, Chicago, IL, USA). When evaluating the study data, beside descriptive study methods (average, standard deviation, median frequency) to detect the group causing the difference and in comparison with 2 groups, paired t-test was used; to evaluate the differences between genders, independent t-test was used; in the evaluation of the relations between parameters, Pearson's correlation analysis was performed; to evaluate the age differences between the groups, Mann-Whitney U-test was used. Results are in 95% confidence range.  $P < 0.05$  was considered significant.

## RESULTS

CT images of 280 patients were analysed. Of the patients, 145 (51.8%) were female, 135 (48.2%) were male. Mean age was  $42 \pm 13.3$  and median age was 41.5 (20–84). The mean age of female patients was  $42 \pm 13.4$  and the median age was 42 (20–84). In male patients, mean age was  $43 \pm 13.2$  and median age was 41 (20–75). The widths and heights of the orbits were as follows: mean right orbital width  $45.3 \pm 2.3$  mm and mean height  $38.2 \pm 2.7$  mm; mean left orbital width  $45 \pm 2.4$  mm and mean height  $38.2 \pm 2.7$  mm. When left and right orbital widths and heights were statistically analysed, it was found that right orbital width was statistically higher and significant than the left orbit ( $p < 0.0001$ ). There was no statistically significant difference between right and left orbital heights ( $p > 0.05$ ).

**Table 3.** Distribution of biorbital-interorbital widths according to genders

Gender	Biorbital width	Interorbital width
Male	96.2 ± 3.9	12.4 ± 2.05
Female	99.6 ± 4.2	13.0 ± 2.1
Total	97.8 ± 4.4	12.7 ± 2.1

When left and right orbital heights and widths were comparatively evaluated between gender groups, left and right orbital widths were higher in male patients and the difference was statistically significant ( $p < 0.0001$ ). Also, it was found that left and right orbital heights were higher and statistically significant in males than in females ( $p = 0.001$ ) (Table 1). The orbital index (orbital height/orbital width  $\times 100$ ) on the right side is  $84.5 \pm 6.2$  and on the left side  $85.2 \pm 6.7$ . When right and left orbital indexes were compared, right orbital index was found to be statistically lower and significant than the left side ( $p = 0.005$ ). When right and left orbital indexes were comparatively evaluated between gender groups, no statistically significant difference was found ( $p > 0.05$ ) (Table 2).

The average biorbital width was  $97.8 \pm 4.4$  mm, and the interorbital width was  $12.7 \pm 2.1$  mm. When biorbital/interorbital widths were evaluated comparatively between gender groups, biorbital width ( $p < 0.0001$ ) and interorbital width ( $p = 0.01$ ) in males were found to be statistically higher and significant than in females (Table 3). When we have evaluated the relation of age with right and left orbital width,

length, orbital index and bi/interorbital width, we have found no statistically significant relation ( $p > 0.05$ ). Furthermore, no age differences were found between the male and female patient groups ( $p > 0.05$ ).

## DISCUSSION

Current study results have revealed that anthropometric differences of the orbita derive from gender, but age has no influence. Ethnic differences were not considered in our study. According to a different study, opposite to our findings was that the orbit widens by age, but similar to our study was that when orbital width and height are normalised, main measurement differences derive from gender [9]. In the present study we have found that the orbital height, width, orbital index, biorbital-interorbital widths were higher in males than in females. According to the study of Weaver et al. [10], similarly to our study, the orbital width and height in males were found to be higher than in females. Furthermore, Husmann et al. [2] in their study found that the orbital index is higher in females. We presume that this differences derive more from ethnic diversities other than gender.

The average orbital index in females was 85, in males 84.6, in total 84.8, and belonging to mesoseme category. In a study conducted on Nigerians it was found that Nigerian males are in megaseme category [12]. Additionally, in a study conducted on Malawians, the orbital index in males was 94.35, in females 96.03, both categorised as megaseme [11]. In an old study conducted by Casidy, the black race was grouped in microseme category [6]. These findings show us, that ethnicity is being influential in orbital measurements.

When both orbits are compared, the right orbit is wider than the left orbit, no difference has been detected in the heights. Thus, the right side orbital index was found to be smaller than the left side. No significant differences between left and right orbital index measurements have been detected in the gender groups. The difference between left and right sides was considered to be due to the different growth of the both sides of the brain, and the left side seems to be more dominant [9].

## CONCLUSIONS

As a result, measurements of the orbita contain valuable practical knowledge about genders. No relation was detected between age and orbital measurements. With this method, in the future, in larger study groups, it would be possible to classify individuals to ethnic and gender groups. We conclude, that orbital images obtained with 3D-CT can be used as a method for gender evaluation.

## REFERENCES

1. Fawehinmi HB, Ligha AE, Chikwu P (2008) Orbital dimensions of Nigerian adults. *Jobiomed Afr*, 6: 1–2.
2. Husmann PR, Samson DR (2011) In the eye of the beholder: sex and race estimation using the human orbital aperture. *J Forensic Sci*, 56: 1424–1429.
3. Igbigbi PS, Ebite LE (2010) Orbital index of adult malawians. *Anil Aggrawal's Internet J Forensic Med Toxicol*, 11: 1.
4. Lo LJ, Marsh JL, Kane AA, Vannier MW (1996) Orbital dysmorphism in unilateral coronal synostosis. *Cleft Palate-Craniofacial J*, 33: 3.
5. Moore-Jansen PM, Ousley SD, Jantz RL (1997) Data collection procedures for forensic skeletal material. Report of investigations. University of Tennessee, Knoxville, TN.
6. Novit M (2006) Facial, upper facial, and orbital index in Batak, Klaten, and Flores students of Jember University Dent J. *Maj Ked Gigi*, 39: 116–119.
7. Patnaik VVG, Sanju B, Rajan SK (2001) Anatomy of the bony orbits-Some applied aspects. *J Anatom Society India*, 50: 59–67.
8. Piquet MM (1954) L'indice orbitaire et l'appréciation de la largeur de l'orbite: essai de standardisation, *Bull Mem Soc Anthropol Paris*, 5: 100–112.
9. Ukoha U, Egwu OA, Okafor IJ, Ogugua PC, Onwudinjo O, Udemezue O (2011) Orbital dimensions of adult male nigerians: a direct measurement study using dry skulls. *Int J Biol Med Res*, 2: 688–690.
10. Weaver AA, Loftis KL, Tan JC, Duma SM, Stitzel JD (2010) CT-based 3D measurement of orbit/eye anthropometry. *Investigative Ophthalmol Visual Science*, 51: 10.
11. Weiss RA, Haik BG, Saint-Louis LA, Ellsworth RM (1987) Advanced diagnostic imaging techniques in ophthalmology. *Ad Ophthalmic Plastic Reconstruct Surg*, 6: 207–263.
12. Whitehouse RW, Jackson A (1993) Measurement of orbital volumes following trauma using low dose computed tomography. *Eur Radiol*, 3: 145–149.