

Morphology of the foramen magnum in young Eastern European adults

F. Burdan^{1, 2}, J. Szumiło³, J. Walocha⁴, L. Klepacz⁵, B. Madej¹, W. Dworzański¹, R. Klepacz³, A. Dworzańska¹, E. Czekajska-Chehab⁶, A. Drop⁶

¹Department of Human Anatomy, Medical University of Lublin, Lublin, Poland

²St. John's Cancer Centre, Lublin, Poland

³Department of Clinical Pathomorphology, Medical University of Lublin, Lublin, Poland

⁴Department of Anatomy, Collegium Medicum, Jagiellonian University, Krakow, Poland

⁵Department of Psychiatry and Behavioural Sciences, Behavioural Health Centre, New York Medical College, Valhalla NY, USA

⁶Department of General Radiology and Nuclear Medicine, Medical University of Lublin, Lublin, Poland

[Received 21 July 2012; Accepted 7 September 2012]

Background: The foramen magnum is an important anatomical opening in the base of the skull through which the posterior cranial fossa communicates with the vertebral canal. It is also related to a number of pathological conditions including Chiari malformations, various tumours, and occipital dysplasias. The aim of the study was to evaluate the morphology of the foramen magnum in adult individuals in relation to sex.

Material and methods: The morphology of the foramen magnum was evaluated using 3D computer tomography images in 313 individuals (142 male, 171 female) aged 20–30 years.

Results: The mean values of the foramen length (37.06 ± 3.07 vs. 35.47 ± 2.60 mm), breadth (32.98 ± 2.78 vs. 30.95 ± 2.71 mm) and area (877.40 ± 131.64 vs. 781.57 ± 93.74 mm²) were significantly higher in males than in females. A significant, positive correlation was found between foramen length and breadth. Significant correlations were reported for breadth and area of the foramen magnum and corresponding external cranial diameters in females. Round as well as longitudinal and horizontal oval-like types of the foramen shape were established according to the breadth/length index of the structure. All the cranial and foramen measurements were significantly higher in individuals with round-like type of the foramen magnum.

Conclusions: There was a sexual dimorphism of the foramen magnum among the examined individuals. It was related mainly to its linear diameters and area, not to the shape. Unlike males, female skulls had higher correlation between the examined parameters of the foramen and proper external cranial measurements, which indicates more homogeneous growth in girls. (Folia Morphol 2012; 71, 4: 205–216)

Key words: sex dimorphism, skull base, posterior cranial fossa, forensic anthropology population data

INTRODUCTION

The foramen magnum is the largest opening located in the median plane of the cranial cavity. The foramen belongs to the posterior cranial fossa and connects it with the base of the skull and with the vertebral canal. The structure is completely surrounded by 4 principal components of the occipital bone: the supra-occipital part of the squama posteriorly, the basilar part anteriorly, and by two lateral parts on the right and left sides [38, 46]. These elements are connected by symmetrical posterior and anterior intraoccipital synchondroses. Fusion of the posterior synchondroses takes place at 2–4 years of age, while the anterior synchondroses start to fuse at the same age but continues until the age of 5–7 [53]. The basilar part is also connected anteriorly with the body of the sphenoid bone by the sphenoccipital (sphenobasilar) synchondrosis, which disappears between the ages of 16–22 for males and 11–19 for females [48]. Bogin [3] indicates that all 3 fusions are related to important maturational events: termination of the deciduous dentition eruption, starting of the permanent molars eruption, and completion of the major permanent dentition, respectively. After fusion of the basilar part of the occipital bone and the posterior surface of the sphenoidal body, the proper mature form of the clivus is observed. The structure extends from the anterior aspect of the foramen magnum and ends superiorly on the level of the dorsum sellae [38, 46].

The foramen is clinically important since the following structures pass through it: the medulla, meninges, accessory spinal nerve, dural sinuses, as well as the vertebral, posterior and anterior spinal arteries. The clivus also supports the brain stem. Since all of the bone elements are well palpated and visible during various radiological examinations, they are also important landmarks for neurosurgeons, radiologists, other physicians, and anthropologists [38, 46].

The aim of the present study was the morphological analysis of the foramen magnum in relation to sex and selected extracranial diameters in young adults in the age range 20–30 years. Since the sphenoccipital synchondrosis is not very visible in the evaluated age, instead of the basilar part of the occipital bone the direct distance between the foramen magnum and the dorsum sellae was measured. Unlike most of the previous studies in which the cranial morphology was evaluated on archaeological material [2, 6, 8–13, 18–22, 25–28, 36, 37, 39, 41–45, 47–52, 54, 56, 57], the current study was performed radiologically using computer tomogra-

phy (CT) images of the skull without any developmental and post-traumatic head abnormalities. Such a procedure allows a concomitant examination of both skull and brain morphology, and was helpful to exclude from the study group any individual with bone abnormalities (e.g. occipital vertebra), Chiari malformations, and various tumours localised on the level of the foramen magnum. It is particularly important for the last two groups of pathologies, which, in the early stages, might only slightly change the cranial anatomy and cannot be detected on dry specimens [4, 7, 14, 15, 49, 50, 55].

MATERIAL AND METHODS

The study was conducted on retrospective human data collected during diagnostic examinations at the First Department of Radiology and Nuclear Medicine, Medical University of Lublin. Records of 313 randomly selected Caucasian individuals in the age range 20–30 years (142 men: 24.53 ± 2.99 years, 171 female: 24.17 ± 2.78 years) were evaluated. The main purpose of performing the CT examination was headache and/or to exclude traumatic changes after an accident. No visible anatomical cranial and/or brain abnormalities were seen in this group.

All examinations were performed by means of a LightSpeed Ultra CT 64-row VCT (GM Medical System). They were conducted with a standard clinical protocol in layers of 5 and 2.5 mm above and below the upper Frankfort line, respectively. During post-processing, spatial imaging of the skull was performed using the volumetric option. External skull diameters were measured according to guidelines for anthropological research [32, 40]. The length of the skull was assumed as the distance between the glabella and opisthocranium (G-Op). The cranial breadth was measured between the 2 most remote points located on the right and the left side of the skull (Eurion-Eurion; Eu-Eu). After removing the calvaria, the maximal length (FmL [Basion-Opisthion; Ba-O]) and breadth (FmB) of the foramen magnum, as well as the distance between the posterior aspect of the dorsum sellae and the anterior pole of the foramen magnum (Basion; Ba) were established at the level of the median plane. Using the option of automatic field setting, the area of the foramen magnum was calculated. All the measurements were carried out in the horizontal plane having an upper view of the internal cranial cavity. The cross-sectional area of the skull (SA) was calculated using the following formula: $SA = \pi ab$, where a and b indicate half of the length (G-Op) and breadth (Eu-Eu) of the oval, respectively. All measurements were per-

formed using a self-calibrated measurement window, which guaranteed the full repeatability of results. Using an original anthropological formula [32], the index of the skull (skull index = Eu-Eu/G-Op [absolute value] or = $100 \times [\text{Eu-Eu/G-Op}]$ [relative value; %]) and the foramen magnum (foramen Index = FmB/FmL [absolute value] or = $100 \times [\text{FmB/FmL}]$ [relative value; %]) was calculated.

Skull index was used to include each individual into one of the 4 principal anthropological groups [32], i.e. dolichocephalus (male: index < 75.9; female: index < 76.9) mesocephalus (male: = 76.0–80.9; female: = 77.0–81.9) brachycephalus (male: = 81.0–85.4; female: = 82.0–86.4) and hyperbrachycephalus (male: > 85.5; female: > 96.5).

Based on the length (FmL) and breadth (FmB) of the foramen magnum, its shape was also divided into either oval-like or round-like type. The round-like type was defined as an FmB/FmL quotient which was between 0.9–1.1 (90–110%). Structures with a value below or above this interval were included in the longitudinal and horizontal oval-like types, respectively. Moreover, similar to the skull, based on the foramen index [32], each structure was classified into one of the 3 groups: dolichotrematous (oval; index < 81.9), mesotrematous (flattened oval; index = 81.9–85.9) and brachytrematous (round; index > 86.0). The shape of the foramen was also evaluated according to a recently published qualitative classification (Fig. 1) [42], which in our opinion is the most precise one.

The obtained data was presented using: arithmetical mean, 95% confidence interval (CI), median (Me), minimal–maximal values (Min.–Max.), and standard deviation (SD). Distribution of the data was checked using the Kolmogorov-Smirnov test. Differences were analysed using the t-Student. Correlations between the selected parameters were also

checked. A nominal scale measures were analysed by χ^2 test. A 0.05 level ($p < 0.05$) of probability was used as the criterion of significance.

RESULTS

Well-formed, typical anatomical structures without any significant developmental or post-traumatic variances were observed in the analysed skulls. Their morphology corresponded to the calendar age of the examined individuals. However, 3 cases of persistent frontal suture and occasionally visible the speno-occipital synchondrosis (male/female: 19/27) were found.

All types of the foramen magnum distinguished previously by Richards and Jabbour [42] were seen in the evaluated population (Table 1, Fig. 2). A typical, longitudinal oval-like type of the foramen magnum — mainly wide oval or ventrally wide oval — was more commonly found in both males ($n = 75$) and females ($n = 110$). The round-like type — generally the two semicircle variation or the very wide type of bi-rounded oval — was detected in 65 and 57 cases, respectively. A lack of significant differences was found in the frequency of anatomical variations between both sexes. In 6 cases a horizontal oval-like type of foramen was observed (2/4). Their shape corresponded to the two semicircle type according to the Richards and Jabbour [42] data. Advance asymmetrical forms were also visible; however, they were classified into one of eight original types, most of them belonging to the two semicircle type (Fig. 2J). Using a traditional anthropological classification [32], the most common type of the foramen was brachytrematous, which was observed in 94 cases in both males and females. Less frequently dolichotrematous (27/38) and mesotre-

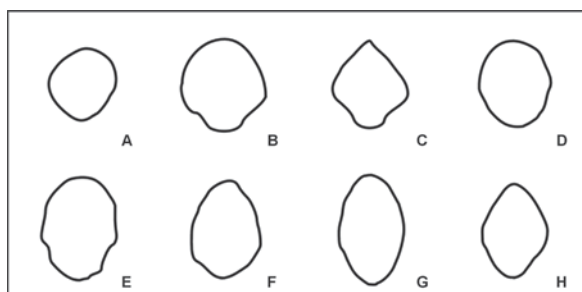


Figure 1. Anatomical variances of the shape of the foramen magnum according to Richards and Jabbour [42]; **A.** Circular; **B.** Two semicircle; **C.** Heart-like; **D.** Wide oval; **E.** Bi-rounded oval; **F.** Ventrally wide oval; **G.** Bi-pointed oval; **H.** Dorsally convergent oval.

Table 1. Anatomical variances of the shape of the foramen magnum according Richard and Jabbour [42] classification, among the examined population

	Male	Female
Circular	10 (7.04%)	17 (9.94%)
Two semicircle	25 (17.61%) ^a	33 (19.30%) ^b
Heart-like	6 (4.23%)	6 (3.51%)
Wide oval	52 (36.62%) ^c	67 (39.18%) ^d
Bi-rounded oval	13 (9.15%) ^e	6 (3.51%)
Ventrally wide oval	20 (14.08%)	24 (14.04%)
Bi-pointed oval	3 (2.11%)	7 (4.09%)
Dorsally convergent oval	13 (9.15%)	11 (6.43%)

Advance asymmetry was observed in ^a2, ^b4, ^c2, ^d3, and ^e2 cases; $p = 0.4325$

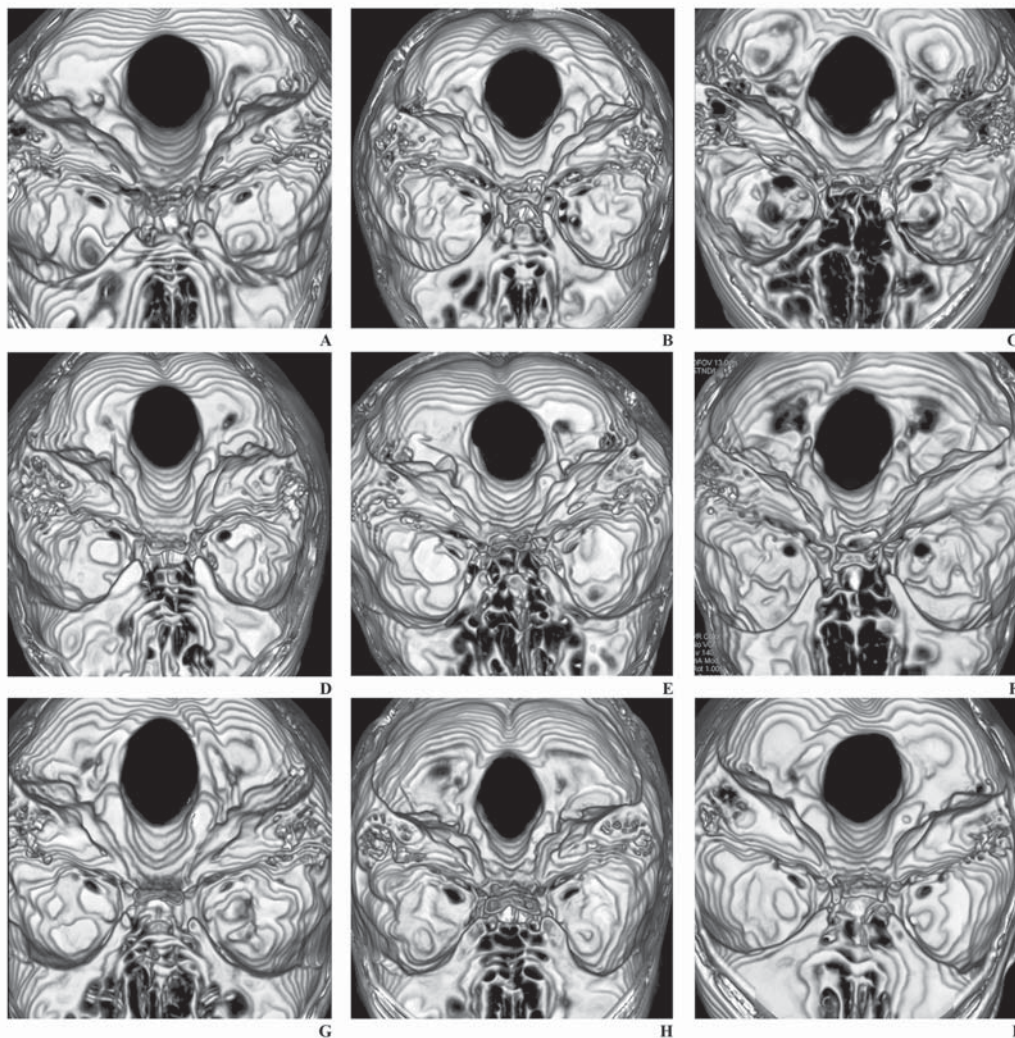


Figure 2. Morphology of the foramen magnum in the pseudo-3D CT reconstruction; **A.** Circular; **B.** Two semicircle; **C.** Heart-like; **D.** Wide oval; **E.** Bi-rounded oval; **F.** Ventrally wide oval; **G.** Bi-pointed oval; **H.** Dorsally convergent oval; **J.** Asymmetrical two semicircle.

matous (21/39) types were seen. In a few cases (34/23) a different degree of dorsum sellae pneumatisation was reported.

A statistically significant increase in the skull length, breadth, and cross-section area was found in males when compared with females (Table 2). Similar dependencies were established for the length and area of the foramen magnum.

There were statistically significant differences in the examined parameters of the skull and foramen magnum in relation to sex and shape of the foramen (Tables 3, 4). Significantly higher linear parameters and area of the foramen magnum were found in the male group with round-like type of the examined structure (Table 3). Higher values were also established for the length and breadth of round-like foramina in comparison with longitudinally oval-like foramina in both

males and females. Similar dependences were found with regard to external cranial parameters (Table 4). However, insignificant changes were observed between both types of foramina in the same sex.

Among the male group, most of the oval-like foramina (18 out of 75) were seen in hyperbrachycephalic individuals (Table 5), while in females they were found mainly in brachycephalic (52/110) and hyperbrachycephalic (26/110) persons (Table 6). Similar data was established for the round-like type of foramen magnum. However, unlike males in whom the dominant skull type was brachycephalic (31/65), in females the frequency of all skull types was more variable: brachycephalic (29/57), hyperbrachycephalic (17/57), mesocephalic (9/57), and dolichocephalic (3/57).

A significant, positive correlation was found between the length and breadth of the foramen mag-

Table 2. External and internal diameters of the skull in males (M) and females (F)

		Sex	Mean	CI -95%	CI +95%	Me	Min.	Max.	SD	p
Skull	Length [mm]	M	181.22	179.97	182.47	180.35	161.30	198.50	7.53	0.0001
		F	172.59	171.26	173.92	173.30	138.10	189.90	8.79	
	Breadth [mm]	M	149.33	148.24	150.42	149.25	129.30	178.00	6.57	
		F	144.22	143.07	145.37	143.20	126.40	189.20	7.61	
Cross-section area [mm ²]	M	21248.69	21025.13	21472.24	21340.03	16372.03	25151.40	1347.53	0.0001	
	F	19534.16	19332.84	19735.49	19480.56	15550.47	23305.63	1333.66		
Breadth/length index	M	82.52	81.75	83.30	82.76	72.35	98.89	4.66	0.0659	
	F	83.82	82.73	84.91	82.58	70.81	137.00	7.23		
Foramen magnum	Length [mm]	M	37.06	36.55	37.57	36.90	30.00	48.50	3.07	0.0001
		F	35.47	35.08	35.86	35.60	29.00	42.70	2.60	
	Breadth [mm]	M	32.98	32.51	33.44	33.05	24.80	39.70	2.78	
		F	30.95	30.54	31.36	30.80	20.10	37.50	2.71	
Area [mm ²]	M	877.40	855.56	899.23	864.30	567.20	1354.30	131.64	0.0001	
	F	781.57	767.42	795.72	773.70	563.90	1088.70	93.74		
Breadth/length index	M	89.34	87.95	90.73	88.89	70.45	128.00	8.35	0.0609	
	F	87.55	86.29	88.82	86.99	59.47	115.41	8.37		
Distance between the foramen magnum and the dorsum sellae [mm]	M	24.32	23.51	25.13	24.65	11.40	35.00	4.87	0.6096	
	F	23.98	23.27	24.70	24.40	3.50	36.10	4.74		

Table 3. Diameters of foramen magnum (M ± SD) in male and female individuals with longitudinal oval- and round-like types of the foramen magnum

	Oval-like		Round-like		p
	Male	Female	Male	Female	
Length [mm]	38.17 ± 2.94*	36.18 ± 2.037	35.97 ± 2.62*,#	34.38 ± 2.50#	0.0001
Breadth [mm]	31.74 ± 2.63*	29.96 ± 2.42	34.28 ± 2.23*,#	32.52 ± 2.13#	0.0001
Area [mm ²]	878.42 ± 138.43*	777.50 ± 89.95	879.80 ± 126.86*	789.38 ± 98.15	0.0001

*male vs. female; #oval-like vs. round-like

Table 4. Cranial parameters (M ± SD) in male and female individuals with longitudinal oval- and round-like types of the foramen magnum

	Oval-like		Round-like		p
	Male	Female	Male	Female	
Length [mm]	177.29 ± 4.94*	171.10 ± 9.67	179.47 ± 6.00	171.87 ± 9.11	0.01
Breadth [mm]	147.08 ± 5.73*	143.39 ± 9.12	151.19 ± 8.76	143.88 ± 6.52	0.05
Area [mm ²]	20466.19 ± 889.53*	19260.32 ± 1636.41	21311.43 ± 1569.66	19429.39 ± 1544.54	0.001

*male vs. female

Table 5. Frequency of the longitudinal oval- and round-like types of the foramen magnum in male individuals according to skull shape

Skull type (skull index)*	Oval-like	Round-like
Dolichocephalus (< 75.9)	7 (9.33%)	4 (6.15%)
Mesocephalus (76–80.9)	24 (32.00%)	16 (24.62%)
Brachycephalus (81.0–85.4)	26 (34.67%)	31 (47.69%)
Hyperbrachycephalus (> 85.5)	18 (24.00%)	14 (21.54%)

*Skull index (%) according to the Martin formula = (Eu-Eu/G-Op) × 100; p = 0.4462

Table 6. Frequency of the longitudinal oval- and round-like types of the foramen magnum in female individuals according to skull shape

Skull type (skull index)*	Oval-like	Round-like
Dolichocephalus (< 75.9)	7 (6.36%)	2 (3.51%)
Mesocephalus (76–80.9)	25 (22.73%)	9 (15.79%)
Brachycephalus (81.0–85.4)	52 (47.27%)	29 (50.88%)
Hyperbrachycephalus (> 85.5)	26 (23.64%)	17 (29.82%)

*Skull index (%) according to the Martin formula = (Eu-Eu/G-Op) × 100; p = 0.5355

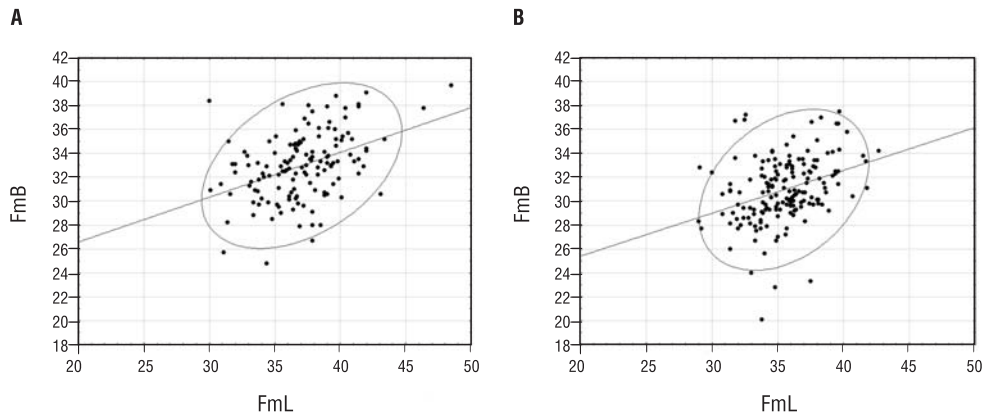


Figure 3. The length of the foramen magnum (FmL) in relation to its breadth (FmB) in males: **A.** $y = 19.0956 + 0.3745x$; $r = 0.4139$, $p < 0.0001$, and females: **B.** $y = 18.2151 + 0.3592x$; $r = 0.3439$, $p < 0.0001$). Data is presented in [mm].

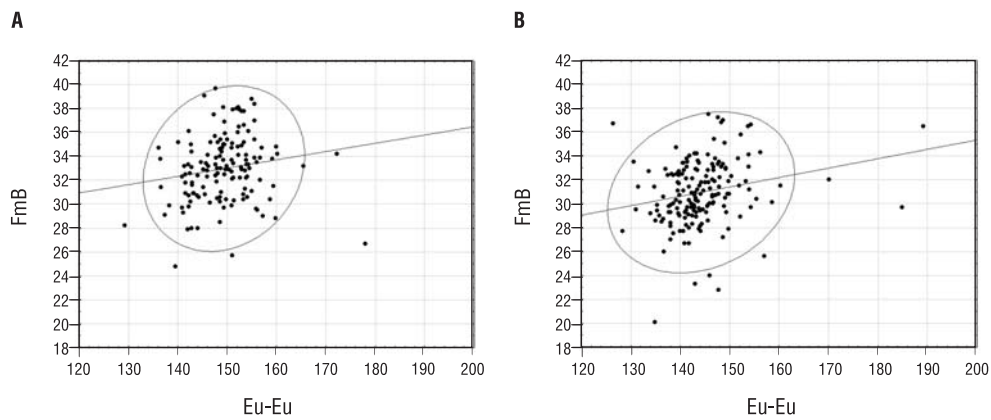


Figure 4. The breadth of the foramen magnum (FmB) in relation to the skull breadth (Eu-Eu) in males: **A.** $y = 22.6454 + 0.0692x$; $r = 0.1635$, $p = 0.0519$, and females: **B.** $y = 19.6077 + 0.0787x$; $r = 0.2209$; $p = 0.0037$. Data is presented in [mm].

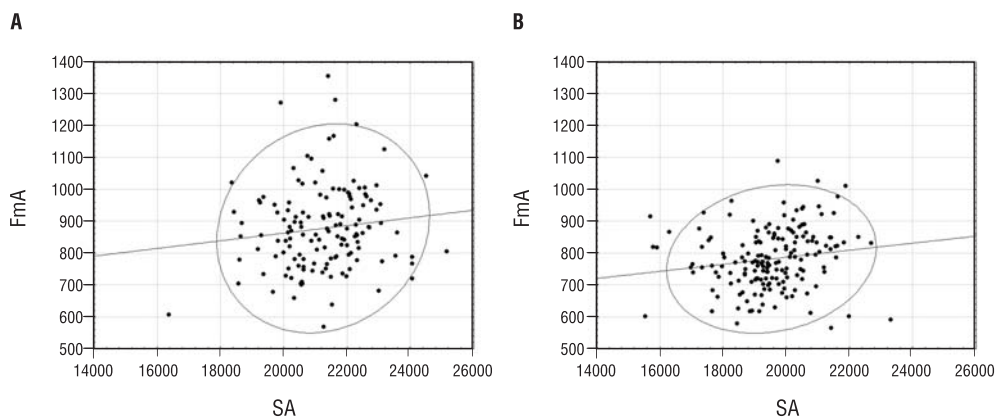


Figure 5. The area of the foramen magnum (FmA) in relation to the skull cross-section area (SA) in males: **A.** $y = 622.3787 + 0.012x$; $r = 0.1229$; $p = 0.1453$, and females: **B.** $y = 565.589 + 0.111x$; $r = 0.1573$; $p = 0.0399$. Data is presented in [mm²].

num in both males and females (Fig. 3). For females, a positive correlation was also found between the breadth and area of the foramen magnum and cranial breadth (Fig. 4) and skull cross section area (Fig. 5),

respectively. In males, both correlations were insignificant. A lack of correlation was also established for the cranial (x) and foramen length (y) in both males ($y = 25.9743 + 0.0612x$; $r = 0.1499$; $p = 0.0749$) and

Table 7. Relative values (%) of the examined skull parameters according to the external cranial diameters

	Male	Female	p
Sagittal diameter/skull length			
Length of the foramen magnum	20.47 ± 1.77	20.61 ± 1.91	0.5224
Distance between the foramen magnum and the dorsum sellae	13.44 ± 2.75	13.93 ± 2.83	0.1276
Transversal diameters/skull breadth			
Breadth of the foramen magnum	22.11 ± 1.91	21.50 ± 1.95	0.0057
Area/area of the skull			
Area of the foramen magnum	4.14 ± 0.64	4.02 ± 0.52	0.0583

females ($y = 35.5019 - 0.0002x$; $r = -0.0006$; $p = 0.9933$). Similar data was reported for the skull index (x) and foramen index (y) in males ($y = 78.544 + 0.1308x$; $r = 0.0730$; $p = 0.3879$) and females ($y = 90.7728 - 0.0384x$; $r = -0.0332$; $p = 0.6668$).

Unlike cranial and foramen parameters, the distance between the dorsum sellae and the foramen magnum was insignificantly lower in males than it was in females (Table 2).

The relative breadth of the foramen magnum in relation to the skull breadth was significantly higher in males (Table 7). All other relative data differed insignificantly between both sexes.

DISCUSSION

The collected data indicates a sexual dimorphism of the foramen magnum, but only in relation to its size. The shape of the structure was similar in both sexes, and the longitudinal oval-like forms were the most commonly observed. However, it has to be pointed that the observed sexual differences are much lower than in long bones and the pelvis. It is probably secondary to early growing/fusing of cranial bones, since the skull reaches near-adult values before the growth spurt and the difference in size between males and females is low [26].

The obtained diameters of the foramen magnum are comparable with the value presented by most of the other authors (Table 8). The differences seem to be related to group size, ethnicity, and geographical and methodological differences, as well as to the fact that in the current study the male and female data are presented separately. Most of the listed studies were also conducted on dry, historical skulls. Gruber et al. [21] did not establish any significant differences between male and female individuals. However, a sexual dimorphism was pointed out by other scientists (see below) but mostly in papers specifically devoted to the foramen magnum dimensions [18] and in articles in which

special multivariate formulae that incorporate several dimensions from the cranial base were used. Giles and Elliot [19], using Fisher's method properly, established the sex for Negroid and Caucasian in 82 and 89%, respectively $\{D_{\text{male}} = [(8.227 \times \text{length of occipital condyle}) + (6.885 \times \text{width of occipital condyle}) + (5.817 \times \text{FmB})] - 227.181\}$. A lower degree of correct determination of male (79.4%) and female (79.1%) in Finnish skulls was revealed using the discriminant function analysis by Kajanoja [28]. The same method was applied by Westcott and Moore-Jansen [56] as well as Henke [24], but the accuracy reached 76% and 88%, respectively. The highest percentage was presented by Routal et al. [44] (100%), Uysal et al. [55] (81%), and by Holland [25] (71–90%), who applied regression equations. However, based on the examination of the 158 skulls and using the above listed methods, Gapert et al. [18] stressed that the dimensions of the foramen magnum are of limited value for sex determination. It should be clearly pointed out that the measurements and morphology of the foramen serve only as an additional confirmation of sex when other more traditional classification methods have already been employed.

Most of the modern articles that explain the foramen magnum morphology are related to the Chiari malformation, which is defined as ectopia of the cerebellar tonsil at least 5 mm below the foramen (Chiari malformation type I: CM-I) [33]. Less frequently such herniations are complicated with myelodysplasia (CM-II) and cervical encephalocele (CM-III), as well as abnormalities of the paraxial mesoderm and maldevelopment of the contents of the posterior cranial fossa or other diseases, e.g. hydrocephalus, tumours of the central nervous system, or Paget's disease. Generally, the size, in particular the transversal diameter and area of the foramen, is smaller in non-complicated CM-I, but significantly higher values for all its measurements were found in the case of CM-I complicated with tethered cord syndrome and for CM-II. In all

Table 8. Current and historical data on linear diameters [mm] and area [mm²] of the foramen magnum in individuals over 9 years of age

Reference (skull origin)	Methods	Sex	No.	Age (year)	Foramen magnum ^a		
					Length	Breadth	Area
Burdan et al. (Poland)	CT	M	30	24.66 ± 3.37	36.89 ± 3.17	32.47 ± 3.08	881.44 ± 149.80
		F	30	24.76 ± 2.72	34.76 ± 2.96	30.96 ± 3.01	765.29 ± 92.48
Richards and Jabbour [42] (North America)	DS ^b	n/a	22	9.0	37.05 ± 3.30	27.61 ± 1.60	n/a
			13	10.0	37.88 ± 2.48	28.81 ± 1.64	n/a
			8	12.0	37.69 ± 3.33	27.81 ± 2.71	n/a
			22	15	35.80 ± 2.92	28.30 ± 2.11	n/a
			23	18–21	37.22 ± 2.21	29.22 ± 2.25	n/a
Dufton et al. [14] (Canada)	MR	M/F	44/63 ^c	41.93 ± 14.70	3.63 ± 0.31	n/a	n/a
Milhorat et al. [33] (USA)	CT, MR	M/F	25/55 ^c	31.7 ± 11.8	32.5 ± 3.17	30.8 ± 5.74	787.70 ± 118.4
Gapert et al. [18] (England)	DS ^d	M	82	52.5 ± 18.5	35.91 ± 2.41	30.51 ± 1.77	862.41 ± 94.79 ^e
		F	76	55.3 ± 18.2	34.71 ± 1.91	29.36 ± 1.96	868.95 ± 96.36 ^f
							801.78 ± 85.43 ^e
						808.14 ± 85.40 ^f	
Gruber et al. [21] (Central Western Europe)	DS ^g	n/a	111	20–80	36.6 ± 2.8	31.1 ± 2.7	n/a
		M	28	n/a	37.1 ± 2.7	32.4 ± 2.4	n/a
		F	21	n/a	35.8 ± 3.5	31.0 ± 2.8	n/a
Tubbs et al. [54] (n/a)	DS	M/F	40/32 ^c	50–90	31.0 (25–37)	27 (24–35)	558 (335–779)
Acer et al. [1] (Turkey)	DS	n/a	n/a	n/a	n/a	n/a	760 ± 144
Uysal et al. [55] (Turkey)	CT	M	48	18–83	37.08 ± 1.94	30.83 ± 2.04	n/a
		F	52	18–83	34.87 ± 2.61	18.93 ± 2.44	n/a
Muthukumar et al. [37] (India)	DS	n/a	50	n/a	33.3 (27–39)	27.9 (23–32)	n/a
Murshed et al. [36] (Turkey)	DS	M	57	n/a	37.2 ± 3.43	31.6 ± 2.99	931.7 ± 144.29
		F	53	n/a	34.6 ± 3.16	29.3 ± 2.19	795.0 ± 99.32
Berge and Bergmann [2] (n/a)	DS	n/a	100	n/a	33.8 (24–53)	28.3 (23–41)	n/a
Günay and Altinkök [22] (Turkey)	DS	M	170	n/a	n/a	n/a	909.91 ± 126.02
		F	39	n/a	n/a	n/a	819.01 ± 117.24
Sendemir et al. [47] (Turkey)	DS ^h	n/a	38	n/a	35.6 ± 2.3	29.9 ± 2.1	n/a
		n/a	27	n/a	35.1 ± 2.8	28.7 ± 2.2	n/a
		n/a	23	n/a	36.4 ± 2.8	30.0 ± 1.4	n/a
Lang [30] (n/a)	DS	n/a	n/a	n/a	35.33 (30.0–41.0)	29.6 (21.4–37.6)	n/a
Catalina-Herrera [8] (Spain)	DS	M	74	n/a	36.2 ± 0.3 ^j	31.1 ± 0.3 ^j	888.4 ± 13.9 ⁱ
		F	26	n/a	34.6 ± 0.4 ^j	29.6 ± 0.3 ^j	801.0 ± 17.4 ⁱ
Routal et al. [44] (India)	DS	M	104	n/a	35.5 ± 2.8	32.0 ± 2.8	819.0 ± 94 ^e
		F	37	n/a	29.6 ± 1.9	27.1 ± 1.6	771.0 ± 90 ^e
Teixeira [51] (Brazil)	DS	M	20	n/a	n/a	n/a	963.73 ± 140 ^f
		F	20	n/a	n/a	n/a	805.65 ± 105 ^f
Olivier [39] (France)	DS	M/F	124	n/a	35.70 ± 2.72	30.34 ± 2.15	n/a
		M	68	n/a	36.06 ± 2.85	30.82 ± 2.07	n/a
		F	56	n/a	35.20 ± 2.25	29.76 ± 2.15	n/a
Coin and Malkasian [9] (n/a)	X	n/a	42	n/a	34 (32–36)	29 (25–34)	n/a

CT — computer tomography, MR — magnetic resonance, X — classic X-ray, DS — dry skull, n/a — unknown data, M/F — male/female; ^aData presented as mean (M), mean ± standard deviation (M ± SD), or mean with a maximal and minimal value — M (Min.–Max.); ^bData only for statistically representative age group (≥ 8 cases) and in age over 8 years (ossification of the anterior intraoccipital synchondrosis); ^cmale/female (M/F); ^d18th–19th century; ^e= 1/4 × π × FmL × FmB; ^f= π × [(FmL + FmB)/4]²; ^gLate Pleistocene to modern time; ^h13th century; ⁱ20th century; ^jmean ± SEM instead of SD

of these cases the volume of the posterior cranial fossa was smaller than in healthy individuals. The correlation between foramen morphology and size of the posterior cranial fossa was also highlighted by Acer et al. [1]. It is worth mentioning that cranial constriction, spinal cord tethering, cranial setting, intracranial hypertension, and intraspinal hypotension increase the risk of cerebellar tonsil herniation and abnormality of the foramen magnum [33].

The shape of the evaluated structure results from developmental changes that influence the morphology of the 4 principal parts of the occipital bone and the intra-occipital synchondroses that connect them. Based on previous observations [34, 35], Richards and Jabbour [42] divided the proper foramen magnum as well as the entire surrounded hard (atlas, dens of axis) and soft elements (ligaments, membranes) into ventral and dorsal parts that comprise 2 functional matrices. The ventral one includes skeletomotor-related structures — the ventrolateral border of the foramen (extending to a line between the bilaterally located anterior intraoccipital synchondroses), anterior longitudinal ligament, ventral arch of the atlas, anterior atlanto-occipital membrane, apical ligament and dens of the axis, cruciform and alar ligaments, as well as the tectorial membrane which separates it from the dorsal matrix. All the listed structures are important for the proper movement and stabilisation of the skull. Unlike the ventral matrix, the dorsal matrix is less involved in head motions but transmits important neurovascular elements. It contains the posterior edge of the foramen magnum, spinal cord, meninges and subarachnoid space, posterior atlanto-occipital membrane, the dorsal arch of the axis, as well as the accessory spinal nerve and various vascular structures, as listed in the introduction. As was stressed above, any abnormal development of the listed structure may significantly change the morphology of the foramen. The most common type are the previously presented Chiari malformations [33]. However, a number of brain and meningeal tumours, as well as various occipital dysplasias — particularly assimilation of the atlas with the occipital bone and irregular formation of the occipital condyles — may also cause encroachment into the foramen [33, 41, 52].

Ford [16] reported that the length of the foramen increases more rapidly during the prenatal period when compared to its breadth. However, recently published data [42] shows that the in utero elongation of the foramen magnum from the 7th gestational month until birth is secondary mainly to the increasing length of its dorsal unit, while the length of the ventral unit does not differ significantly.

Such growth changes reverse in the early postnatal period (0–6 months). The dynamics of the process slow down after 1 year of age, when the dorsal unit reaches mature size but the length of the ventral unit continues to increase slowly until both anterior intraoccipital synchondroses become fully calcified (< 8.2 years). The postnatal period is also characterised by growth where changes in breadth dominate over changes in length. The breadth-dominated growth pattern is even longer and continues until about 9.5–10.0 years of age. Secondary to those changes, the foramen index also changes from 62.7–65.7% in the very early stages of the prenatal period to 69.8–71.0% at 0.75–2.5 years, and later becomes more stable at 62.7–79.9%, with a mean value $78.88 \pm 4.25\%$ for adults (> 18 years). Unlike in the present results, in adult native South Africans, a high predilection of dolichotrematous and low frequency of meso- and brachytrematous foramina was found by De Villiers [12]. However, similar to our data, a much greater range of the index value (71.0–111.0%) was presented by other authors [7, 10, 18, 32]. All the authors note an oval or oval-to-round form of the foramen magnum as the dominant one for modern adult *Homo sapiens*. However, the shape may change during ontogeny. Richards and Jabbour [42] found 8 developmental variations (Fig. 1) that were noted in 470 examined skulls during various stage of human life from the 7th gestational month to 21 years of age. During the foetal period, the following forms were seen: a bi-rounded oval, a ventrally wide oval, a bi-pointed oval, and a dorsally convergent oval. According to the authors, a predominance of the oval variations was also visible during the postnatal period due to the growth of the anterior intraoccipital synchondroses. Similar to the current examined human population, in which the frequency of longitudinally oval (mostly bi-rounded and ventrally wide) and round types (two semicircle) were similar, the main tendency pointed by Richards and Jabbour [42] was an increase in the ventral breadth of the foramen making the foramen anteriorly wide, not fully circular. A low incidence of the proper circular variation was also found in the currently examined population. The differences in the frequencies of each variation may be secondary to various geographic and age ranges since most of the archaeological skulls (4500–100 years old) came from North America and their biological age was below 21 years of age. However, the main objection to such results is the fact that the study was based

mostly on dried skulls, without the possibility of establishing the correct developmental follow-up changes that may occur in individuals.

According to the classification and data previously presented by Lang [30], a higher frequency of the two semicircle form is more typical for adult (41.2%) than for child skulls (18.2%). The occurrence of the other postnatal forms is as follows: elongated circle — wide oval according to Richards and Jabbour [42] (adult/children: 22.4/20.4%), egg-shaped — ventrally wide oval RJ (17.6/25.5%), rhomboid — dorsally convergent oval and heart-like form RJ (11.8/31.6%), rounded — circular RJ (7/4%). Similar observations were made on 200 Indian skulls by Zaidi and Dayal [57], but the authors used their own geometrical classification of the foramen shape: oval — various oval types from RJ (64%), hexagonal — two semicircle from RJ (24.5%), pentagonal — heart-like like from RJ (7.5%), irregular (3.5%), and circle (0.5%). This adult data is similar to the results obtained from the currently examined Polish population and seems to be typical for the modern human in which various oval shapes and two semicircle forms are the most commonly observed.

On the other hand, by having a large multigenerational population, Richards and Jabbour [42] were able to evaluate the relationships between the diameters of the foramen magnum and the cranial vault, which our data also partially confirmed. Regardless of age, they found that dolichocephalic individuals had 1 of 5 oval variants of the foramen magnum (no specific one was pointed out) and a low incidence of the circular one, while mesocephalic, brachycephalic, and hyperbrachycephalic skulls were characterised by all 8 forms. Moreover, Rude and Mertzlufft [45], similar to our study, found a higher correlation of examined foramen and cranial measurements in female than in male skulls. The collected findings were interpreted as an indication of more homogeneous female growth. It should also be pointed out that, like in our study, a positive linear correlation between foramen length and breadth was found by Gruber et al. [21] and Olivier [39].

It should also be noted that our data does not match the results presented by Tubbs et al. [54], who established three principle types of foramen magnum based on its area. None of the currently examined individuals met the criteria for type I (area < 500 mm²). Only 4 foramina (1/3) were classified as type II (500–600 mm²), while the remaining 309 individuals met type III (> 600 mm²) criteria. For comparison, among all of the 72 dry skulls examined by Tubbs et

al. [54] 15, 48, and 9 cases were classified to first, second, and third type, respectively. Such data clearly differs not only from our results but also from all the data compiled from the bibliography (Table 8), in spite of the diversity of employed measurement methods. It could be easily proven by the mean area of the foramen that, according to Tubbs et al. [54], is 558 mm², while in other studies is always over 760 mm², even over 800 mm².

Moreover, it was also postulated that the size of the foramen magnum is related to the volume of the brain, in particular to the brain stem and the cerebellum, which occupy the posterior cranial fossa [16]. Such observations were partially confirmed by the observations presented above relating to the size of the foramen and the volume of the fossa [1, 33]. However, the role of the so-called ventral skeletal unit of the foramen (posterior or occipital part of the clivus), which corresponds with the basilar part of the occipital bone, was also pointed [42]. Evaluation of the basioccipital length (sphenobasion [Spba]-Ba) and Spba-BiSam (point located posteriorly on the line connecting the right and left anterior interoccipital synchondroses) distance indicated a significant increase only between the 7th and 8th gestational months. Later, unlike the foramen magnum, the growth of the unit stabilised until birth, and slowly continued until the end of the 3rd year of life. Its growth corresponds with developmental changes to the ventral aspect of the foramen magnum, indicating the contribution of the anterior intraoccipital synchondroses to the final length of the foramen as well as the clivus. Its length increases between the ages of three and five years, followed by a slow minor increase until the sphenoccipital synchondrosis disappears around the age of 20 years. Based on current data, it should be stressed that such a process may have different sex-dependent dynamics, since the direct distance between the foramen magnum and the dorsum sellae was found to be insignificantly longer in females, characterised in the currently discussed population as having a significantly smaller foramen magnum. On the other hand, these differences may be related to clivus inclination, which was not examined.

It was also pointed out that the sexual dimorphism of the foramen magnum might be at least loosely related to stature [43], as well as to the dimensions of the vertebral canal [23, 29] and spinal cord [17]. The last elements correlate with the number of motor and sensory neuronal fibres that connect the brain with the peripheral structures (muscles, glands) and detectors (sensory receptors), and as such is related to body size [17, 21]. Although this hypothesis seems

logical and plausible, it has not been proven in clinical studies to this date. However, the primate data indicates that the size of the foramen and spinal cord is not straightforward, although the size of the vertebral canal is a good predictor of spinal cord size [31]. Moreover, spinal cord weight at the intraspecies level is not related to the number of neurons, but to the density of non-neuronal cells, and possibly to variations across individuals in cell size [5]. It has been shown that the spinal cord mass is related to the organ length, and hence indirectly to the body length, more than to body weight.

Generally speaking, the foramen magnum development is regulated by various biological (mostly genetic and hormonal) and non-biological factors during the pre- and postnatal periods. The non-biological group includes an asymmetrical foetal position in the uterine cavity, which may result in changes within muscle attachments. The majority of anatomical brain abnormalities also involve the asymmetrical deformity of cranial bones [6, 46, 52]. Patients with achondroplasia were found to have an abnormally shaped foramen magnum, which was smaller in size, influencing the flow of blood and cerebrospinal fluid [41, 42]. In the postnatal period, the main role in abnormal, acquisitive bone formation is played by malnutrition and pathological states directly affecting bone mineralisation as well as prevalent customs [8, 18, 52].

The main limitation of the current study is the relatively small group size ($n = 313$) of evaluated individuals. On the other hand, it is the biggest one in available literature (Table 8), but since all examined persons were randomly chosen the obtained data seems to be representative of at least a Polish or even Eastern European Caucasian population (of the same age). On the other hand, the calculated cross-sectional area of the skull does not always fully project with the proper one, since both parameters used in the calculation (Eu-Eu and G-Op distance) do not always lie on the same horizontal plane. However, the value of the cranial area was only an accessory parameter, which does not directly influence other ones.

CONCLUSIONS

The foramen magnum showed a weak sexual dimorphism among the examined individuals. This was related mainly to the length and area of the structure, not to its shape. Unlike in males, female skulls had a higher correlation between the examined parameters of the foramen and proper external cranial measurements, which indicates a more homogeneous growth.

REFERENCES

1. Acer N, Sahin B, Ekinçi N, Ergür H, Basaloglu H (2006) Relation between intracranial volume and the surface area of the foramen magnum. *J Craniofac Surg*, 17: 326–330.
2. Berge JK, Bergman RA (2001) Variations in size and in symmetry of foramina of the human skull. *Clin Anat*, 14: 406–413.
3. Bogin B (1997) Evolutionary hypotheses for human childhood. *Year Book Physic Antropol*, 40: 63–89.
4. Burdan F, Umlawska W, Dworżański W, Klepacz R, Szumiło J, Starosławska E, Drop A (2011) Anatomical variances and dimensions of the superior orbital fissure and foramen ovale in adults. *Folia Morphol*, 70: 263–271.
5. Burish MJ, Peebles JK, Baldwin MK, Tavares L, Kaas JH, Herculano-Houzel S (2010) Cellular scaling rules for primate spinal cords. *Brain Behav Evol*, 76: 45–59.
6. Calcaterra TC, Cherney EF, Hanafee WF (1973) Normal variations in size and neoplastic changes of skull foramina. *Laryngoscope*, 83: 1385–1397.
7. Calvy TM, Segall HD, Gilles FH, Bird CR, Zee CS, Ahmadi J, Biddle R (1987) CT anatomy of the craniovertebral junction in infants and children. *Am J Neuroradiol*, 8: 489–494.
8. Catalina-Herrera CJ (1987) Study of the anatomic metric values of the foramen magnum and its relation to sex. *Acta Anat*, 130: 344–347.
9. Coin CG, Malkasian DR (1971) Foramen magnum. In: Newton TH, Potts DG eds. *Radiology of the skull and brain: the skull*. Mosby, St. Louis, pp. 275–347.
10. Coqueugniot H (1999) *Le crane d'Homo sapiens en Eurasie: Croissance et variation depuis 100,00 ans*, Technical Report 822. British Archaeological Reports, International Series, London.
11. Daimi SR, Siddiqui AU, Gill SS (2011) Analysis of foramen ovale with special emphasis on pterygoalar bar and pterygoalar foramen. *Folia Morphol*, 70: 149–153.
12. De Villiers H (1968) *The skull of the South Africa Negro*. Witwatersrand University Press, Johannesburg.
13. Dharwal K (2012) Foramina parietalia permagna: the ins and outs. *Folia Morphol*, 71: 78–81.
14. Dufton JA, Habeeb SY, Heran MK, Mikulis DJ, Islam O (2011) Posterior fossa measurements in patients with and without Chiari I malformation. *Can J Neurol Sci*, 38: 452–455.
15. Emirzeoglu M, Sahin B, Celebi M, Uzun A, Bilgic S, Tontus HO (2012) Estimation of nasal cavity and conchae volumes by stereological method. *Folia Morphol*, 71: 105–108.
16. Ford HER (1956) Growth of the foetal skull. *J Anat*, 90: 63–72.
17. Fox JH, Wilczynski W (1986) Allometry of major CNS divisions: towards a reevaluation of somatic brain-body scaling. *Brain Behav Evol*, 28: 157–169.
18. Gapert R, Black S, Last J (2009) Sex determination from the foramen magnum: discriminant function analysis in an eighteenth and nineteenth century British sample. *Int J Legal Med*, 123: 25–33.

19. Giles E, Elliot O (1964) Sex determination by discriminant function analysis of crania. *Am J Phys Anthropol*, 22: 129–136.
20. Górski AZ, Skrzat J (2006) Error estimation of the fractal dimension measurements of cranial sutures. *J Anat*, 208: 353–359.
21. Gruber P, Henneberg M, Böni T, Rühli FJ (2009) Variability of human foramen magnum size. *Anat Rec*, 292: 1713–1719.
22. Günay Y, Altinkök M (2000) The value of the size of foramen magnum in sex determination. *J Clin Forensic Med*, 7: 147–149.
23. Hasue M, Kikuchi S, Sakuyama Y, Ito T (1983) Anatomic study of the interrelation between lumbosacral nerve roots and their surrounding tissues. *Spine*, 8: 55–58.
24. Henke W (1977) On the method of discriminant function analysis for sex determination of the skull. *J Hum Evol*, 65: 95–100.
25. Holland TD (1986) Sex determination of fragmentary crania by analysis of the cranial base. *Am J Phys Anthropol*, 70: 203–208.
26. Humphrey LT (1998) Growth patterns in the modern human skeleton. *Am J Phys Anthropol*, 105: 57–72.
27. Kaczkowski H, Porwollik K, Porwollik M, Noga L, Woyton H, Domagala Z, Gworys B. (2012) Anatomical analysis of preangular mandibular notch in humans. *Folia Morphol*, 71: 100–104.
28. Kajanoja O (1969) Sex determination of Finnish crania by discrimination function analysis. *Am J Anthropol*, 24: 29–34.
29. Kikuchi S, Hasue M, Nishiyama K, Ito T (1984) Anatomic and clinical studies of radicular symptoms. *Spine*, 9: 23–30.
30. Lang J (1991) *Clinical anatomy of the posterior cranial fossa and its foramina*. Thieme Medical Publishers, Berlin.
31. MacLarnon A (1996) The evolution of the spinal cord in primates: evidence from the foramen magnum and the vertebral canal. *J Hum Evol*, 30: 121–138.
32. Martin R, Saller K (1959) *Lehrbuch de Anthropologie*. Gustav Fischer, Stuttgart.
33. Milhorat TH, Nishikawa M, Kula RW, Dlugacz YD (2010) Mechanisms of cerebellar tonsil herniation in patients with Chiari malformations as guide to clinical management. *Acta Neurochir*, 152: 1117–1127.
34. Moss ML (1997) The functional matrix hypothesis revisited. I. The role of mechanotransduction. *Am J Orthod Dentofacial Orthop*, 112: 8–11.
35. Moss ML, Young R (1960) A functional approach to craniology. *Am J Phys Anthropol*, 18: 281–292.
36. Murshed KA, Cicekcibasi AE, Tuncer I (2003) Morphometric evaluation of the foramen magnum and variations in shape: a study on computerized tomographic images of normal adults. *Tur J Med Sci*, 33: 301–306.
37. Muthukumar N, Swaminathan R, Venkatesh G, Bhanumathy SP (2005) A morphometric analysis of the foramen magnum region as it relates to the transcondylar approach. *Acta Neurochir*, 147: 889–895.
38. Narkiewicz O, Dziwiątkowski J, Kowiański P, Wójcik S, Spodnik JH (2010) Head. In: Narkiewicz O, Moryś J eds. *Human anatomy*. PZWL, Warszawa, pp. 83–265.
39. Olivier G (1975) Biometry of the human occipital bone. *J Anat*, 120: 507–518.
40. Piontek J (1999) *Biology of prehistoric population*. Wydawnictwo Naukowe UAM, Poznan.
41. Reynolds KK, Modaff P, Pauli RM (2001) Absence of correlation between infantile hypotonia and foramen magnum size in achondroplasia. *Am J Med Genet*, 101: 40–45.
42. Richards GD, Jabbour RS (2011) Foramen magnum ontogeny in *Homo sapiens*: a functional matrix perspective. *Anat Rec*, 294: 199–216.
43. Röthig W (1971) Relationships between body height and diameter of the occipital foramen magnum in the adult. *Anthropol Anz*, 33: 48–51.
44. Routal RR, Pal GP, Bhagwat SS, Tamankar BP (1984) Metric studies with sexual dimorphism in foramen magnum of human crania. *J Anat Soc India* 33: 85–89.
45. Rude J, Mertzlufft FO (1987) Correlation coefficients in human skulls: significant sexual differences. *Anthropol Anz*, 45: 371–375.
46. Scheuer L, Black S (2000) *Developmental juvenile osteology*. Academic Press, London.
47. Sendemir E, Savci G, Cimen A (1994) Evaluation of the foramen magnum dimensions. *Kaibogaku Zasshi*, 69: 50–52.
48. Shirley NR, Jantz RL (2011) Spheno-occipital synchondrosis fusion in modern Americans. *J Forensic Sci*, 56: 580–185.
49. Skrzat J (2006) Modelling the calvarium diploe. *Folia Morphol*, 65: 132–135.
50. Skrzat J (2007) Fractal models of the cranial sutures silhouettes. *Episteme*, 5: 41–48.
51. Teixeira WR (1982) Sex identification utilizing the size of the foramen magnum. *Am J Forensic Med Pathol*, 3: 203–206.
52. Teul I, Czerwiński F, Gawlikowska A, Konstany-Kurkiewicz V, Sławiński G (2002) Asymmetry of the ovale and spinous foramina in mediaeval and contemporary skulls in radiological examinations. *Folia Morphol*, 61: 147–152.
53. Tillmann B, Lorenz R (1978) The stress at the human atlanto-occipital joint. *Anat Embryol*, 153: 269–277.
54. Tubbs RS, Griessenauer CJ, Loukas M, Shoja MM, Cohen-Gadol AA (2010) Morphometric analysis of the foramen magnum: an anatomic study. *Neurosurgery*, 66: 385–388.
55. Uysal S, Gokharman D, Kacar M, Tuncbilek I, Kosa U (2005) Estimation of sex by 3D CT measurements of the foramen magnum. *J Forensic Sci*, 50: 1310–1314.
56. Westcott D, Moore-Jansen P (2001) Metric variation in the human occipital bone: forensic anthropological application. *J Forensic Sci*, 5: 1159–1163.
57. Zaidi SH, Dayal SS (1988) Variations in the shape of foramen magnum in Indian skulls. *Anat Anz*, 167: 338–340.