

# Unusual presence of Wormian (sutural) bones in human skulls

A.A. Khan, M.A. Asari, A. Hassan

*Department of Anatomy, School of Medical Sciences, Universiti Sains Malaysia, Kelantan, Malaysia*

[Received 10 July 2011; Accepted 1 September 2011]

*Wormian bones are a subset of the small intrasutural bones that lie between the cranial sutures formed by the bones of the skull vault. They are formed due to additional ossification centres in or near sutures. They are usually considered as normal variants and seem to be determined genetically in certain populations. They have been linked with rapid cranial expansion as they appear in great number in hydrocephalic skulls. They are commonly found in the lambdoid suture and fontanelles but are occasionally seen in other sutures especially the coronal, squamosal, and sagittal sutures. We examined 25 dried human skulls with the aim to find out the occurrence and variations of Wormian bones, and surprisingly we found Wormian bones in the coronal, squamosal, and sagittal sutures in 6 skulls. These are uncommon sites of occurrence of sutural bones as reported in the literature. These findings prompted us to report these cases as their presence can lead to confusion in diagnosis in cases of skull fractures. (Folia Morphol 2011; 70, 4: 291–294)*

**Key words:** skull, Wormian bones, suture, coronal, sagittal, squamosal

## INTRODUCTION

Wormian or sutural bones are usually small irregular ossicles located within the cranial sutures. They are formed as a result of alterations in the normal formation of the flat bones of the skull and are usually regarded as normal variants. They are not named, because they vary in number and shape from skull to skull. They are studied and reported as ethnic variables, being of interest to human anatomy, physical anthropology, radiology, and forensic medicine [5]. Pathological, mechanical, and genetic factors have been proposed as the primary causal mechanism in the occurrence of Wormian bones (WB). According to some, WB may be the result of additional ossification centres in the fibrous tissue occurring during late foetal ages or postnatally and which remain separated from the primary centres of ossification of cranial bones. Very high frequen-

cies of WB in some populations and their absence in others, geographically nearby or subject to similar environmental stresses, suggest a genetic mechanism [7]. The reported incidence is variable, ranging from around 10% (in Caucasian skulls), through 40% (in Indian skulls), to 80% (in Chinese skulls). In general, males are more frequently affected than females [4]. They are most commonly found in the lambdoid suture. The next most common site is the epipterice bone (pterion ossicle) found near the former anterolateral fontanelle. Very rarely they are seen in other sutures especially the coronal, sagittal, and squamosal sutures. In order to contribute to the knowledge of the sutural bones and their occurrence we carried out this study. Knowledge of this variation is very important for anthropologists, radiologists, orthopaedic surgeons, and neurosurgeons.

## MATERIAL AND METHODS

The present study was carried out on 25 dried adult human skulls obtained from the Department of Anatomy, School of Medicine, Universiti Sains Malaysia. The various sutures were examined systematically for the presence or absence of WB. The findings were documented and the photographs of relevant WB were taken using a Sony digital camera.

## RESULTS

Out of the 25 skulls studied, 7 skulls were found to have WB, which were located in the coronal (2 cases), squamosal (2 cases), and sagittal sutures (2 cases). Coronal sutural bones were found in the left coronal suture 4 cm above the pterion in both of the specimens. In one skull (case 1; Fig. 1), the WB was roughly triangular in shape and its sutures were not well marked. In the other skull (case 2; Fig. 2) it was rounded and its sutures were well demarcated.

Squamosal sutural bone (Parietal notch bone) (Fig. 3) was found on the right side about 2 cm anterior to the asterion in one skull (case 3). It was well demarcated both externally and internally. In the same skull we also noticed 2 large interparietal bones and a WB in the occipitomastoid suture. In the other skull (case 4; Fig. 4) squamosal sutural bone was found on the left side about 3 cm from the asterion.

In the other two skulls (cases 5 and 6) WB were found in the sagittal suture along with a single *Os inca* bone at the lambda. Case 5 (Fig. 5) was noted to have 2 sutural bones which were 1 cm apart and the anteriorly placed bone was larger than the posterior one. It was also associated with sutural bones in the lambdoid suture. In case no 6 (Fig. 6) a single WB was noted in the sagittal suture just in front of the lambda along with an *Os inca* bone at the lambda.

## DISCUSSION

Wormian bones are a common occurrence in the human skull. They occur most frequently in the lambdoid suture. Bergman et al. [1] reported that nearly 40% of skulls have sutural bone in the lambdoid suture. The next most common site of WB is the pterion ossicle, which has a high incidence among Indians. A study by Saxena et al. [10] showed that 11.79% of Indian skulls and 5.06% Nigerians skulls had epip-teric bone. There can be another bone called the pre-interparietal bone or *inca* bone at the lambda.

It is still unclear why sutural bones are common in certain races. According some authors the occurrence

of WB is controlled by genetic factors [6]. Some other studies suggest that the presence of WB is associated with cranial and central nervous system abnormalities [3, 9]. Radiologist Dr. Frank Gaillard [4] and Dr. Amit Tripathi [12] have reported cases of WB associated with rickets, hypothyroidism, down syndrome, osteogenesis imperfecta, pycnodysostosis and cleidocranial dysplasia. Conversely, Jeanty et al. [8] have reported the presence of WB in four foetuses, but none of these cases were associated with any anomalies.

There have been very few studies reporting the occurrence of WB in the coronal, sagittal, and squamosal suture. In the present study, out of 25 skulls, we found 2 cases of WB in coronal sutures, 2 cases in squamosal sutures, and in the sagittal sutures in another 2 skulls. Berry and Berry [2], in their study on epigenetic variations in the human cranium, reported the presence of WB in the coronal and squamosal sutures. However, Tewari et al. [11] studied 1500 skulls for the presence of sutural bones, but they failed to find a single case of Wormian in the coronal, squamosal, and sagittal sutures.

Despite the rarity of their occurrence in the present study, WB were associated with some other interesting and even rarer variations. For example, one skull with WB in the squamosal suture was noted to have 2 large bilaterally symmetrical interparietal bones and an additional WB in the occipitomastoid suture. In the other two skulls, WB in the sagittal suture were associated with the presence of *os inca* bone. These variations are very rare and have not been reported in the earlier literature.


## CONCLUSIONS

The present study indicates that WB may be present in the coronal, squamosal, and sagittal sutures in addition to the usual site in the lambdoid suture. It is important for neurosurgeons and radiologists to be aware of the presence of WB in these sutures as they may be mistaken for fractures in cases of head injuries. Therefore, this report may be useful for neurosurgeons, radiologists, and anthropologists.

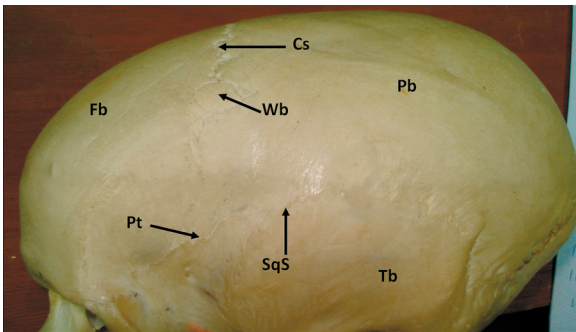
## ACKNOWLEDGEMENTS

I would like acknowledge and thank technologists Mr. Mohd Harissal Ismail and Mr. Mohd Aidi Azhari Mohamad for helping me in conducting this study.

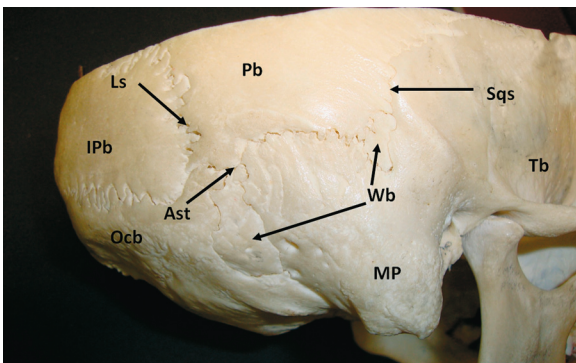
The study was carried out in the Department of Anatomy, PPSP, USM, Kempus Kesihatan, Kubang Kerian 16150, Kota Bharu, Kelantan, Malaysia in the year 2010.



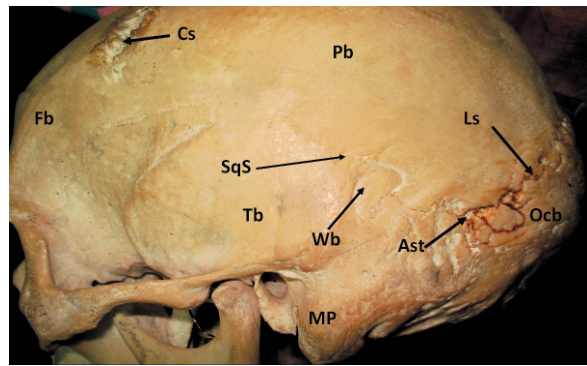
**Figure 1.** Left lateral view of the skull showing the Wormian bone in the coronal suture; Cs — coronal suture; Fb — frontal bone; Pb — parietal bone; Wb — Wormian bone; Ss — sagittal suture; Br — Bregma.



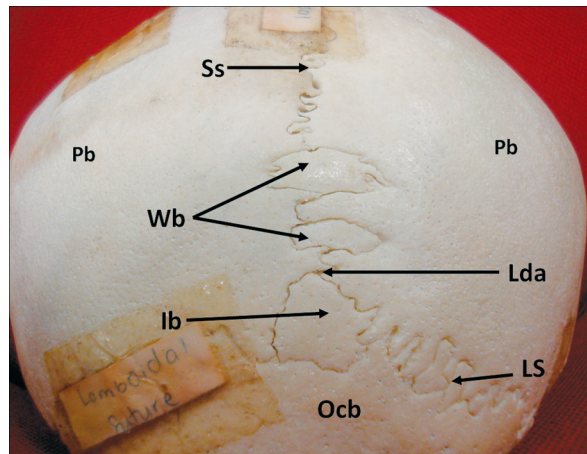
**Figure 2.** Left lateral view of the skull showing the Wormian bone in the coronal suture; Cs — coronal suture; Fb — frontal bone; Pb — parietal bone; Wb — Wormian bone; Pt — pterion; SqS — squamosal suture; Tb — temporal bone.



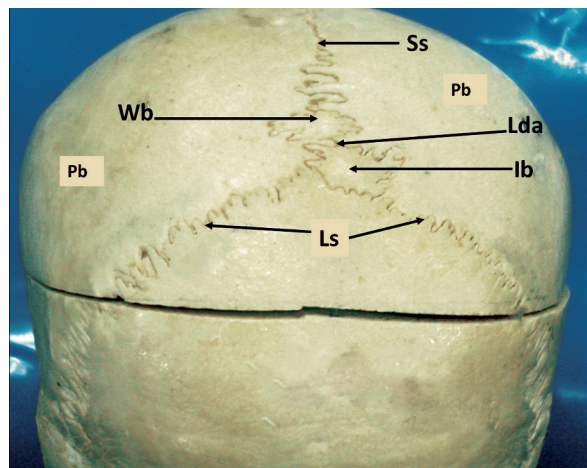
**Figure 3.** Right lateral view of the skull showing the Wormian bone in the right squamosal suture; SqS — squamosal suture; Tb — temporal bone; Pb — parietal bone; Wb — Wormian bone; Ls — lambdoid suture; IPb — interparietal bone; Ast — asterion; MP — mastoid process; Ocb — occipital bone.



**Figure 4.** Left lateral view of the skull showing the Wormian bone in the left squamosal suture; SqS — squamosal suture; Tb — temporal bone; Pb — parietal bone; Wb — Wormian bone; Ls — lambdoid suture; Ast — asterion; MP — mastoid process; Ocb — occipital bone; Fb — frontal bone; Cs — coronal suture.



**Figure 5.** Superior view of the skull cap showing the Wormian bones in the sagittal suture and os inca bone; Ss — sagittal suture; Wb — Wormian bone; Ls — lambdoid suture; lb — inca bone; Lda — lambda; Pb — parietal bone.



**Figure 6.** Superior view of the skull cap showing the Wormian bone in the sagittal suture and os inca bone; Ss — sagittal suture; Wb — Wormian bone; Ls — lambdoid suture; lb — inca bone; Lda — lambda; Pb — parietal bone.

## REFERENCES

1. Bergman RA, Afifi AK, Miyauchi R (1988) Skeletal systems: Cranium. In: Compendium of human anatomical variations. Urban and Schwarzenberg, Baltimore, pp. 197–205.
2. Berry CA, Berry RJ (1967) Epigenetic variation in the human cranium. *J Anat*, 101 (Pt 2): 361–379.
3. Das S, Suri R, Kapur V (2005) Anatomical observations on os inca and associated cranial deformities. *Folia Morphol*, 64: 118–121.
4. Gaillard F (2008) Case no. 5280, <http://Radipaedia.org/> /30 December.
5. Garcia-Hernandez F, Diaz Blanco JL, Echeverria G, Murphy T (2007) Incidence of sutural bones in a population of monkey's skulls of Northern Chile, Antofagasta. *Intern J Morphol*, 25: 801–804.
6. El-Najjar M, Dawson GL (1977) The effect of artificial cranial deformation on the incidence of Wormian bones in the lambdoidal suture. *Am J Phys Anthropol*, 46: 155–160.
7. Finkel DJ (1976) Wormian bone formation in the skeletal population from Lachish. *J Hum Evolut*, 5: 291–295.
8. Jeanty P, Silva SR, Turner C (2000) Prenatal diagnosis of Wormian bones. *J Ultrasound Med*, 19: 863–869.
9. Pryles CV, Khan AJ (1979) Wormian bones. A marker of CNS abnormality? *Am J Dis Child*, 133: 380–382.
10. Saxena SK, Jain SP, Chowdhary DS (1988) A comparative study of pterion formation and its variations in the skulls of Nigerians and Indians. *Anthropol Anz*, 46: 75–82.
11. Tewari PS, Malhotra VK, Agarwal SK, Tewari SP (1982) Preinterparietal bone in man. *Anat Anz*, 152: 337–339.
12. Tripathi A (2011) Case no. 13352, <http://Radipaedia.org/> /1 April.