

The anatomopathology of bicuspid aortic valve

S.-M. Yuan

Department of Cardiothoracic Surgery, Affiliated Hospital of Taishan Medical College, Taian, Shandong Province, People's Republic of China

[Received 7 July 2011; Accepted 16 August 2011]

The bicuspid aortic valve is a common congenital heart disease characterised by inequality of cusp size, a central raphe, and smooth cusp margins even in diseased valves. It may progress and become calcified, leading to varying degrees of aortic valve disorders, such as stenosis, regurgitation, or combined, which may eventually necessitate surgical intervention. The bicuspid aortic valve is not a disorder confined to the aortic valve, but a spectrum involving the aortic valve, aortic annulus, aortic root, ascending aorta, and the left ventricular outflow tract. Different types of bicuspid aortic valves may present with distinct aetiologies and morphologies. The anatomopathological features of the bicuspid aortic valve have not been sufficiently elucidated. Differences in the anatomy of the bicuspid aortic valve could reflect different pathogeneses and different needs for different therapeutic approaches. Debates still remain in terms of timing of surgery and surgical indications of this disorder. The aim of the present article is to make a review of the anatomy and the management strategies of the bicuspid aortic valve in order to draw inferences about the clinical implications. (Folia Morphol 2011; 70, 4: 217–227)

Key words: aortic valve, heart valve diseases, pathology, surgical

INTRODUCTION

The bicuspid aortic valve (BAV) is a common congenital heart disease characterised by inequality of cusp sizes, a central raphe, and smooth cusp margins even in diseased valves [96]. Most patients with a BAV are unaware of the diagnosis until they become symptomatic or the onset of infective endocarditis, or when they are subject to an incidental echocardiographic examination [4]. BAV is often associated with aortic dilation, aneurysms, and dissection, which can be the main problems of BAV. However, the pathogenesis is still unknown. Moreover, the implications of the anatomopathology of BAV in the development of the aortic disorders that constitute a special entity along with BAV have not been elucidated. The present article aims to present some evidences of the anatomopathological aspects of BAV.

ANATOMOPATHOLOGY

Epidemiology

BAV represented 6–22% of the patients for native aortic valve surgery [66, 95]. Sabet et al. [75] reported a large patient population with diseased BAV, aging from 1 to 86 years with a mean age of 61 years, showing a strong male predominance. Similarly, Yotsumoto et al. [102] reported a group of 63 BAV patients with a mean age of 53 years ranging from 14 to 76 years. It has been reported that BAV patients with aortic regurgitation were significantly younger than those with aortic stenosis (45 ± 13 vs 60 ± 11 years, $p < 0.01$). Ichihara et al. [39] and Koide et al. [50] observed the same results with respect to patients' age with stenotic or regurgitant BAVs. Aortic regurgitation in BAV showed stronger male gender predominance than aortic stenosis [39].

When comparing to the patients with tricuspid aortic valve disorder, stenotic BAV patients were 7.1 years older, and the regurgitant BAV patients were 6.3 years younger at the time of aortic valve replacement [50]. The prevalence of BAV in patients with Marfan syndrome was 4.5%; the concurrence of both conditions would lead to more aggressive aortic disorder at an earlier stage [2].

Classifications

In 1983, Brandenburg et al. [12] suggested, on the basis of two-dimensional echocardiography, a classification system of BAV according to the fused leaflet and the position of the raphe, which has now been popularly accepted in clinical practice: type 1, fusion of right and left coronary cusp (R-L); type 2, right and non-coronary fusion (R-N); and type 3, left and non-coronary fusion (L-N) (Fig. 1). Clinical observations revealed that type 1 was the most frequent BAV, accounting for 70–79.6% of cases [34, 78], followed by type 2, at 20.4%, and type 3 was the least with only 0.5%. Subsequently, several new classification schemes were readily suggested in order to involve more information of the status of BAVs.

Sadee et al. [76] divided BAVs into 3 types: valves that were purely bicuspid (23%), bicuspid valves with a raphe (34%), and valves with an additional indentation of the free edge of the conjoined cusp (43%). Tokunaga et al. [92] categorised BAV into four types: Type I (44.7%) in which 2 cusps are situated right and left, a coronary artery arises from each related sinus of Valsalva; Type II (22.4%) which is Type I + raphe in the right cusp; Type III (3.5%) which has one anterior cusp and one posterior cusp with both coronary arteries arising from the anterior cusp; and Type IV (29.4%) which is Type III + raphe in the anterior cusp. Regarding preoperative diagnosis, aortic stenosis dominated in Type I (78.8%) and aortic regurgitation dominated in Type IV (72.0%). Implanted valve sizes were 22.2 ± 1.8 (Type I), 23.4 ± 1.6 (Type II), and 24.0 ± 2.2 mm (Type IV), and a significant difference was noted between Type I and Type II, as well as between Type I and Type IV. Recently, a new classification was proposed by Sievers and Schmidtke [82] on the basis of number of raphae, spatial position of cusps or raphae, and functional status of the valve. Three major types were identified according to the number of raphae: type 0 (no raphe), type 1 (one raphe), and type 2 (two raphae) (Fig. 2), followed by two supplementary characteristics: spatial position and function. Similar BAV phenotypes were defined by the presence and orientation of cusps and

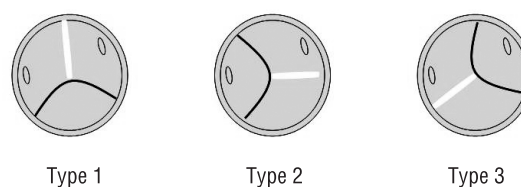


Figure 1. Brandenburg classification of bicuspid aortic valve.

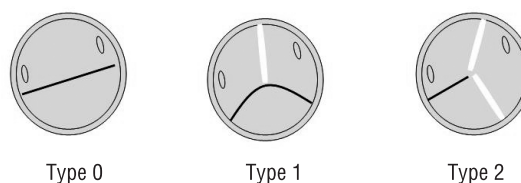


Figure 2. Sievers and Schmidtke classification of bicuspid aortic valve.

raphae in cardiovascular magnetic resonance (CMR) as: (1) Two well-developed cusps and commissures without a raphe; (2) A malformed commissure, and a raphe extending from the commissure to the free edge of the two underdeveloped conjoint cusps [15]. Moreover, Sonoda et al. [85] divided BAVs into anteroposteriorly (A-P) located, and right-left (R-L) located BAVs.

In humans, most BAVs result from fusion of either the right-coronary and left-coronary leaflets (R-L) or the right-coronary and non-coronary leaflet (R-N). R-N BAV can be associated with a greater degree of valve dysfunction [33, 74, 77]. Compared to the R-N type, the R-L type BAV was associated a more diseased aortic wall, at younger age, and with a larger aortic root. Cystic medial necrosis of the ascending aortic wall was particularly prevalent in patients with BAV of an R-L type [16].

Studies in animal models have suggested distinct aetiologies regarding different subtypes: R-N BAVs result from defective development of the cardiac endocardial cushions, whereas R-L BAVs result from an extra fusion of the septal and parietal ridges [35]. BAVs in *Gata5*^{-/-} mice were the result of a fusion between the posterior intercalated cushion and the septal ridge, resulting in an R-N subtype [54]. Clinical observations revealed that patients with R-L BAV had larger aortic annulus and ascending root dimensions compared to those with R-N BAV [45]. The R-N BAVs have been suggested as a morphogenetic defect formed before the cardiac outflow tract septa-

tion and probably an exacerbated nitric oxide-dependent epithelial-to-mesenchymal transformation product. The R-L BAVs may result from the anomalous septation of the proximal portion of the cardiac outflow tract caused by distorted behaviour of neural crest cells. Discrepancies between the R-N and R-L BAVs may rely on the relationship between the BAV morphologic phenotypes and other heart diseases [35]. Interestingly, differences in aortic elasticity among different BAV phenotypes have been noted. Patients with an R-N type BAV had increased aortic stiffness at the sinuses of Valsalva compared with the R-L type BAV, but no difference was found in stiffness between the ascending aorta and aortic arch [79].

Aortic stenosis and regurgitation

BAV is the cause of aortic stenosis in 70–85% of paediatric patients and about 50% of adult patients. Indications for aortic valve replacement in BAV patients are the same as rheumatic or senile degenerative aortic valve disorders; however, BAVs often extend the lesions from the valve leaflets to the left ventricular outflow tract and even the ascending aorta. Furthermore, BAVs are usually associated with several congenital anomalies, infective endocarditis, and acute aortic aneurysm or dissection [14]. Aortic stenosis may become the cause of the primary cardiac events in children with BAV; however, it is usually amenable to balloon dilation [56].

Nistri et al. [63] demonstrated that the ascending aortas of BAV patients with aortic regurgitation were less stiff and more distensible compared to those of individuals with normally functioning BAVs. A BAV may progress and become calcified, leading to varying degrees of severity of aortic stenosis and aortic regurgitation, which may eventually necessitate surgical intervention [11]. There have been diverse proportions of valvular abnormalities and normally functioning valves among patient populations of BAV from different centres. In 280 adult patients with isolated BAV, echocardiography analysis showed that BAVs were normally functioning in 39%, stenotic in 33%, and regurgitant in 27% [27]. Sabet et al. [75] reported 75% of the diseased BAVs were purely stenotic, 13% purely regurgitant, 10% combined stenotic and regurgitant, and 1% normally functioning. Luciani et al. [55] described 11% of BAVs as being stenotic; 65% as regurgitant, and 24% as mixed lesions.

Moderate or severe aortic stenosis was most common, and moderate or severe aortic regurgi-

tation was more frequently observed in patients with type 2 BAV. Most aortic coarctation patients (89%) had type 1 BAVs, with lesser degrees of valve stenosis or regurgitation [78]. Aortic regurgitation was more severe in A-P type than in R-L type BAVs, while aortic stenosis was more severe in the R-L type than in the A-P type. The area eccentricity index (the ratio of the larger aortic cusp area to the smaller aortic cusp area) was larger in raphe type than in non-raphe type (1.83 ± 0.53 vs 1.51 ± 0.47 , $p < 0.05$) [85].

The raphe

A raphe is a typical sign of diagnosing a BAV [100]. It may appear in 50–76% of patients, with 67% typical and 9% atypical [53, 73, 75]. When the cusps were R-L located, the false commissures were always in the right cusp; when the cusps were A-P located, the raphe was always in the anterior cusp [73]. Raphe position was between the right and left cusps in 86% and raphe absence occurred more often in valves with equal-sized cusps than unequal [75]. Kuboki [53] noted that the raphe was more frequently seen in BAVs with mixed aortic stenosis and regurgitation and those without aortic stenosis or regurgitation than in those with pure aortic stenosis, and all cases had raphae in BAVs without aortic stenosis or regurgitation. Yotsumoto et al. [102] noted that 55% of BAVs with a raphe had aortic regurgitation, and 76% of BAVs without a raphe had aortic stenosis. Patients with a BAV with a raphe were significantly younger than those without a raphe at the time of surgery (50 ± 15 vs 57 ± 11 years, $p = 0.02$). A study on cusp weight showed that the raphe and non-raphe cusps differed in weight in 74% of patients, with the raphe cusps being larger in 74% of patients, and similar weights were noted in 26% of patients. Of the patients with raphae in neither cusp, 82% of cusps differed in weight and 18% had similar weights [73].

Diverse hypothesis existed in the pathological changes of the raphe of BAVs. In the raphe group, infective endocarditis, prolapse of the aortic valve, and cusp thickening with contraction were the causes of aortic regurgitation. In the non-raphe group, infective endocarditis, and cusp contraction in younger patients, were the causes of aortic regurgitation. The reduced tendency towards calcium deposition in raphed BAV can be an important factor leading to pure aortic regurgitation [100]. However, some authors suggested that the raphe should be the main location of calcification because spiralled collagen fibrils were observed [91].

The annulus

Observations of the aortic annulus in BAV patients generated different results. Ichihara et al. [39] reported that the annular diameter measured during surgery was significantly narrower in the BAV patients compared to patients with a tricuspid aortic valve undergoing aortic valve replacement during the same period. Annular dilation was associated with aortic regurgitation to a greater degree than aortic stenosis (48% vs 11%, $p < 0.001$). Osaka et al. [66] did not find any significant difference in the aortic annular size between BAV and non-BAV patients by preoperative echocardiography (22.8 ± 2.0 vs 22.5 ± 2.2 mm in aortic stenosis, and 25.4 ± 2.4 vs 23.4 ± 2.5 mm in aortic regurgitation). In comparison to the stenotic tricuspid aortic valve, a stenotic BAV often had a smaller diameter of preoperative valve orifice (6.9 vs 9.2 mm, $p < 0.05$), and a smaller valve ring diameter (23.0 vs 24.3 mm, $p < 0.05$), but the valve prostheses used for the patients in the operations had almost identical sizes of 22 mm [50]. A supra-annular type prosthetic valve was more frequently inserted in BAV than in tricuspid aortic valve patients because the BAV annulus can cause difficulty in prosthetic insertion [69]. However, of the BAVs, the aortic annulus diameter was often larger in the A-P type than in the R-L type (15 ± 3 vs 13 ± 2 mm/body surface area, $p < 0.05$) [85]. A few patients with a regurgitant BAV had annuloaortic ectasia, which was suspected as an underlying cause of solitary aortic regurgitation [3].

Cusp calcification

BAV calcification was the most common cause of pure aortic stenosis, representing 38% of valve replacements, followed by degenerative calcification of tricuspid aortic valves (33%), and postinflammatory (presumably rheumatic) calcification and fibrosis (24%) [68]. Moderate to severe calcification affected valves with aortic stenosis more frequently than aortic regurgitation [75]. The calcification can be seen in 3 different locations: cusp bases (base type), free edges (edge type), and both bases and edges (mixed type). Among 10 patients with a stenotic BAV, 10% had a base type and 90% had a mixed type calcification, while 23.1% had an edge type and 76.9% had a mixed type in patients with rheumatic aortic stenosis [99]. The cusps of BAVs were the most severely thickened compared to senile and rheumatic aortic stenosis. Among 324 patients younger than 70 years of age, calcified BAVs

were observed in 50%. In contrast, among those aged 70 years or older, degenerative calcification accounted for 48% of the stenotic aortic valves [68]. By echocardiography, aortic valve sclerosis began from the second decade, and the sclerotic index progressed with age, while aortic valve calcium was noted from the fourth decade [8].

Calcification was severe in patients with a stenotic BAV or a stenotic predominance of mixed valve stenosis and regurgitation; however, calcification was limited in cases with regurgitant dominance in a mixed valve disorder. Therefore, BAV did not necessarily become stenotic, and this has been confirmed by the normally-functioning cases with no stenosis or regurgitation. Cases without a raphe were prone to be markedly calcified and stenotic, and cases with a raphe were not [53]. In the patients with pure aortic stenosis, calcified BAVs accounted for 46%, and accounted for 19% for combined aortic stenosis and insufficiency [86]. Calcification in BAV was more frequently found in the A-P cusps than in the R-L cusps, suggesting that calcification may result in aortic stenosis [64].

The distribution of calcium was more diffuse throughout the body of calcified BAVs; while calcific deposits of calcified tricuspid aortic leaflets are typically superimposed in nodular form. That is why BAVs can hardly be amenable to operative or percutaneous valvuloplasty [42]. Pathological findings of the pure regurgitant valves revealed neither calcium deposit nor findings of infection, but commonly showed myxoid degeneration [3]. Histological study of the excised valves disclosed severe myxoid degeneration in 16 of 27 patients with aortic regurgitation [102]. In stenotic BAVs, the pathological findings of the resected valve included irregular fibrotic thickening and marked calcification without any vegetation or thrombus formation [101]. Grossly, the cusps were thickened, rolled, and redundant; microscopically, they consisted of immature loose connective tissue consistent with a dysplastic or incompletely differentiated valve [19]. In rheumatic aortic valve disorder, microfibril-like fibrillar structures were found in the areas of deposition of electron-dense materials, suggesting degradation and necrosis of newly formed connective tissue because of nutritional deprivation, especially in the thickened central area, leading to calcium deposition. In contrast, in degenerative and BAV, numerous lipid vacuoles were found in the electron-dense deposition areas similar to lipid deposition in aortic atherosclerosis. The

increase of the haemodynamic load with abnormal structure in BAVs may be prone to the sclerotic changes with the degeneration of collagen fibres, providing a core for calcification [91].

Aortic valve pressure gradient increased approximately 18 mm Hg each decade, concomitant with progression of valve sclerosis. Progression of cusp sclerosis was faster in patients with A-P located cusps than in those with R-L located cusps, and was faster in those with eccentric cusps than in those with symmetric cusps. In patients with eccentric and A-P located cusps, aortic valve pressure gradient increased 27 mm Hg per decade [8].

Fibrous bands

The fibrous band was present in 6% of BAVs, where the raphe was fenestrated with only a thin fibrous band (or bands) joining the valve cusp to the aortic wall (type A); or a similar fibrous band (or bands) associated with other usually appearing raphal tissue (type B) [102]. An observation of BAV leaflets revealed neither calcium deposit nor infection but did show collagenous fibrous tissue with focal mucinous degeneration [3]. The majority of BAVs with an abnormal fibrous band stretched from the centre of the conjoined cusp to the aortic wall were found in the patients with aortic regurgitation. But in extreme cases, it was associated with aortic stenosis [61]. A degenerative change alone was evidenced by histology in the resected fibrous band, which was supposed to be an embryogenic remnant of the aortic valve [59].

Aortic root

Aortic stenosis and aortic regurgitation were equally common in tricuspid aortic valve and BAV with normal aortic dimensions, while aortic regurgitation was predominant in tricuspid aortic valve with dilated aortas, and aortic stenosis was predominant in BAV with dilated aortas. Aortic dilation was evenly distributed in BAV regardless of leaflet morphology [43]. Not all patients with BAV, but the patients with an elevated 10-year risk of > 7%, tobacco use, and higher random blood glucose level, demonstrated progressive aortic dilation [41]. Aortic root dilation has been documented in childhood, suggesting that this process begins early in life [84]. Although mild ascending aortic dilation was common in children, the clinical course was relatively benign [56].

In the worst case of BAV, this aortopathy can result in rupture or dissection [83]. Aortic dissection can occur at dimensions < 5 cm in both BAV

patients and the general population [67]. But the mean diameter of the ascending aorta progressing to dissection in the setting of BAV was 6 cm [89]. Some have advocated earlier repair of ascending aorta at 5 cm [87]. Root replacement is commonly recommended for Marfan syndrome when the aorta is ≤ 4.5 cm [48]. If the cause is related to pathological valvular haemodynamics, the correction of the valvular disease would theoretically also ameliorate the aortopathy, rendering aortic replacement less necessary. If the cause is related to genes, the replacement of the dilated aorta will be performed more liberally to stop the haemodynamically independent process of dilation and, thus, to reduce the risk for rupture or dissection [83].

AETIOLOGY

A haemodynamic origin of the BAV phenotypes was advocated [37]. BAVs have currently been evidenced to be heritable, and BAV can be malformed in the condition of defective valvulogenesis [22]. Patients with BAV have thinner elastic lamellae of the aortic media and greater distances between elastic lamellae than patients with tricuspid aortic valves [44]. Echocardiographic studies showed that BAVs had significantly lower aortic distensibility and greater aortic stiffness index in comparison with the controls [9]. Histologically, the ascending aorta can present cystic medial necrosis and elastic fragmentation, similar to Marfan syndrome [26]. In aneurysm tissue from patients with BAV, Nataatmadja et al. [62] discovered intracellular accumulation and reduction of extracellular distribution of fibrillin, fibronectin, and tenascin to a similar degree as that found in patients with Marfan syndrome. Nistri et al. [63] performed a similar study and found that 42% of the BAV patients had impaired aortic elasticity. Dysregulation of fibrillin-1 during valvulogenesis may lead to poor development of the aortic cusps, resulting in a BAV and a weakened aortic root [32]. Reduced fibrillin-1 content in both ascending aorta and pulmonary trunk are possible causes of the weakness of the aortic wall [26]. Type I and III collagens were significantly decreased in the dilated aortas in the BAV patients compared to the controls [21]. The endothelial nitric oxide synthase expression of aortic endothelial cells was significantly lower in patients with a BAV as compared to tricuspid aortic valves ($4,615 \pm 489$ vs $6,275 \pm 442$, $p = 0.017$) [1]. In BAVs, there was a significant correlation between endothelial nitric oxide synthase

expression and maximal aortic diameter or sinotubular diameter, whereas in patients with tricuspid aortic valves no significant correlation between aortic size and endothelial nitric oxide synthase expression was found [1].

The initial stages of valve formation involve multiple signalling molecules including members of the TGF- β , Ras, Wnt/ β -catenin, vascular endothelial growth factor, and NOTCH signalling families [57]. By mouse genetics, determination of the function of Gata5 in mammalian embryogenesis was made, and it was shown that deletion of Gata5 may result in BAV formation [54]. The Lrp5/Wnt/ β -catenin pathway plays an important role in the development of vascular and valvular calcification [18]. The Wnt/Lrp5/frizzled complex turns on downstream components such as dishevelled Dvl/Dsh, which leads to repression of the glycogen synthase kinase-3 (GSK3) [38]. BAV covers a spectrum of diseases from early atherosclerotic changes in the valve leaflets; aortic sclerosis, which is characterised by early calcification and thickening; and, finally, to outflow obstruction and severe aortic stenosis [72].

Alpha₁-antitrypsin may play an important role in maintaining the integrity of connective tissue, including the blood vessel wall. Aneurysmal pathogenesis appears to be complex, and several investigators have tried to find a connection between α_1 -antitrypsin deficiency and formation of abdominal aortic aneurysms. Kilickesmez et al. [47] noted that the plasma α_1 -antitrypsin concentration was negatively correlated with dilation of the ascending aorta in patients with BAV, indicating that the serum α_1 -antitrypsin concentration remains a possible biomarker of aortic aneurysm growth.

BAV aneurysms have increased apoptosis, greater degrees of elastic fragmentation, and alterations in tissue concentrations of matrix metalloproteinase (MMP) and endogenous inhibitors [40]. Elevation in MMP-2 expression was found in BAV aortic aneurysms, while the level of MMP-9 activity was normal [13]. MMP-2/TIMP-1 in ascending aorta was greater in BAV and aortic dilation patients [98]. Immunohistochemical studies demonstrated evidence of intracellular accumulation of fibrillin, fibronectin, and tenascin, increased expression of increased levels of MMP-2, and in vitro evidence of increased smooth muscle cell apoptosis among BAV-associated aneurysms [62].

DIAGNOSIS

Two-dimensional echocardiography may provide accurate configuration of a BAV, and has been

taken as a golden standard for the diagnosis of BAV as well as severity of the morphology of the aortic valve and the ascending aorta. The short-axis view is used to examine commissures, leaflet morphology, mobility, and the presence or absence of a low raphe. Therefore, the diagnosis of a BAV is based on the clear demonstration of two cups and two commissures in systole and diastole in the short-axis view. However, the short-axis view in some cases may present as almost normal because of a fused raphe in the middle of one of the two leaflets. Moreover, BAV may show a doming configuration in the long-axis view during systole [71]. However, a false positive diagnosis may result from an unclear follow-up [36]. The sensitivity, specificity, positive predictive value, and negative predictive value for the detection of a BAV were 76.5%, 60.6%, 68.4%, and 95.2%, respectively, for echocardiography and 94.1%, 100%, 100%, and 97.1%, respectively, for computed tomography. The computed tomographic findings were not significantly different from the intraoperative findings, but the echocardiographic findings were [90]. Both cardiac computed tomography and MRI now offer a valuable adjunct for accurate diagnosis of BAV. The absence of three cusps forming a "Y" configuration of the tricuspid aortic valve is suggestive of the diagnosis of a BAV [81]. Multi-detector computed tomographic (MDCT) features of uneven cusp size, round-shaped opening, midline calcification, longer leaflet fusion, and larger diameter of the ascending aorta can be helpful in distinguishing BAVs from tricuspid aortic valves [46].

TREATMENT AND PROGNOSIS

Beta-blockers may improve the haemodynamics of the patients in a state of heart failure. The use of β -blockers in BAV patients may retard aortic root dilation and prevent aortic valve regurgitation, and may be reasonable in those with aortic root dilation to retard further progression and also reduce the risk of aortic dissection [28]. Aortic valve infective endocarditis complicated by valvular dysfunction may indicate the need for a combination of aggressive antimicrobial therapy and early surgery [52].

The current surgical strategies including ACC/AHA support more aggressive treatment of BAV-related aortic dilation at smaller aortic size [20]. Valve-sparing aortic root replacement provides durable results in tricuspid and bicuspid valve anatomies. Symmetric tricuspidisation of the valve was thus achieved [51].

Table 1. The surgical strategies for bicuspid aortic valve and the clinical outcomes [6, 7, 17, 29, 58, 65, 70, 97]

Surgical strategy	Clinical outcome
Aortic root replacement: <ul style="list-style-type: none"> Modified Bentall–DeBono approach with reimplantation of the coronary arteries Ross operation Isolated ascending aorta replacement 	Excellent long-term results
Aortic root remodelling: <ul style="list-style-type: none"> Reduction aortoplasty Patch augmentation of the incompetent bicuspid aortic valve Modified David type repair 	No re-operations, progression of aortic root dilation or recurrent regurgitation occurred. Excellent mid-term results at a mean follow-up of 5.1 years
Aortic valve replacement: <ul style="list-style-type: none"> Reimplantation of the aortic valve Transcatheter aortic valve implantation 	Good results in selected patients who were not indicated for routine aortic valve replacement
Aortic valve repair: <ul style="list-style-type: none"> Free edge plication Subcommissural annuloplasty (obtain a good coaptation of the aortic valve leaflets) Mid-leaflet plication of the prolapsing leaflet Triangular resection of the prolapsing leaflet Triangular resection of a median raphe Tricuspidisation cusp extension 	Freedom from reoperation was 95, 87, and 84% at 1, 5, and 7 years, respectively

The timing of surgery and procedures continues to be debated, with some authors advocating surgery at an aortic size > 5.5 cm and others suggesting surgery at < 4.5 cm. A regurgitant BAV should be repaired, and the aorta should be replaced when the ascending aorta is significantly dilated at > 4.5 cm or aortic cross-sectional area/height ratio > 10 cm²/m [88]. Dayan et al. [24] suggest that aortic valve replacement prevents aortic root dilation in BAV patients whose aortic root diameter at the time of surgery was ≤ 4.5 cm. Boodhwani et al. [10] reported that all their BAV patients underwent supracoronary ascending aortic replacement and sinotubular junction remodelling with a Dacron prosthesis. If the raphe was fibrous, without significant calcification, it was simply shaved and the leaflet was left intact. If the raphe was calcified or severely restrictive, it was resected. Wald et al. [94] proposed that aorta replacement should be considered when aortic dilation with a size of (1) > 4.0 cm in patients with concomitant aortic valve replacement or other heart operations; (2) > 4.5 cm with rapid dilation of 0.5 cm/year, or aortic coarctation, first-degree relatives with acute aortic dissection/rupture, chronic obstructive pulmonary disorder, or hypertension; or (3) > 5.0 cm.

Several possible surgical options exist for dilation of the proximal thoracic aorta in BAV patients without significant valve dysfunction (Table 1). However, because of the intrinsic weakness of the aortic wall, there is a significant risk for recurrent dilation [30, 60]. Ring dilation may be present in the majority of regurgitant BAVs, and may be independent or in combination with aortic root dilation. If root dilation was present, an annular reinforcement was performed using aortic valve reimplantation technique. After resection of the aortic sinuses, the aortic valve annulus and subcommissural triangles of the non-coronary cusp were implanted inside a vascular graft [23]. Overall survival was not statistically significantly different between the groups, 80 ± 18% in the BAV group, and 94 ± 3.2% in tricuspid aortic valve patients [5]. Schäfers et al. [80] recommended a root diameter of > 4–4.5 cm, depending on the body surface area of the patient, as a cutoff in favour of root replacement. They found that freedom from reoperation at 5 and 10 years was 95%; and freedom from valve replacement was 97%, and suggested that valve preservation for the combination of regurgitant BAV and root dilation were similar to composite replacement.

BAV morphology is of prognostic importance. The raphe of a BAV and less tendency to deposit calcium are important causes of pure aortic regurgitation. Aortic regurgitation was more severe in the A-P type than in the R-L type BAVs, while aortic stenosis was more severe in the R-L type than in the A-P type. Annular dilation was associated with aortic regurgitation more than aortic stenosis. Supra-annular type prosthetic valve was more frequently inserted in BAV than in non-BAV. The more diffuse distribution of calcium in BAVs may preclude it from percutaneous valvuloplasty. Valve repair by coapting sutures alone or in combination with triangular resection of a median raphe with aortic root remodelling and the ascending aorta and proximal arch replacement can obtain promising outcomes. Coaption line of the tricuspid aortic valve and a prominent raphe giving an appearance of an additional coaption line may lead to a false negative result [25].

In patients with a regurgitant BAV and dilation of the proximal aorta > 5 cm, valve repair of BAVs by using coapting sutures alone or in combination with triangular resection of a median raphe, along with aortic root remodelling and ascending aorta and proximal arch replacement, provided promising outcomes [58]. Tricuspidisation cusp extension and the Ross procedure were indicated for paediatrics [58, 70]. During aortic valve repair for ascending aortic aneurysms, preserving functionally normal BAVs may bring about a low perioperative risk with encouraging early results [93]. Zalaquett et al. [103] reported a triangular resection of the prolapsing larger cusp including the median raphe performed in 17 cases, 13 of which had a regurgitant BAV undergoing a complementary subcommissural annuloplasty. There were no deaths during the follow-up period. Reoperation-free rates were 93% ± 6.4% at 1 year and 85% ± 9.5% at 5 years. Kin et al. [49] obtained similar results in BAV patients with aortic regurgitation for aortic valve repair. The 5-year survival rate was 90 ± 7%. The 1- and 5-year reoperation-free rates were 87 ± 12% and 76 ± 23%, respectively. But patients with a BAV and a history of aortic insufficiency may develop moderate autograft dysfunction after the Ross procedure during long-term follow-up [31].

In conclusion, BAV is the most common congenital heart disease, which is not a disorder confined to the aortic valve, but a spectrum involving the aortic valve, aortic annulus, aortic root, ascending

aorta, and the left ventricular outflow tract. The different types of BAVs may present with distinct aetiologies and morphologies. Apart from β -blockers and antibacterial therapies, aggressive surgical interventions including aortic root and aortic valve repair or replacement may bring about excellent clinical outcomes. The anatomopathological features of BAV may have important implications in decision-making regarding the surgical treatment of this aortic disorder entity.

REFERENCES

1. Aicher D, Urbich C, Zeiher A, Dimmeler S, Schäfers HJ (2007) Endothelial nitric oxide synthase in bicuspid aortic valve disease. *Ann Thorac Surg*, 83: 1290–1294.
2. Amezcua-Guerra L, Santiago C, Espinola-Zavaleta N, Pineda C (2010) Bicuspid aortic valve: a synergistic factor for aortic dilation and dissection in Marfan syndrome? *Rev Invest Clin*, 62: 39–43.
3. Arikawa K, Morishita Y, Watanabe K, Taira A (1990) Pure aortic regurgitation due to congenital bicuspid valve: a case report. *Kyobu Geka*, 43: 80–82.
4. Bacchion F, Cukon S, Rizzoli G, Gerosa G, Daliendo L, Thiene G, Basso C (2007) Infective endocarditis in bicuspid aortic valve: atrioventricular block as sign of perivalvular abscess. *Cardiovasc Pathol*, 16: 252–255.
5. Badiu CC, Bleiziffer S, Eichinger WB, Zaimova I, Hutter A, Mazzitelli D, Voss B, Lange R (2011) Are bicuspid aortic valves a limitation for aortic valve repair? *Eur J Cardiothorac Surg*, 40: 1097–1104.
6. Badiu CC, Eichinger W, Bleiziffer S, Hermes G, Hettich I, Krane M, Bauernschmitt R, Lange R (2010) Should root replacement with aortic valve-sparing be offered to patients with bicuspid valves or severe aortic regurgitation? *Eur J Cardiothorac Surg*, 38: 515–522.
7. Bajona P, Feindel CM (2010) Bicuspid-aortic valve surgery: repair or replace? *Curr Opin Cardiol*, 25: 119–123.
8. Beppu S, Suzuki S, Matsuda H, Ohmori F, Nagata S, Miyatake K (1993) Rapidity of progression of aortic stenosis in patients with congenital bicuspid aortic valves. *Am J Cardiol*, 71: 322–327.
9. Biner S, Rafique AM, Ray I, Cuk O, Siegel RJ, Tolstrup K (2009) Aortopathy is prevalent in relatives of bicuspid aortic valve patients. *J Am Coll Cardiol*, 53: 2288–2295.
10. Boodhwani M, de Kerchove L, Glineur D, Rubay J, Vanoverschelde JL, Van Dyck M, Noirhomme P, El Khoury G (2011) Aortic valve repair with ascending aortic aneurysms: associated lesions and adjunctive techniques. *Eur J Cardiothorac Surg*, 40: 424–428.
11. Borger MA, David TE (2005) Management of the valve and ascending aorta in adults with bicuspid aortic valve disease. *Semin Thorac Cardiovasc Surg*, 17: 143–147.
12. Brandenburg RO Jr, Tajik AJ, Edwards WD, Reeder GS, Shub C, Seward JB (1983) Accuracy of 2-dimensional echocardiographic diagnosis of congenitally bicuspid aortic valve: echocardiographic-anatomic correlation in 115 patients. *Am J Cardiol*, 51: 1469–1473.
13. Braverman AC (2011) Aortic involvement in patients with a bicuspid aortic valve. *Heart*, 97: 506–513.

14. Bruckner BA, Reardon MJ (2010) Bicuspid aortic valve and associated aortopathy: surgical considerations. *Methodist Debakey Cardiovasc J*, 6: 29–32.
15. Buchner S, Hülsmann M, Poschenrieder F, Hamer OW, Fellner C, Kobuch R, Feuerbach S, Riegger GA, Djavidani B, Luchner A, Debl K (2010) Variable phenotypes of bicuspid aortic valve disease: classification by cardiovascular magnetic resonance. *Heart*, 96: 1233–1240.
16. Cannata A, Russo CF, Martinelli L (2010) Relationship between bicuspid aortic valve morphology and aortic wall degeneration: further evidence is emerging. *Echocardiography*, 27: 1028; author reply 1029. doi: 10.1111/j.1540-8175.2010.01265.x.
17. Casselman FP, Gillinov AM, Akhrass R, Kasirajan V, Blackstone EH, Cosgrove DM (1999) Intermediate-term durability of bicuspid aortic valve repair for prolapsing leaflet. *Eur J Cardiothorac Surg*, 15: 302–308.
18. Caverzasio J (2004) Wnt/LRP5, a new regulation osteoblastic pathway involved in reaching peak bone masses. *Rev Med Suisse Romande*, 124: 81–82.
19. Cheitlin MD, Fenoglio JJ Jr, McAllister HA Jr, Davia JE, DeCastro CM (1978) Congenital aortic stenosis secondary to dysplasia of congenital bicuspid aortic valves without commissural fusion. *Am J Cardiol*, 42: 102–107.
20. Coady MA, Stockwell PH, Robich MP, Poppas A, Sellke FW (2010) Should aortas in patients with bicuspid aortic valve really be resected at an earlier stage than tricuspid? *CON. Cardiol Clin*, 28: 299–314.
21. Cotrufo M, Della Corte A, De Santo LS, Quarto C, De Feo M, Romano G, Amarelli C, Scardone M, Di Meglio F, Guerra G, Scarano M, Vitale S, Castaldo C, Montagnani S (2005) Different patterns of extracellular matrix protein expression in the convexity and the concavity of the dilated aorta with bicuspid aortic valve: preliminary results. *J Thorac Cardiovasc Surg*, 130: 504–511.
22. Cripe L, Andelfinger G, Martin LJ, Shooner K, Benson DW (2004) Bicuspid aortic valve is heritable. *J Am Coll Cardiol*, 44: 138–143.
23. David TE, Feindel CM (1992) An aortic valve-sparing operation for patients with aortic incompetence and aneurysm of the ascending aorta. *J Thorac Cardiovasc Surg*, 103: 617–521.
24. Dayan V, Cura L, Muñoz L, Areco D, Ferreiro A, Pizzano N (2010) Risk of subsequent aortic dilatation is low in patients with bicuspid aortic valve and normal aortic root diameter at the time of aortic valve replacement. *Interact Cardiovasc Thorac Surg*, 10: 535–538.
25. De Mozzi P, Longo UG, Galanti G, Maffulli N (2008) Bicuspid aortic valve: a literature review and its impact on sport activity. *Br Med Bull*, 85: 63–85.
26. De Sá MP, Bastos ES, Murad H (2009) Bicuspid aortic valve: theoretical and clinical aspects of concomitant ascending aorta replacement. *Rev Bras Cir Cardiovasc*, 24: 218–224.
27. Della Corte A, Cotrufo M (2008) Bicuspid aortopathy or bicuspid aortopathies? The risk in generalizing. *J Thorac Cardiovasc Surg*, 136: 1604.
28. Desai PA, Tafreshi J, Pai RG (2011) Beta-blocker therapy for valvular disorders. *J Heart Valve Dis*, 20: 241–253.
29. Doss M, Risteski P, Sirat S, Bakhtiary F, Martens S, Moritz A (2010) Aortic root stability in bicuspid aortic valve disease: patch augmentation plus reduction aortoplasty versus modified David type repair. *Eur J Cardiothorac Surg*, 38: 523–527.
30. Evangelista A (2011) Bicuspid aortic valve and aortic root disease. *Curr Cardiol Rep*, 13: 234–241.
31. Favaloro R, Stutzbach P, Gomez C, Machain A, Casabe H (2002) Feasibility of the Ross procedure: its relationship with the bicuspid aortic valve. *J Heart Valve Dis*, 11: 375–382.
32. Fedak PW, Verma S, David TE, Leask RL, Weisel RD, Butany J (2002) Clinical and pathophysiological implications of a bicuspid aortic valve. *Circulation*, 106: 900–904.
33. Fernandes SM, Khairy P, Sanders SP, Colan SD (2007) Bicuspid aortic valve morphology and interventions in the young. *J Am Coll Cardiol*, 49: 2211–2214.
34. Fernandes SM, Sanders SP, Khairy P, Jenkins KJ, Gauvreau K, Lang P, Simonds H, Colan SD (2004) Morphology of bicuspid aortic valve in children and adolescents. *J Am Coll Cardiol*, 44: 1648–1651.
35. Fernández B, Durán AC, Fernández-Gallego T, Fernández MC, Such M, Arqué JM, Sans-Coma V (2009) Bicuspid aortic valves with different spatial orientations of the leaflets are distinct etiological entities. *J Am Coll Cardiol*, 54: 2312–2318.
36. Gilkeson RC, Markowitz AH, Balgude A, Sachs PB (2006) MDCT evaluation of aortic valvular disease. *Am J Roentgenol*, 186: 350–360.
37. Girdauskas E, Borger MA, Kuntze T, Hope MD (2010) Aortopathy in bicuspid aortic valve disease: is it really congenital? *Radiology*, 256: 1015–1016 (author reply 1016).
38. Holmen SL, Salic A, Zylstra CR, Kirschner MW, Williams BO (2002) A novel set of Wnt-Frizzled fusion proteins identifies receptor components that activate β -catenin-dependent signaling. *J Biol Chem*, 277: 34727–34735.
39. Ichihara T, Fujii G, Sasaki M, Kawaguchi O, Ueda Y (2006) Clinical characteristics of bicuspid aortic valves in surgical patients. *Asian Cardiovasc Thorac Ann*, 14: 210–212.
40. Ikonomidis JS, Jones JA, Barbour JR, Stroud RE, Clark LL, Kaplan BS, Zeeshan A, Bavaria JE, Gorman JH 3rd, Spinale FG, Gorman RC (2007) Expression of matrix metalloproteinases and endogenous inhibitors within ascending aortic aneurysms of patients with bicuspid or tricuspid aortic valves. *J Thorac Cardiovasc Surg*, 133: 1028e36.
41. Iqtidar AF, O'Rourke DJ, Silverman DI, Thompson PD, DiScipio AW, Palac RT (2011) Predictors of rapid aortic dilatation in adults with a bicuspid aortic valve. *J Heart Valve Dis*, 20: 292–298.
42. Isner JM, Chokshi SK, DeFranco A, Braimen J, Slovenkai GA (1990) Contrasting histoarchitecture of calcified leaflets from stenotic bicuspid versus stenotic tricuspid aortic valves. *J Am Coll Cardiol*, 15: 1104–1108.
43. Jackson V, Petrini J, Caidahl K, Eriksson MJ, Liska J, Eriksson P, Franco-Cereceda A (2011) Bicuspid aortic valve leaflet morphology in relation to aortic root morphology: a study of 300 patients undergoing open-heart surgery. *Eur J Cardiothorac Surg*, 40: e118–e124.
44. Jain D, Dietz HC, Oswald GL, Maleszewski JJ, Halushka MK (2011) Causes and histopathology of ascending aortic

- disease in children and young adults. *Cardiovasc Pathol*, 20: 15–25.
45. Jassal DS, Bhagirath KM, Tam JW, Sochowski RA, Dumesnil JG, Giannoccaro PJ, Jue J, Pandey AS, Joyner CD, Teo KK, Chan KL (2010) Association of Bicuspid aortic valve morphology and aortic root dimensions: a sub-study of the aortic stenosis progression observation measuring effects of rosuvastatin (ASTRONOMER) study. *Echocardiography*, 27: 174–179.
 46. Joo I, Park EA, Kim KH, Lee W, Chung JW, Park JH (2011) MDCT differentiation between bicuspid and tricuspid aortic valves in patients with aortic valvular disease: correlation with surgical findings. *Int J Cardiovasc Imag*, [Epub ahead of print].
 47. Kilickesmez KO, Abaci O, Kocas C, Yildiz A, Kaya A, Okcun B, Kucukoglu S (2011) Dilatation of the ascending aorta and serum alpha 1-antitrypsin level in patients with bicuspid aortic valve. *Heart Vessels*, [Epub ahead of print]
 48. Kim SY, Martin N, Hsia EC, Pyeritz RE, Albert DA (2005) Management of aortic disease in Marfan syndrome: a decision analysis. *Arch Intern Med*, 165: 749–755.
 49. Kin H, Izumoto H, Nakajima T, Kawase T, Kamata J, Ishihara K, Kawazoe K (2003) Midterm results of conservative repair of the incompetent bicuspid aortic valve. *J Cardiovasc Surg (Torino)*, 44: 19–23.
 50. Koide S, Kanabuchi K, Odagiri S, Shohtsu A (1993) Artificial valve replacement for congenital bicuspid aortic valves. *Tokai J Exp Clin Med*, 18: 149–153.
 51. Konstantinov IE, Saxena P (2010) Valve-sparing aortic root replacement and tricuspidization in a patient with an asymmetric bicuspid aortic valve. *Tex Heart Inst J*, 37: 79–81.
 52. Kopf MS, Gajayanaka R, Passik CS (2011) Infective endocarditis in two young men with previously undiagnosed bicuspid aortic valves. *Conn Med*, 75: 269–272.
 53. Kuboki K (2000) Clinicopathologic study of congenital bicuspid aortic valve in the aged. *J Cardiol*, 35: 287–296.
 54. Laforest B, Andelfinger G, Nemer M (2011) Loss of Gata5 in mice leads to bicuspid aortic valve. *J Clin Invest*, 121. pii: 44555. doi: 10.1172/JCI44555.
 55. Luciani GB, Favaro A, Casali G, Santini F, Mazzucco A (2005) Ross operation in the young: a ten-year experience. *Ann Thorac Surg*, 80: 2271–2277.
 56. Mahle WT, Sutherland JL, Frias PA (2010) Outcome of isolated bicuspid aortic valve in childhood. *J Pediatr*, 157: 445–449.
 57. Markwald RR, Norris RA, Moreno-Rodriguez R, Levine RA (2010) Developmental basis of adult cardiovascular diseases: valvular heart diseases. *Ann NY Acad Sci*, 1188: 177e83.
 58. McMullan DM, Oppido G, Davies B, Kawahira Y, Cochrane AD, d'Udekem d'Acoz Y, Penny DJ, Brizard CP (2007) Surgical strategy for the bicuspid aortic valve: tricuspidization with cusp extension versus pulmonary autograft. *J Thorac Cardiovasc Surg*, 134: 90–98.
 59. Misawa Y, Hasegawa T, Oyama H, Sudo H, Hasegawa N, Kamisawa O (1993) Congenital bicuspid aortic valve with regurgitation: a rare case showing a fibrous band between the conjoined cusp and the ascending aorta. *Nippon Kyobu Geka Gakkai Zasshi*, 41: 2156–2159.
 60. Mueller XM, Tevaearai HT, Genton CY, Hurni M, Ruchat P, Fischer AP, Stumpe F, von Segesser LK (1997) Draw-back of aortoplasty for aneurysm of the ascending aorta associated with aortic valve disease. *J Thorac Cardiovasc Surg*, 63: 762–767.
 61. Nakamura K, Onitsuka T, Nakamura E, Yano M, Matsuzaki Y, Nabeshima K (1999) Rare cases of congenital bicuspid aortic valve with an abnormal fibrous band. *Ann Thorac Cardiovasc Surg*, 5: 343–346.
 62. Nataatmadja M, West M, West J, Summers K, Walker P, Nagata M, Watanabe T (2003) Abnormal extracellular matrix protein transport associated with increased apoptosis of vascular smooth muscle cells in Marfan syndrome and bicuspid aortic valve thoracic aortic aneurysm. *Circulation*, 10 (suppl. 1): II329–II334.
 63. Nistri S, Grande-Allen J, Noale M, Basso C, Siviero P, Maggi S, Crepaldi G, Thiene G (2008) Aortic elasticity and size in bicuspid aortic valve syndrome. *Eur Heart J*, 29: 472–479.
 64. Normand J, Loire R, Zambartas C (1988) The anatomical aspects of adult aortic stenosis. *Eur Heart J*, 9 (suppl. E): 31–36.
 65. Olearchuk AS (2004) Congenital bicuspid aortic valve disease with an aneurysm of the ascending aorta in adults: vertical reduction aortoplasty with distal external synthetic wrapping. *J Card Surg*, 19: 144–148.
 66. Osaka K, Kamada M, Nagamine S, Kakihata H (2004) Surgery for aortic valve disease with congenital bicuspid aortic valve. *Kyobu Geka*, 57: 1213–1216.
 67. Pape LA, Tsai TT, Isselbacher EM, Oh JK, O'gara PT, Evangelista A, Fattori R, Meinhardt G, Trimarchi S, Bossone E, Suzuki T, Cooper JV, Froehlich JB, Nienaber CA, Eagle KA; International Registry of Acute Aortic Dissection (IRAD) Investigators (2007) Aortic diameter ≥ 5.5 cm is not a good predictor of type A aortic dissection: observations from the International Registry of Acute Aortic Dissection (IRAD). *Circulation*, 116: 1120–1127.
 68. Passik CS, Ackermann DM, Pluth JR, Edwards WD (1987) Temporal changes in the causes of aortic stenosis: a surgical pathologic study of 646 cases. *Mayo Clin Proc*, 62: 119–123.
 69. Penther P, Boschat J, Etienne Y, Le Potier J, Gilard M (1988) Narrow and calcified aortic valve stenosis in subjects in their 8th and 9th decades. An anatomic study of 64 cases. *Arch Mal Coeur Vaiss*, 81: 887–893.
 70. Prêtre R, Kadner A, Dave H, Bettex D, Genoni M (2006) Tricuspidisation of the aortic valve with creation of a crown-like annulus is able to restore a normal valve function in bicuspid aortic valves. *Eur J Cardiothorac Surg*, 29: 1001–1006.
 71. Raizada V, Roth R, Abrams J, Schroeder K (1982) Superiority of two-dimensional echocardiography in the diagnosis of congenitally bicuspid aortic valve. *Jpn Heart J*, 23: 305–313.
 72. Rajamannan NM (2011) Bicuspid aortic valve disease: the role of oxidative stress in Lrp5 bone formation. *Cardiovasc Pathol*, 20: 168–176.
 73. Roberts WC (1970) The structure of the aortic valve in clinically isolated aortic stenosis: an autopsy study of 162 patients over 15 years of age. *Circulation*, 42: 91–97.
 74. Russo CF, Cannata A, Lanfranconi M, Vitali E, Garatti A, Bonacina E (2008) Is aortic wall degeneration related

- to bicuspid aortic valve anatomy in patients with valvular disease? *J Thorac Cardiovasc Surg*, 136: 937–942.
75. Sabet HY, Edwards WD, Tazelaar HD, Daly RC (1999) Congenitally bicuspid aortic valves: a surgical pathology study of 542 cases (1991 through 1996) and a literature review of 2,715 additional cases. *Mayo Clin Proc*, 74: 14–26.
 76. Sadee AS, Becker AE, Verheul HA, Bouma B, Hoedemaker G (1992) Aortic valve regurgitation and the congenitally bicuspid aortic valve: a clinico-pathological correlation. *Br Heart J*, 67: 439–441.
 77. Sans-Coma V, Fernández B, Durán AC, Thiene G, Arqué JM, Muñoz-Chápuli R, Cardo M (1996) Fusion of valve cushtions as a key factor in the formation of congenital bicuspid aortic valves in Syrian hamsters. *Anat Rec*, 244: 490–498.
 78. Schaefer BM, Lewin MB, Stout KK, Byers PH, Otto CM (2007) Usefulness of bicuspid aortic valve phenotype to predict elastic properties of the ascending aorta. *Am J Cardiol*, 99: 686–690.
 79. Schaefer BM, Lewin MB, Stout KK, Gill E, Prueitt A, Byers PH, Otto CM (2008) The bicuspid aortic valve: an integrated phenotypic classification of leaflet morphology and aortic root shape. *Heart*, 94: 1634–1638.
 80. Schäfers HJ, Kuniyama T, Fries P, Brittner B, Aicher D (2010) Valve-preserving root replacement in bicuspid aortic valves. *J Thorac Cardiovasc Surg*, 140 (6 suppl.): S36–S40.
 81. Schäfers HJ, Langer F, Aicher D, Graeter TP, Wendler O (2000) Remodeling of the aortic root and reconstruction of the bicuspid aortic valve. *Ann Thorac Surg*, 70: 542–546.
 82. Sievers HH, Schmidtke C (2007) A classification system for the bicuspid aortic valve from 304 surgical specimens. *J Thorac Cardiovasc Surg*, 133: 1226–1233.
 83. Sievers HH, Sievers HL (2011) Aortopathy in bicuspid aortic valve disease — genes or hemodynamics? or Scylla and Charybdis? *Eur J Cardiothorac Surg*, 39: 803–804.
 84. Siu SC, Silversides CK (2010) Bicuspid aortic valve disease. *J Am Coll Cardiol*, 55: 2789–2800.
 85. Sonoda M, Takenaka K, Uno K, Ebihara A, Nagai R (2008) A larger aortic annulus causes aortic regurgitation and a smaller aortic annulus causes aortic stenosis in bicuspid aortic valve. *Echocardiography*, 25: 242–248.
 86. Subramanian R, Olson LJ, Edwards WD (1984) Surgical pathology of pure aortic stenosis: a study of 374 cases. *Mayo Clin Proc*, 59: 683–690.
 87. Sundt TM 3rd (2010) Replacement of the ascending aorta in bicuspid aortic valve disease: where do we draw the line? *J Thorac Cardiovasc Surg*, 140 (6 suppl.): S41–S44.
 88. Svensson LG, Kim KH, Blackstone EH, Rajeswaran J, Gillinov AM, Mihaljevic T, Griffin BP, Grimm R, Stewart WJ, Hammer DF, Lytle BW (2011) Bicuspid aortic valve surgery with proactive ascending aorta repair. *J Thorac Cardiovasc Surg*, 142: 622–629.e3.
 89. Svensson LG, Kim KH, Lytle BW, Cosgrove DM (2003) Relationship of aortic cross-sectional area to height ratio and the risk of aortic dissection in patients with bicuspid aortic valves. *J Thorac Cardiovasc Surg*, 126: 892–893.
 90. Tanaka R, Yoshioka K, Niinuma H, Ohsawa S, Okabayashi H, Ehara S (2010) Diagnostic value of cardiac CT in the evaluation of bicuspid aortic stenosis: comparison with echocardiography and operative findings. *Am J Roentgenol*, 195: 895–899.
 91. Togashi M, Tamura K, Masuda Y, Fukuda Y (2008) Comparative study of calcified changes in aortic valvular diseases. *J Nippon Med Sch*, 75: 138–145.
 92. Tokunaga H, Koyanagi H, Hashimoto A, Nakano K, Hirayama T, Hachida M, Imamaki M (1992) Classification of congenitally bicuspid aortic valve and its angiographic and surgical significance. *Nippon Kyobu Geka Gakkai Zasshi*, 40: 467–472.
 93. Veldtman GR, Connolly HM, Orszulak TA, Dearani JA, Schaff HV (2006) Fate of bicuspid aortic valves in patients undergoing aortic root repair or replacement for aortic root enlargement. *Mayo Clin Proc*, 81: 322–326.
 94. Wald O, Korach A, Shapira OM (2010) Should aortas in patients with bicuspid aortic valve really be resected at an earlier stage than tricuspid? *PRO. Cardiol Clin*, 28: 289–298.
 95. Walley VM, Antecol DH, Kyrollos AG, Chan KL (1994) Congenitally bicuspid aortic valves: study of a variant with fenestrated raphe. *Can J Cardiol*, 10: 535–542.
 96. Ward C (2000) Clinical significance of the bicuspid aortic valve. *Heart*, 83: 81–85.
 97. Wijesinghe N, Ye J, Rodés-Cabau J, Cheung A, Velianou JL, Natarajan MK, Dumont E, Nietlispach F, Gurvitch R, Wood DA, Tay E, Webb JG (2010) Transcatheter aortic valve implantation in patients with bicuspid aortic valve stenosis. *J Am Coll Cardiol Cardiovasc Interv*, 3: 1122–1125.
 98. Wilton E, Bland M, Thompson M, Jahangiri M (2008) Matrix metalloproteinase expression in the ascending aorta and aortic valve. *Interact Cardiovasc Thorac Surg*, 7: 37–40.
 99. Yabe A, Ohkawa S, Watanabe C, Chida K, Kuboki K (2000) Clinicopathologic study of calcified aortic valve stenosis in the aged, and evaluation of the indications for percutaneous aortic balloon valvuloplasty. *J Cardiol*, 36: 311–319.
 100. Yamada T, Kaneko H, Imaseki T, Nakahara H, Yokoyama M, Ohshima N, Tanabe S, Irie Y (1990) Significance of raphe in congenitally bicuspid aortic valve. *Kyobu Geka*, 43: 258–266.
 101. Yoshikai M, Muraya J, Fujita H (2006) Stenosis of the bicuspid aortic valve with systemic lupus erythematosus. *Jpn J Thorac Cardiovasc Surg*, 54: 16–18.
 102. Yotsumoto G, Moriyama Y, Toyohira H, Shimokawa S, Iguro Y, Watanabe S, Masuda H, Hisatomi K, Taira A (1999) Congenital bicuspid aortic valve: analysis of 63 surgical cases. *J Heart Valve Dis*, 7: 500–503.
 103. Zalaquett R, Camplá C, Scheu M, Córdova S, Becker P, Morán S, Irrarrázaval MJ, Baeza C, Arretz C, Braun S, Chamorro G, Godoy I, Yáñez F (2005) Valve repair surgery for incompetent bicuspid aortic valves. *Rev Med Chil*, 33: 279–286.