

The types of neurones in the neostriatum of the guinea pig (*Cavia porcellus*): Golgi and Klüver-Barrera studies

Stanislaw Szteyn, Anna Robak, Maciej Równiak

Department of Comparative Anatomy, Warmia and Masuria University, Olsztyn, Poland

[Received 16 December 1999; Revised 3 January 2000; Accepted 4 January 2000]

The Golgi technique stain was used to reveal the cellular structure of the neostriatum (nucleus caudatus and putamen) in the guinea pig. The computerised reconstructions were made from Golgi impregnated neurones. On the basis of various criteria, 4 types of neurones were distinguished in the guinea pig neostriatum:

1. *The rounded neurones (most numerous) with 5–8 thin dendritic trunks;*
2. *The triangular nerve cells with 3 thick dendritic trunks;*
3. *Two types of multipolar neurones differing in dendritic arborisation pattern with 4–6 and 7–9 primary dendrites, respectively.*
4. *The pear-shaped cells, which divide into two distinctly different subpopulations.*

key words: neostriatum, neuronal structure, guinea pig

INTRODUCTION

The aim of our studies was to give full morphological characteristics of the neuronal structure in the neostriatum (nucleus caudatus and putamen) of the guinea pig. Studies of the neuronal composition of the neostriatum on the basis of Golgi preparations had been carried out in a number of mammal species — rat [5,10], cat [7,11,16], monkey [8,9,11], rabbit [11] and bison [19]. There have also been some observations in man [6,11]. The data and final conclusions according to the observations of many authors are often different and sometimes contradictory [15]. These differences are probably caused by the staining specificity of the Golgi procedure and by the large number of its modifications. However, the Golgi technique, very helpful in the qualitative investigations of the neuronal structures, has several limitations, including the fact that it stains only a small, not necessarily representative, percentage of the whole neuronal population. Therefore the ar-

range and packing density of neuronal populations cannot be correctly evaluated.

Our investigations made on the neostriatum of the guinea pig are thought to be complementary and confirmatory. The application of two different Golgi procedures allowed us to attain more real qualitative pictures, and the Klüver-Barrera method allowed us to achieve also quantitative data of the examined structures.

MATERIALS AND METHODS

The studies were carried out on the telecephalons of 6 adult guinea pigs. The preparations were impregnated according to two different Golgi procedures (60- μ m-thick sections) and stained with cresyl violet (15- μ m-thick sections). The material was fixed in formalin, dehydrated in ethyl alcohol and embedded in paraffin. The microscopic images of chosen neurones impregnated according to Golgi technique were digitally recorded by means of a cam-

era that was coupled with a microscope and an image processing system (VIST-Wikom, Warsaw). From 50 to 100 such digital microscopic pictures were taken at different focus layers of the section for each neurone. The computerised reconstructions of microscopic images were made on the basis of these series. The neuropil and other neurones were removed to clarify the picture.

RESULTS

While distinguishing the types of neurones, the following criteria were taken into account: the shape and size of perikaryons, the number of dendritic trunks and their arborisation pattern, the appearance and course of axon, as well as the distribution and structure of tigroidal substance.

On the basis of the criteria presented above, four types of neurones were distinguished in the neostriatum of the guinea pig:

1. The rounded neurones (Figs. 1A and 1B). These neurones are the most numerous and constitute about 90% of the total number of nerve cells forming neostriatum. The perikaryons measure from 16 to 28 μm ., but the majority of them 16–20 μm . Only a small number of these cells has larger somata [25–28 μm]. From the soma there arise 5–8 thin dendritic trunks without conus. The dendritic trunks bifurcate dichotomically close to the cell bodies (10–15 μm) and many of them give off fine collaterals. Most dendrites divide once again after a distance of 15–20 μm . From this place dendritic branches have a varicose course and show the spines. A thin axon emerges directly from the cell body. The fine granules of tigroidal substance are peripherally distributed around the cell nucleus and do not penetrate into the initial portions of the dendritic trunks.

2. The triangular nerve cells (Figs. 2A and 2B). The cell bodies measure from 28 to 35 μm . This type represents about 8% of neurones in the neostriatum. From the perikaryons there arise conically 3 thick dendritic trunks. Most dendritic trunks bifurcate dichotomically at a distance of 15–20 μm . from the perikaryon and some of them (but not numerous) close to the cell body. Some dendrites give off at the distal segments numerous ramifications covered with spines. A thick axon emerges directly from the soma, near to the conus of a dendrite. The dendritic field is large and has a spherical form. The cells contain numerous, thick tigroidal granules, which penetrate deeply into the initial portions of the dendritic trunks.

3. The multipolar neurones (Figs. 3A and 3B). These cells constitute about 1% of the total number

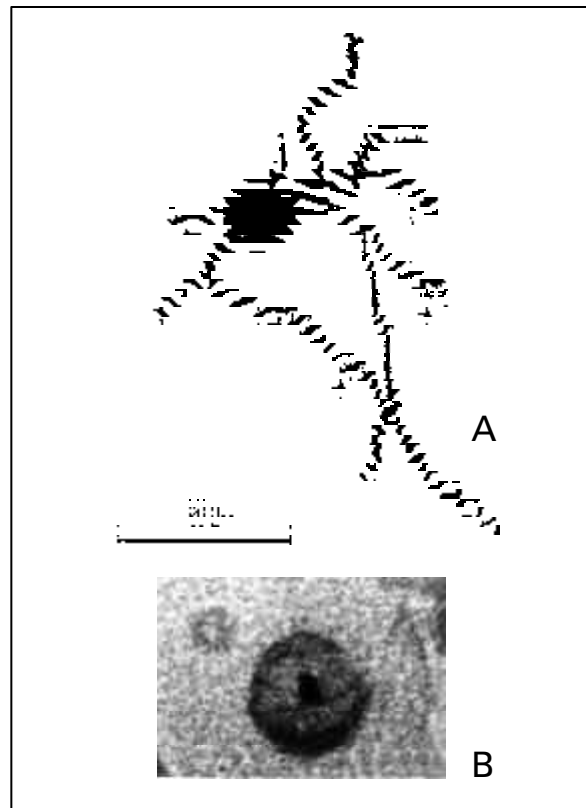


Figure 1. The rounded neurones: Golgi impregnation (A); Klüver-Barrera method (B)

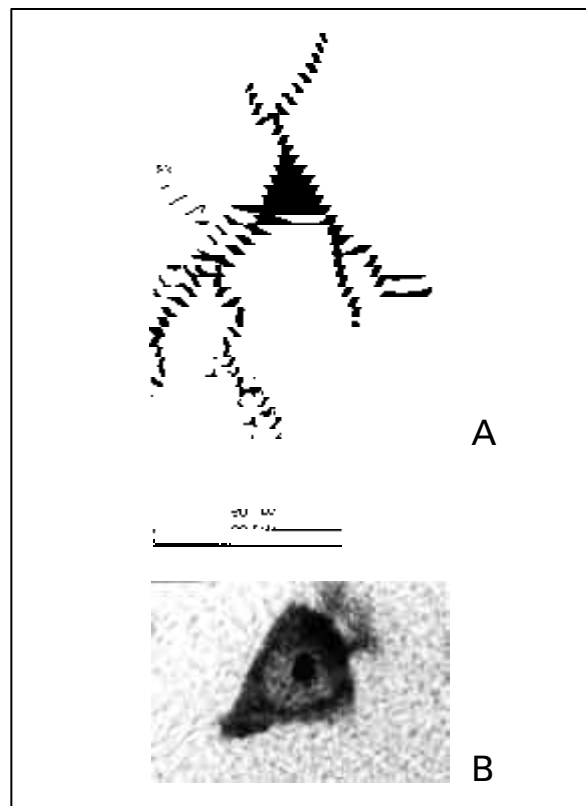


Figure 2. The triangular neurones: Golgi impregnation (A), axon — axon; Klüver-Barrera method (B)

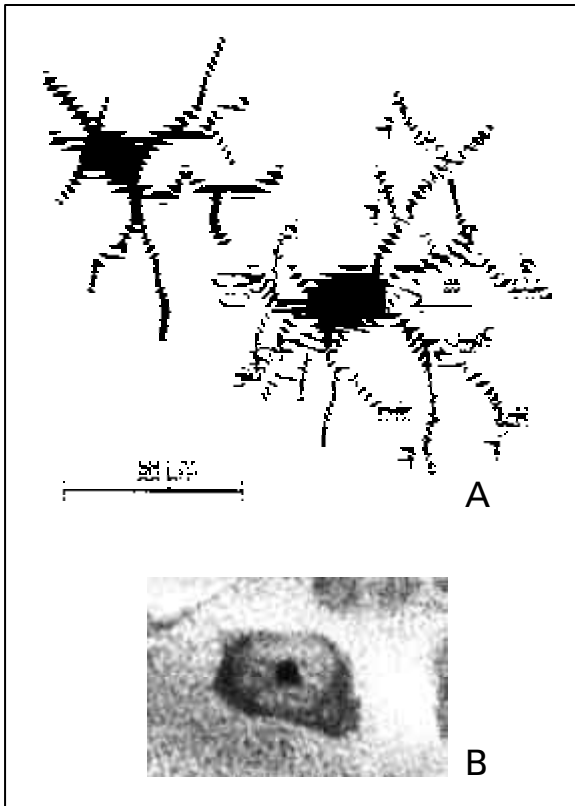


Figure 3. The multipolar neurones: Golgi impregnation (A), ax — axon; Klüver-Barrera method (B)

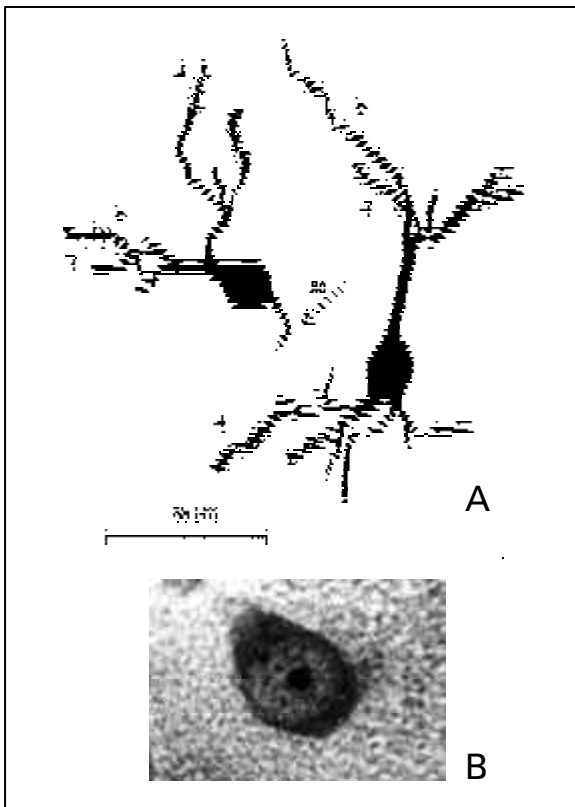


Figure 4. The pear-shaped neurones: Golgi impregnation (A), ax — axon; Klüver-Barrera method (B)

of neostriatal neurones and divide into 2 distinctly different sub-populations. One of them has perikaryons which measure from 32 to 40 μm . and send off 7–9 thin, richly arborised dendritic trunks. The branches of the dendritic trunks are covered with spines. The second kind has cell bodies measuring 25 to 35 μm with 4–6 thick weakly arborised dendritic trunks. The branches of the dendritic trunks are devoid of spines. Only final parts of ramifications show a varicose course. In both kinds of multipolar neurones a thin axon is separated from the dendritic trunks and emerges directly from the soma. The cells contain numerous thick, spherical granules of the tigroidal substance. The tigroidal granules penetrate the initial segments of the dendritic trunks only for a short distance.

4. The pear shaped cells (Figs. 4A and 4B). The pear-shaped cells constitute about 1% of neurones forming the caudate nucleus and putamen. They divide into two kinds. The first one creates neurones with one dendritic trunk arising from one pole of the soma, and 2–3 dendritic trunks arising from the opposite pole of the cell body. A thin, short axon emerges directly from the soma between the dendritic trunks and is difficult to impregnate. The neurones of the second type give off 1–2 thick dendritic trunks from one pole, whereas from the opposite pole of the perikaryon there emanates a short axon. The dendritic trunks divide irregularly into tuft-like ramifications. These ramifications are covered with not numerous spines. The perikaryons of the pear-shaped cells measure from 15 to 22 μm . Many thick granules of the tigroidal substance are distributed peripherally in the soma, around the cell nuclei.

DISCUSSION

Type 1 – the medium-size rounded neurones with dendrites densely packed with spines observed in our studies correspond probably to spiny-medium size neurones in the neostriatum of the monkey [8,9], cat [10], bison [19] and man [6]. It is the commonest cell type and comprises 95% of the total population of the neurones in the mammalian neostriatum; in our studies about 90%. In Nissl stained sections these neurones have an uniform pattern of pigmentation and contain many, small tigroidal granules.

Anatomical and physiological investigations suggest that this kind of neurones receives a massive input from the cerebral cortex, thalamus, substantia nigra, raphe nuclei and the locus coeruleus [2,7,13,17,21]. The medium size neostriatal spiny cells are histochemically differentiated. GABA, sub-

stance P, met-enkephalin and neurotensin can be probably produced by these neurones [1–4, 12–14, 22]. Effects of anterograde and retrograde labelling studies [2,13,14,17,23], and also analysis of synaptic buttons [4] indicate that the described cells are of an efferent nature. The main efferent targets are substantia nigra and globus pallidus.

Large neurones with long, infrequently branching dendrites are described in the rat neostriatum on the basis of immunocytochemistry and Golgi-impregnation studies by Bolam et al. [5] as „a type I of AChE-positive neurones“. A similar kind of cell was found by Kemp and Powell [16] in the neostriatum of the cat. They nominated these neurones „giant cells“. They are also comparable with „type III neurones“ of Braak and Braak [6] in man. The morphological features of one type of triangular cells and one subtype of multipolar neurones observed in our material suggest that these neurones can be also of a similar, cholinergic nature.

Our second subtype of multipolar neurones, with many richly arborised dendritic trunks, are morphologically distinct and distinguishable from cholinergic large cells. In some mammals, i.e. in bison [19], only one type of the large neurones was found in the neostriatum. It is generally accepted that large neurones send their axons outside of the neostriatum [23].

A morphological view of our pear-shaped cells (both subtypes) suggests that they belong to the Golgi Type II interneurones [11,18,20]. The pear-shaped cells have short axon and are difficult to impregnate. The dendrites are scarcely spiny and the diameter of the dendritic field is small. The dendritic branches divide in tuft-like manner in their final segments.

The differentiation of the neuronal architecture of the guinea pig into 4 types and 2 subtypes of nerve cells is not rich. Eder et al. [11] described in the caudate nucleus of the cat — 7, monkey — 6 and man — 9 types of neurones. Many authors suppose that the numbers of neuronal types and subtypes in the mammalian neostriatum „show an increasing tendency in the phylogenetic series“ [11].

REFERENCES

1. Beckstead RM, Kersey KS (1985) Immunohistochemical demonstration of differential substance P., met-enkephalin and glutamic acid-decarboxylase-containing cell body and distribution in the corpus striatum of the cat. *J Comp Neurol*, 232: 481–498.
2. Beckstead RM (1987) Striatal substance P. cell cluster coincide with the high density terminal zones of the discontinuous nigrostriatal dopaminergic projection system in the cat; a study by combined immunohistochemistry and autoradiography axon-tracing. *Neuroscience*, 20: 557–576.
3. Bolam JP, Somogyi P, Totterdell S, Smith AD (1981) A second type of striatonigral neurone: a comparison between retrogradely labelled and Golgi stained neurones at the light and electron levels. *Neuroscience*, 6: 2141–2157.
4. Bolam JP, Somogyi P, Takagi H, Fodor I, Smith AD (1983) Localisation of substance P-like immunoreactivity in neurones and nerve terminals in the neostriatum of the rat: a correlated light and electron microscopic study. *J Neurocytol*, 12: 325–344.
5. Bolam JP, Wainer BBH, Smith AD (1984) Characterisation of cholinergic neurones in the rat neostriatum. A combination choline acetyltransferase immunocytochemistry, Golgi-impregnation and electron microscopy. *Neuroscience*, 12: 711–718.
6. Braak H, Braak E (1982) Neuronal types in the striatum of man. *Cell Tissue Res*, 227: 319–342.
7. Desban M, Gauchy C, Kemel ML, Besson MJ, Glowinski J (1989) Three-dimensional organisation of the striosomal compartment and patchy distribution of striatonigral projections in the matrix of the cat caudate nucleus. *Neuroscience*, 29: 551–566.
8. Difiglia M, Pasik P, Pasik T (1976) A Golgi study of neuronal types in the neostriatum of monkey. *Brain Res*, 114: 245–256.
9. Difiglia M, Pasik T, Pasik P (1980) Ultrastructure of Golgi-impregnated and gold-toned spiny and aspiny neurones in the monkey neostriatum. *J Neurocytol*, 9: 471–492.
10. Dimova R, Vuillet J, Seite R (1980) Study of the rat neostriatum using a combined Golgi-electron microscope technique and serial sections. *Neuroscience*, 5: 1581–1596.
11. Eder M, Vizceley T, Tombol T (1980) Nerve cells of the rabbit, cat, monkey, and human caudate nucleus: a Golgi study. *Acta Morphol*, 28: 337–363.
12. Ferrante RJ, Kowall NW, Richardson Jr. EP, Bird ED, Martin JB (1986) Topography of enkephalin, substance P. and acetylcholinesterase staining Huntington's disease striatum. *Neurosci Lett*, 71: 283–288.
13. Groves PM (1983) A theory of the functional organisation of the neostriatum and the neostriatal control of voluntary movement. *Brain Res*, 5: 109–132.
14. Groves PM, Martone M, Young SJ, Armstrong DM (1988) Three-dimensional pattern of enkephalin-like immunoreactivity in the caudate nucleus of the cat. *J Neurosci*, 8: 892–900.
15. Kaiya H, Kreutzberg GW, Namba M (1980) Ultrastructure of acetylcholinesterase synthesising neurones in the neostriatum. *Brain Res*, 187: 369–382.
16. Kemp JM, Powel TPS (1971) The structure of the caudate nucleus of the cat. Light and electron microscopy. *Phil Trans, London*, SB, 262: 383–401.
17. Misgeld U, Frotscher M, Wagner A (1984) Identification of projecting neurones in rat neostriatal slices. *Brain Res*, 299: 367–370.
18. Morest DK (1971) Dendrodendritic synapses of cells that have axons: the fine structure of the Golgi type II cell in the medial geniculate body of the cat. *Z Anat Entwickl Gesch*, 133: 216–246.

19. Równiak M, Szteyn S, Robak A, Klawon M, Dusza M (1994) The types of neurones in the neostriatum of bison *bonasus*. Nissl and Golgi study. *Folia Morphol*, 53: 165–176.
20. Rutheford JG, Gwyn DG (1980) A light and electron microscopic study of the inferior olivary nucleus of the squirrel monkey, *Saimiri sciureus*. *J Comp Neurol*, 189: 127–155.
21. Somogyi P, Bolam JP, Smith AD (1981) Monosynaptic cortical input and local axon collaterals of identified striatonigral neurones. A light and electron microscopic study using the Golgi-peroxidase transport-degeneration procedure. *J Comp Neurol*, 195: 567–584.
22. Sugimoto T, Mizuno N (1986) Immunohistochemical demonstration of neurotensin in striatal neurones of the cat, with particular reference to coexistence with enkephalin. *Brain Res*, 398: 195–198.
23. Szabo J (1979) Strionigral and nigrostriatal connections. *Applied Neurophysiology*, 42: 9–12.