VIA MEDICA

ORIGINAL ARTICLE

Folia Morphol.
Vol. 59, No. 2, pp. 99–103

ISSN 0015–5659

Surgical anatomy of anterior petrosectomy

Paweł Słoniewski, Piotr Zieliński, Michał Rynkowski

Department of Neurosurgery, Medical University of Gdańsk, Poland

[Received 22 December 2000; Revised 3 February 2000; Accepted 4 February 2000]

Neurosurgical procedures in the region of the petroclival region of the skull base require unique knowledge of the local anatomy. The measurements of this region considering the visible anatomical landmarks are helpful both during surgery and while planning the general schemes for the approach.

We have evaluated the anatomy of the anterior surface of the petrous bone and of the middle fossa taking into consideration the surgical removal of part of the petrous bone — the anterior petrosectomy. We have measured the distances and angles between the chosen structures in this region. The measurements were taken on 10 skulls, on both sides.

The results enrich the algorithm of the anterior petrosectomy.

key words: skull base surgery, Kawase approach, aneurysm, arteria basilaris

INTRODUCTION

Knowledge of surgical anatomy requires not only perfect knowledge of the classical anatomy but also needs some acquaintance with the local geometry and with the anatomical views, changing step-by-step, according to specific schemes. The anatomy of the surgical approaches is very demanding in neurosurgery, especially in surgery of the skull base. There are numerous limitations when choosing the approach to the base of the skull. Brain compression should be avoided as much as possible. The nerves and vessels should be treated with special attention. On the other hand, the pathologic lesion should be exactly visualised, even at the cost of the extended bone removal.

"The brain should not know that it is being operated on", said Harvey Cushing, and these words are fundamental for contemporary skull base surgery. The increasing knowledge of functional neuroanatomy stimulated the evolution of minimal brain invasion during surgery. The results of neurosurgery were highly improved with the development of microneurosurgical techniques, minimalising brain destruction [3]. Nowadays mortality in microneurosurgical procedures ranges from 0 to 5%. Misfortunes are especially frequent in the surgery of the posterior circulation aneurysms, which means the aneurysms of the basilar artery, posterior cerebral artery and cerebellar arteries [4–6,9].

Skull base surgery developed quickly thanks to the new surgical techniques from the late eighties. The invention of high speed drills was especially important in this field. They allow the removal of large quantities of bone in a short period of time and with relative safety for the cranial nerves and vessels [2].

Every neurosurgical approach to intracranial pathology is strictly related to the identification of the anatomical structures, visible on surfaces and layers. They form often definite geometrical polygons, which are very helpful in the navigation to the deeper localised structures. For many years this method has allowed neurosurgeons to find intracranial structures [7]. Besides, exact knowledge of surgical anatomy allows lesser skull openings and minimal brain retraction. The optimal approaches to the lesions situated in relation to the skull base are not those from the direction of the convexity, but from the base of the skull, even resulting in cosmetic deformities, but avoiding brain trauma [8].

From the anatomic point of view, the exact schema of anterior petrosectomy supplied with some morphometric data of the patient may create the possibility of optimal and safe basilar artery aneurysm surgery.

Address for correspondence: Prof. Paweł Słoniewski, Department of Neurosurgery, Medical University of Gdańsk, ul. Dębinki 7, 80–211 Gdańsk, Poland, tel: +48 58 329 23 30, fax: +48 58 345 58 88, e-mail: nchir@amg.gda.pl

MATERIAL AND METHODS

Morphometric analysis was performed on 10 dry adult skull specimens. The most important anatomical landmarks for petrosectomy were defined. The distances and angles between them were measured. The distances between the foramens were defined as the shortest distances between the bony openings. The distances between the foramens and the linear structures were defined as the distances between the bony openings and the middle point of the linear structures. The measured distances were between: foramen spinosum and foramen ovale, foramen spinosum and trigeminal fossa, foramen ovale and trigeminal fossa, foramen spinosum and hiatus of the greater petrosal nerve, foramen spinosum and sulcus of the greater petrosal nerve, foramen ovale and hiatus of the greater petrosal nerve, foramen ovale and sulcus of the greater petrosal nerve, hiatus of the greater petrosal nerve and emminentia arquata, hiatus of the greater petrosal nerve and sulcus of the upper petrosal sinus. The angles were measured between: the sulcus of the upper petrosal sinus and emminentia arquata, emminentia arquata and sulcus of the greater petrosal nerve, internal acoustic meatus and emminentia arquata. The results were shown as the arithmetic mean in millimetres or degrees and standard deviation.

RESULTS

The localisation of the emminentia arquata was doubtful in three skull specimens. The results are shown in Table 1.

The first step of petrosectomy is fronto-temporal or subtemporal craniotomy. Then the extradural approach with identification of the foramen spinosum, foramen ovale, carotid artery, greater and lesser petrosal nerve is performed (Fig. 1). Their mutual relations, difficult to evaluate during these first steps, are easier with the measurements (Table 1). Petrosal nerves can be dissected to avoid mechanical injury to the facial nerve [1]. Then the removal of the petrous bone is performed in front of the arquate eminence, alongside the greater petrosal nerve to the genu of the facial nerve. According to our measure-

Table 1. The results of the morphometric analysis of the anatomical bony landmarks in the region of the anterior petrosectomy approach

Distances and angles between:	Mean mm or degrees ± OS
foramen spinosum and foramen ovale	L: 3,5 ± 1,3 R: 3,4 ± 1,4
foramen spinosum and trigeminal fossa	L: 12,2 ± 1,9 R: 12,8 ± 1,5
foramen ovale and trigeminal fossa	L: 11 ± 1,8 R: 12,2 ± 2,0
foramen spinosum and hiatus of the greater petrosal nerve	L: 13,5 ± 2,7 R: 12,8 ± 3,5
foramen spinosum and sulcus of the greater petrosal nerve	L: 10,5 ± 2,0 R: 9,7 ± 2,7
foramen ovale and hiatus of the greater petrosal nerve	L: 18,6 ± 2,0 R: 18,2 ± 2,5
foramen ovale and sulcus of the greater petrosal nerve	L: 14,7 ± 1,6 R: 14,3 ± 2,1
hiatus of the greater petrosal nerve and emminentia arquata	L: 11,3 ± 1,8 R: 12,1 ± 2,6
hiatus of the greater petrosal nerve and sulcus of the upper petrosal sinus	L: 12,8 ± 1,5 R: 12,8 ± 2,2
the angle: sulus of the upper petrosal sinus and emminentia arquata	L: 91 ± 6,0 R: 84 ± 7,0
the angle: emminentia arquata and sulcus of the greater petrosal nerve	L: 90 ± 5,0 R: 85 ± 7,4
the angle: internal acoustic meatus and emminentia arquata	L: 115 ± 9,0 R: 95 ± 9,0

L — left, R — right

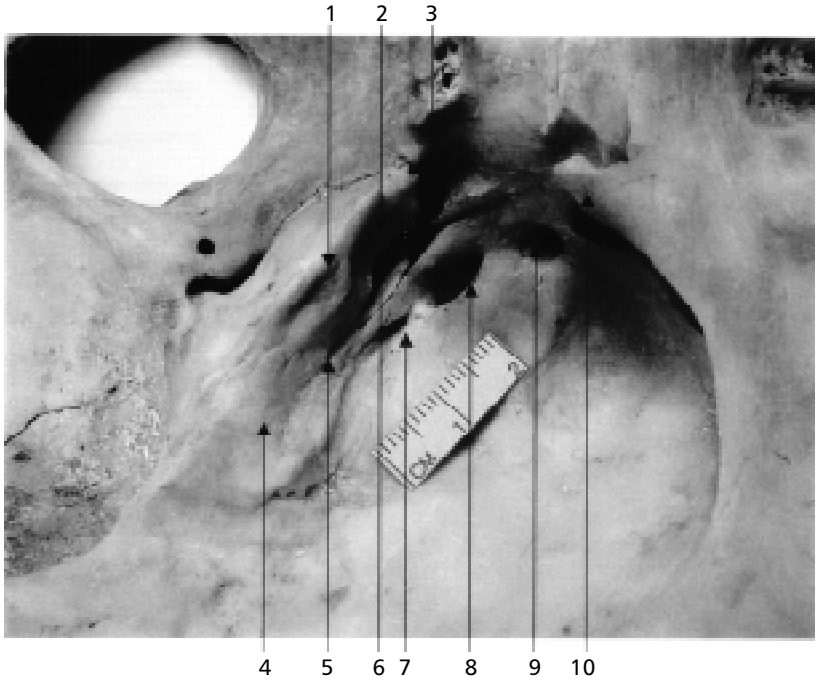

Figure 1. Anatomy of the region of the right petrous apex viewed from the middle fossa. Abrreviations: 1 — sulcus of the upper petrosal sinus, 2 — trigeminal fossa, 3 — lingula sphenoidalis, 4 — emminentia arquata, 5 — hiatus and sulcus of the greater petrosal nerve, 6 — foramen lacerum, 7 — foramen spinosum, 8 — foramen ovale, 9 — foramen rotundum, 10 — anterior clinoid process.

ments, the internal acoustic meatus is positioned at an angle of around 100 degrees to the arquate eminence. The cochlea, situated below the facial nerve, is the postero-lateral border of the petrosectomy. The final aim of the petrosectomy is the removal of the bone between the facial nerve, internal carotid artery and cochlea (laterally) and upper semicircular canal with internal acoustic meatus (posteriorly), up to the superior petrosal sinus. This creates a window into the posterior fossa between the internal carotid artery, trigeminal and facial nerve.

DISCUSSION

The master of skull base morphometry and neurosurgical anatomy remains Johannes Lang from Wurtzburg [16]. His perfect specimens and numerous measurements of the skull base are very helpful for every neurosurgeon. Such data help in establishing the surgical algorithms for the approaches.

The evolution of the approaches to the basilar artery attracts special attention. They pose some specific problems because of the deep position of the artery, its proximity to the brain stem and numerous perforators of the brain stem. For a long period of time the lesions of the basilar artery, like aneurysms, were considered inoperable. The approaches used for the basilar artery surgery are still not satisfactory whilst the availability of the proximal part of the artery in case of bleeding is insufficient [10–13]. Cardiac arrest used for the basilar artery surgery and endovascular treatment has not solved the problem. The results of our own work on the extension of the cranio-orbito-zygomatic craniotomy with cardiac arrest do not improve the proximal control of the basilar artery, although they have enhanced the procedure [17].

One of the examples illustrating the philosophy of skull base surgery techniques is the approach called anterior petrosectomy. This approach allows for operation in the region of the upper half of the clivus and in the region of the petrous apex [14,15]. Petrosectomy means the excision of part of the petrous bone and thus creates the window into the petroclival region. The most common diseases in this region are aneurysms of the basilar artery, meningiomas and chordomas. Petrosectomy may be proceeded from the middle cranial fossa. Then it is called the anterior one. It may be performed from the posterior and lateral direction, then it is called the posterior petrosectomy. Petrosectomy must be preceded by the skull opening. In the case of the anterior petrosectomy, it may be either a fronto-temporal or subtemporal craniotomy. The posterior petrosectomy may be preceded by the presigmoid craniotomy.

Anterior petrosectomy was introduced by Takeshi Kawase. He published in 1985 the results of the surgical treatment performed on two patients with basilar artery aneurysms [14]. Later on, Kawase made some modifications of this procedure, enlarging or lessening the extent of the removal of the petrous bone [14, 15]. The first part of the petrosectomy is performed extradurally. The area of the surgical work in this part is situated medially to the internal carotid artery (lateral and posterior loop), posteriorly to the foramen ovale and anteriorly to the internal acoustic porus. This approach in its classical form is used mainly by the author, but the results of treatment of the basilar artery aneurysms are very encouraging. It seems that anterior petrosectomy, after establishing the standard schema of this procedure, may become the approach of choice in the surgery of the basilar artery aneurysms.

We have found our data, shown in Table 1, helpful in performing the anterior petrosectomy, which can also be described in a defined step-by-step scheme. We have chosen to measure the specified landmarks and distances because of their practical usefulness during the procedure. The distances between the skull base foramina seem to be more valuable than, for example, the distances between the lateral side of the skull and these foramina, as published by other authors [16].

There are two anatomical triangles described in this region — the Glasscock and Kawase triangles (Fig. 2). The Glasscock triangle is defined laterally by the line from the foramen spinosum to the arquate emminence, medially by the greater petrosal nerve, basally by the third branch of the trigeminal nerve. The Kawase triangle is defined by the greater petrosal nerve, the petrous ridge and by the arquate emminence.

Our measurements seem to enhance the safety of the extradural middle fossa dissection as well as the removal of the petrous bone. They are helpful in establishing the scheme of the anterior petrosectomy.

REFERENCES

1. Aziz KMA, van Loveren HR, Tew JM, Chicoine MR (1999) The Kawase approach to retrosellar and upper clival basilar aneurysms, Neurosurgery, 44: 1225––1230.
2. Allen GS et al. (1974) Cerebral arterial spasm. Part 1; in vitro contractile activity of vasoactive agents on canine basilar and middle cerebral arteries, J. Neurosurg. 40: 433–441.
3. Al.-Mefty O (1987) The supraorbital-pterional approach to skull base lesions, Neurosurgery, 21: 474–477.
4. Al.-Mefty O (1986) Skull base. Zygomatic approach (letter), Neurosurgery, 19: 674–675.
5. Al.-Mefty O, Anand VK (1990) Zygomatic approach to skull base lesions. J Neurosurg, 73: 668–673.
6. Al.-Mefty O, Originato TC, Harkey LH (1996) Controversies in Neurosurgery, Thieme, Stuttgart, 159–165.

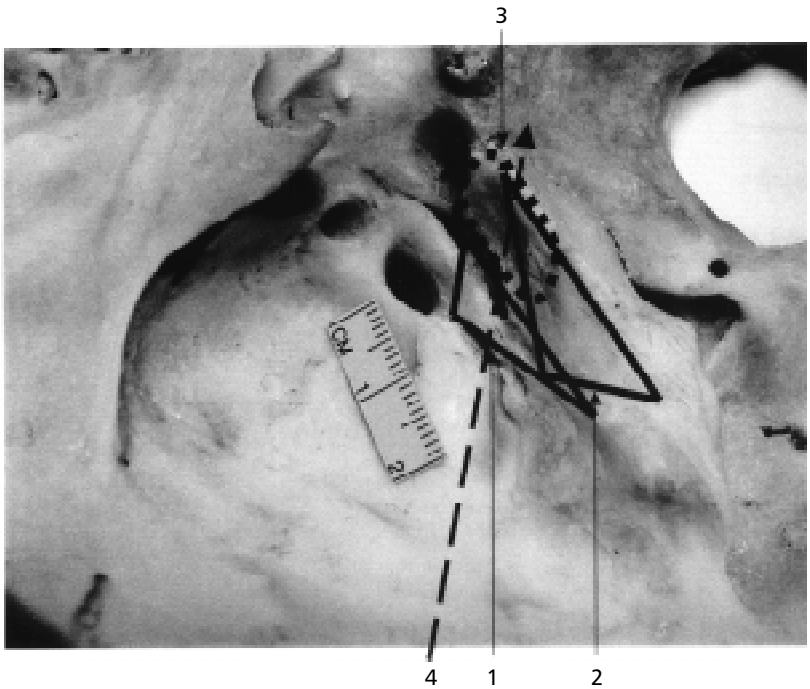

Figure 2. The extent of the anterior petrosectomy. Abrreviations: 1 — glasscock triangle, 2 — kawase triangle, 3 — the extent of the anterior petrosectomy, 4 — the direction of view into the posterior fossa through the window in the petrous bone.

7. Al.-Mefty, Smith RR (1988) Surgery of tumors invading the cavernous sinus, Surg. Neurol., 30: 370–381.
8. Bajter HH, Mickey BE, Samson DS (1987) Enlargement and rupture of distal basilar aneurysms following iatrogenic carotid occlusion, Neurosurgery, 20: 624–628.
9. Batjer HH, Samson DS (1989) Causes of morbidity and mortality from surgery of aneurysms of distal basilar artery, Neurosurgery, 25: 904–916.
10. Day JD, Fukushima T, Giannotta SL (1994) Microanatomical study of the extradural middle fossa approach to the petroclival and posterior cavernous sinus region. Description of the rhomboid construct, Neurosurgery, 34: 1009–1016.
11. Day JD, Giannotta SL, Fukushima T (1994) Extradural temporopolar approach to lesions of the upper basilar artery and infrachiasmatic region, J Neurosurg, 81: 230–235.
12. Day DJ, Takanori F, Giannotta SL (1997) Cranial base approaches to posterior circulation aneurysms, J Neurosurg, 87: 44–554.
13. Dolenc VV (1989) Anatomy and surgery of the cavernous sinus, Vienna, Springer-Verlag, 171–195.
14. Kawase T, Shiobara R, Toya S (1991) Anterior transpetrosal-transtentorial approaches for sphenopetro-clival meningiomas: surgical method and results in 10 patients, Neurosurgery, 28: 869–876.
15. Kawase T,Toya S i wsp. (1985) Transpetrosal approach for aneurysms of the lower basilar artery, J Neurosurg, 63: 857–867.
16. Lang J (1994) Skull base and related structures. Atlas of clinical anatomy. Schattauer, Stuttgart.
17. Słoniewski P, Zieliński P, Nosowicz J (1998) Some technical tips for the cranio-orbital zygomatic approach, Skull Base Surg., 8, Suppl. 35: 230.