

Analysis of operating field area in transpyramidal retrolabyrinthine approach to posterior cranial fossa

Stanisław Nitek¹, Jarosław Wysocki¹, Eliza Brożek²

¹Department of Normal Anatomy, Medical University of Warsaw, Poland

²Department of Paediatric Otorhinolaryngology, Medical University of Warsaw, Poland

[Received 23 September 2002; Revised 21 October 2002; Accepted 21 October 2002]

Retrolabyrinthine surgical access to the posterior and middle cranial fossa has a long history of use during the procedures aiming at the removal of small neoplastic changes located in the area of the internal auditory tube. A precise knowledge of the anatomical alterations of the temporal bone in the aspect of the retrolabyrinthine access to the posterior cranial fossa determines a successful otoneurosurgical endoscopy, which involves a relatively narrow area. Forty-four cadaver temporal bones of both sexes were measured to obtain the dimensions of the surgical area limited by the sigmoid sinus, superior petrosal sinus and posterior labyrinth. The techniques of computer picture analysis were applied in the research. The mean value of the surface area of the figure limited by the sigmoid sinus, superior petrosal sinus and posterior semicircular canal was 175.9 mm² with no significant differences between sexes and sides. The maximal measured value was 356 mm², and the minimal was 84.3 mm². The size of the surgical area is characterised by large deviation range but was always sufficient to insert the endoscopic device and standard otosurgical instruments.

key words: otosurgery, retrolabyrinthine approach, sigmoid sinus, labyrinth, superior petrosal sinus, temporal bone

INTRODUCTION

The knowledge of the deviations in the topography of the anatomic structures situated on the posterior surface of the temporal bone pyramid is significantly important in endoscopic surgery of the posterior cranial fossa. These structures are: anteriorly — the posterior labyrinth block (posterior semicircular canal), superiorly — the superior edge of the pyramid with superior petrosal sinus, and posteriorly — the sigmoid sinus. All the above constitute the classical limitations of the Trautmann triangle [2]. The mean value of the Trautmann triangle surface area according to Prott [11] is approx. 1 cm². Oppel and Mulch [10] attained similar results, approx. 1.2 × 0.8 cm

on average. The retrolabyrinthine access to the posterior cranial fossa aiming at surgical decompression in the severe cases of otogenic meningitis was already described by Barany in 1912 [1], by Holmgren in 1914 [1], by Zollner in 1944 [1], Link, Moser, Mundnich in 1950 [1], by Blohmke and Link in 1954 [1] and Ehrenberger et al. in 1976 [5]. In 1972 [7] and 1977 [12] Hitselberger and Pulec presented the selective retrolabyrinthine trigeminal nerve neurotomy also through the Trautmann triangle, previously usually executed through the infraoccipital approach. The possibilities exploiting the retrolabyrinthine endoscopy through the opened Trautmann triangle were investigated by Prott [11] and Oppel with Mulch

[10]. The retrolabyrinthine approach also allows decompression of the endolymphatic sac [8, 13] and the vestibular nerve neurectomy [9] in surgical treatment of Meniere disease.

The use of the retrolabyrinthine approach when removing the posterior cranial fossa tumours or in the surgical treatment of vasculo-neural conflict was also described by other authors [3, 14].

MATERIAL AND METHODS

Forty-four fixed human temporal bones were used in the research (28 male and 16 female bones, age 11 to 85, 10 left sides, 34 right sides). They were prepared under a surgical microscope with the use of a dental fraise. The posterior semicircular canal was open at full length on the posterior pyramid surface. The bones prepared in this way, with a millimetre scale, were placed under the optics in such a way as to put the area limited by the posterior semicircular canal, sigmoid sinus, bulb of interior jugular vein, and superior petrosal sinus (SPC figure) perpendicularly to the optic axis on the side of the posterior cranial fossa (Fig. 1).

Subsequently, the image underwent computer image analysis by means of the Multiscan program. After previous graduation, the SPC figure borders were encircled manually (always by the same person) and the surface area and periphery were measured. Additionally the maximal length and width were automatically given. Attained results underwent statistical analysis regarding sex and age (t Student test).

RESULTS

Mean SPC surface area value was 183.1 mm² for men and 163.2 mm² for women but the difference was not statistically significant. The area of the measured figure was between 84.3 mm² and 356 mm². The periphery of the SPC figure was approx. 70 mm. The maximal length and width were usually close to each other and measured 22 and 16 mm respectively. There was no correlation observed either with sex or with age. The results regarding sex and side are presented in Table 1.

Of a great meaning for the size of the SPC figure area was the high localisation of the jugular fossa

Table 1. The SPC measurements regarding sex and side (all diameters are in mm or mm²)

Feature Body side	Men		Women	
	Left	Right	Left	Right
Surface area	210.1	171.5	154.8	168.2
	183.14 (84.3–356.8)		163.20 (108.8–290.1)	
Periphery	69.1	68.7	65.1	74.9
	71.22 (55.3–98.1)		69.39 (46–100.7)	
Length	22.2	21.4	21.3	23.3
	22.29 (17–28)		22.56 (15–35)	
Width	17.5	15.9	14.1	16.7
	16.74 (13–24.8)		15.5 (11.7–21.1)	

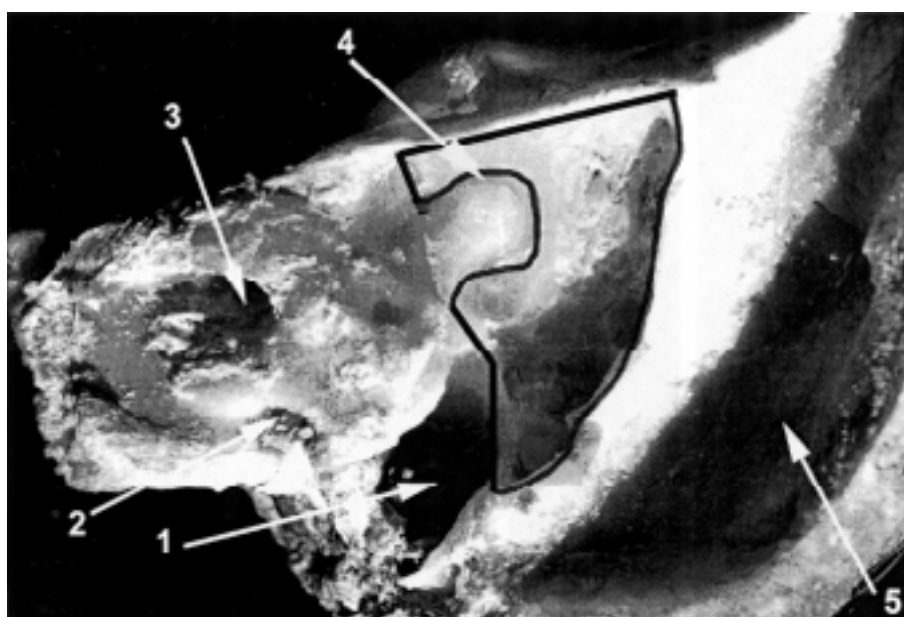


Figure 1. Posterior wall of the temporal bone pyramid with opened posterior semicircular canal (the SPC figure was encircled); 1 — jugular fossa, 2 — orifice of the cochlear canaliculus, 3 — internal acoustic meatus, 4 — posterior semicircular canal, 5 — sigmoid sinus.

and, probably, coexistence of the sigmoid sinus. This condition was found in four cases, which is 10% of the studied material. Localisation of both superior petrosal sinus and posterior semicircular canal did not affect the SPC figure area.

DISCUSSION

The available literature contains little information on the anatomy of retrolabyrinthine approach to the posterior cranial fossa. Among the information it is worth mentioning Prott's study [11], and Oppel and Mulch's study [10]. Mean surface area value of the Trautmann triangle given in both works was approx. 1 cm². In this work the SPC figure surface area enclosed by the posterior semicircular canal, sigmoid sinus and superior petrosal sinus, which corresponds with the Trautmann triangle, was approx. 1.83 cm² for men, and 1.63 cm² for women (the difference being statistically insignificant), which is comparable with the data in other research. It is worth underlining that the area of the measured figure was limited inferiorly by the jugular fossa, because the three structures mentioned above do not form a circle periphery. Here, the SPC figure was usually more like a regular tetragon. There was observed a great variability in size and shape of the measured SPC figure area. This was mainly due to a large diversity of the sigmoid sinus course and the jugular fossa depth and to a lesser extent to the anatomical diversity of the superior petrosal sinus and posterior labyrinth. Mayer defines a protruding sigmoid sinus, which complicates surgical conditions, and is located less than 12 mm away from the posterior wall of the external meatus (Ukleja after Mayer; 1960) [15]. According to the above criteria, Ukleja recorded protruding sinus in 30% of examined material. However, Wysocki [16] argues with the above results and with the definition of the protruding sinus. On the basis of anatomic research he stated that the sigmoid sinus occurs 13 mm on an average from the external auditory tube. Such big differences are probably connected with more precise preparation of the sigmoid sinus wall in the anatomic research than in measurements performed by Ukleja during the surgery (lesser accuracy). Different authors mention that a protruding sinus occurs more frequently on the right side (Ukleja after Koerner) [6, 15]. The sigmoid sinus penetrates the mastoid process of the brachycephal skull to the greatest extent (Ukleja according to Bezold and Koerner; 1960) [15]. Of a practical meaning may be a statement concerning the relation between the magnitude of the suprameatal

spine and the sigmoid sinus location — when the suprameatal spine is poorly seen, then the sigmoid sinus occurs more often [15]. The sigmoid sinus course can be approximately determined basing on the line joining the asterion and the mastoid process apex [4]. The asterion (the junction of the parietomastoid, occipitomastoid and lambdoid sutures) is a helpful landmark in estimating the junction of the transverse and sigmoid sinuses. The scalp at the asterion is the site of the slight depression that can be palpated through the skin. The asterion is located indirectly lower than the upper border of the transverse-sigmoid sinus junction.

On the basis of the performed studies and available literature it can be stated that the dimensions of the area located between the sigmoid sinus, superior petrosal sinus and posterior labyrinth seem to be sufficient for an otosurgical approach, especially with the use of endoscopic methods. It is possible even if this area is extremely small. The impaired anatomic conditions occur in approx. 25% due to the incidence of the protruding sigmoid sinus and deep jugular fossa. These structures happen to occur statistically more frequently on the right side and such bones are described as "dangerous temporal bones" [6]. The retrolabyrinthine approach is technically difficult, time-consuming and requires precise anatomic knowledge with very well developed technical abilities in fraising the temporal bone. However, its advantage is a significantly less traumatic postoperative course in comparison with patients operated from a typical neurosurgical approach. The attained data encourage us to continue and broaden the studies connected with the above topic.

REFERENCES

1. Blohmke A, Link R (1950) Die transmastoidale Cisternendrainage und ihre Bedeutung bei schwerer otogener Meningitis. *Arch Ohr- usw- Heilk*, 157.
2. Bochenek A, Reicher M (1989) *Anatomia człowieka*. Vol. V, ed. III, Warszawa, pp. 443–444.
3. Brackmann DE, Hitselberger WE (1978) Retrolabyrinthine approach, technique and newer indications. *The Laryngoscope*, 88: 286–297.
4. Day JD, Kellog JX, Tschabitscher M, Fukushima T (1996) Surface and Superficial Surgical Anatomy of the Posterolateral Cranial Base: Significance for Surgical Planning and Approach. *Neurosurgery*, 38 (6): 1079–1084.
5. Ehrenberger K, Innitzer J, Koos W (1976) Erfolgreiche Akustikusdekompression bei postarachnoiden Hirschaden. *Laryng Rhinol*, 55: 561–568.
6. Hadziselimovic H, Savkovic L, Bubic I (1961) How to determine a "dangerous temporal bone". *Acta Anat*, 44: 322–335.

7. Hitselberger W, Pulec J (1972) Trigeminal Nerve (Posterior Root) Retrolabyrinthine Selective Section. *Arch Otolaryng*, 96: 412–415.
8. House WF (1962) Subarachnoid shunt for drainage of endolymphatic hydrops. *Laryngoscope*, 72: 713–729.
9. House JW, Hitselberger WE, McElveen J, Brackmann DE (1984) Retrolabyrinthine section of the vestibular nerve. *Otolaryngol Head Neck Surg*, 92: 212–215.
10. Oppel F, Mulch G (1979) Selective Trigeminal Root Section via an Endoscopic Transpyramidal Retrolabyrinthine Approach. *Acta Neurochirurg*, suppl. 28: 565–571.
11. Prott W (1974) Möglichkeiten einer Endoskopie des Kleinhirnbrückenwinkels auf transpyramidalem-retrolabyrintharem Zugangsweg-Cisternoskopie. *HNO*, 22: 337–341.
12. Pulec J, Hitselberger W (1977) Trigeminal Neuralgia: Retrolabyrinthine Selective Posterior Root Section. *Laryngoscope*, 87: 1861–1869.
13. Shambaugh GE (1966): Surgery of the Endolymphatic Sac; *Arch Otolaryng*, 83: 29–39.
14. Silverstein H, Norell H (1980) Retrolabyrinthine surgery: A direct approach to the cerebellopontine angle. *Otolaryngol Head Neck Surg*, 88: 462–469.
15. Ukleja Z (1966) Wielkość kolca nadprzewodowego a położenie zatoki esowatej. *Otolaryngol Pol*, 14 (1): 81–83.
16. Wysocki J (1998) Zależności pomiędzy topografią ważnych struktur kości skroniowej a położeniem zatoki esowatej. *Otolaryngol Pol*, 52, 4: 463–466.