

The foetal development of the human osseous labyrinth in a computed tomographic study

Leszek Porowski¹, Antoni Radziemski¹, Adam Piotrowski¹, Agnieszka Skórzewska², Witold Woźniak¹

¹Department of Anatomy, University of Medical Sciences, Poznań, Poland

²Laboratory of Gynaecological-Obsterical Radiology, University of Medical Sciences, Poznań, Poland

[Received 9 June 2003; Accepted 30 June 2003]

A CT study was performed on 8 fetuses aged between 20 and 38 weeks. In fetuses at the 20th week the semicircular canals, the spiral canal of the cochlea and the initial (labyrinthine) part of the facial canal are visible. At week 24 the tympanic part of the facial canal is observed. In the 31st week the cochlea is divided into 2 compartments, and in the 38th week the vestibular aqueduct and osseous labyrinth are seen.

key words: human labyrinth, development, CT

INTRODUCTION

The conventional postero-anterior projection of the developing osseous labyrinth is not precise in radiological investigations due to the overlapping of the cranial bones on the middle and posterior cranial fossae. Computed tomography permits detailed visualisation in intact material of structures which are small or deeply set [4, 5, 7]. In such studies the osseous labyrinth, parts of the facial canal and the tympanic cavity with auditory ossicles can be well documented [1, 2, 4].

MATERIAL AND METHODS

Computed tomography of the posterior cranial fossa was applied in 8 fetuses aged between 20 and 38 weeks. The fetuses were from the collection of the Department of Anatomy, Poznań. The study was made in the CT Laboratory for Regional Lung Disease, Poznań. Picker CY PO 2000 Apparatus was used to scan the specimens in 1mm thick sections.

RESULTS

In the foetus in the 20th week the semicircular canals and the spiral canal of the cochlea are seen on serial cross-sections through the pyramid of the temporal bone (Fig. 1). On the posterior surface of

the pyramid a wide internal acoustic meatus is evident. Posteriorly to the spiral canal of the cochlea a narrow space corresponding to the vestibulum is observed. Between this space and the cochlea there is a fissure which is an initial (labyrinthine) part of the facial canal (Fig. 2).

At week 24 anteriorly to the lateral semicircular canal and between this and the tympanic cavity there is a narrow space forming the tympanic part of the facial canal (Fig. 3).

In the foetus aged 31 weeks there is a distinct, thin spiral osseous lamina inside the spiral canal of the cochlea arising from the base of the modiolus and dividing the spiral canal into the scala tympani and the scala vestibuli (Fig. 4).

In the foetus in the 38th week the internal aperture of the vestibular aqueduct is visible as a narrow opening on the posterior surface of the pyramid laterally to the internal acoustic meatus. Within the osseous labyrinth this aqueduct passes anteriorly to the anterior semicircular canal towards the vestibule. The vestibular aqueduct extends from the vestibule to the subdural space and terminates in the external aperture of the vestibular aqueduct on the posterior surface of the pyramid. At this time all structures of the osseous labyrinth are evident.

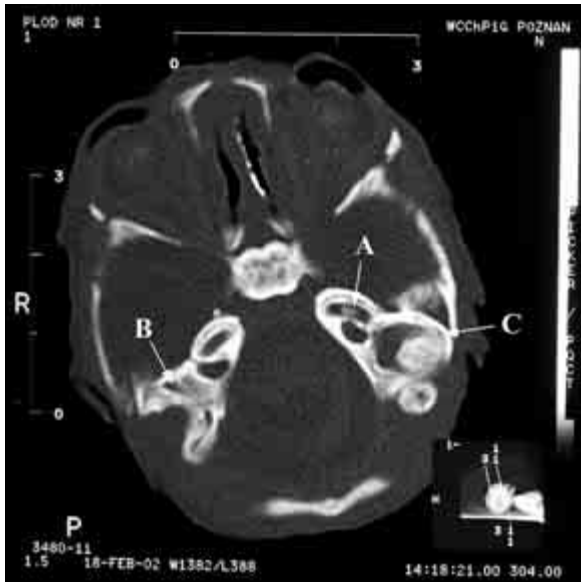


Figure 1. Foetus aged 20 weeks; A — spiral canal of cochlea, anterior (B) and posterior (C) semicircular canals.

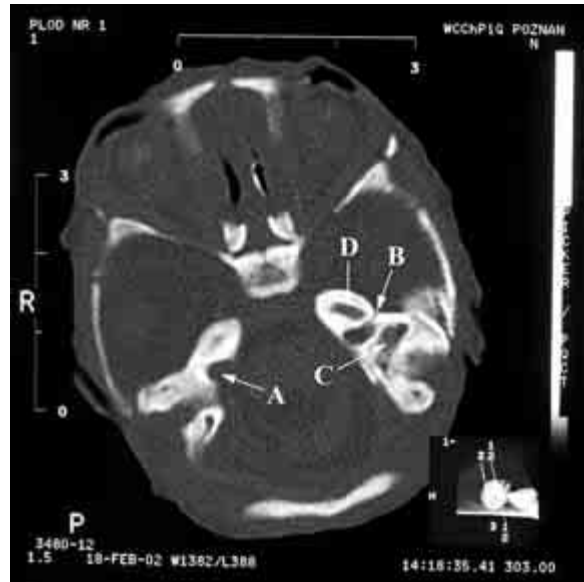

Figure 2. Foetus aged 20 weeks; A — internal acoustic meatus, B — initial part of facial canal between vestibule (C) and cochlea (D).

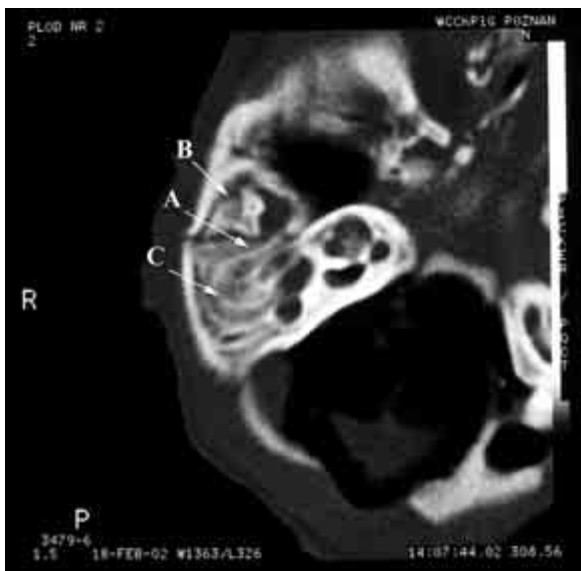


Figure 3. Foetus aged 24 weeks; A — tympanic part of facial canal, B — tympanic cavity, C — semicircular ducts.

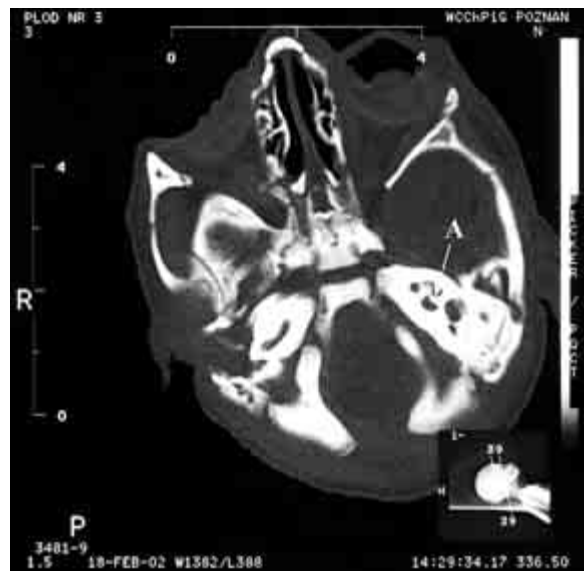

Figure 4. Foetus aged 31 weeks; A — spiral osseous lamina.

DISCUSSION

Arnold and Lang [1], applying 3D computed tomography, described the osseous labyrinth in 10-week-old foetuses. Nemzek et al. [3] noted that the cochlea, vestibule and lateral semicircular canal were not ossified in the foetus in the 21st week. Spector and Ge [6] observed the beginning of ossification in the facial canal in a foetus aged 21 weeks. In the present study it was shown that the various parts of the facial canal

ossify at different periods. All the components and compartments of the osseous labyrinth are clearly evident by the 38th week.

REFERENCES

1. Arnold WA, Lang T (2001) Development of membranous labyrinth of human embryos and fetuses using computer aided 3D reconstruction. *Ann Anat*, 183: 61–66.
2. Eby TL, Nadol JB (1986) Postnatal growth of the human temporal bone. Implications for cochlear implants in children. *Ann Otol Rhinol Laryngol*, 95: 356–364.

3. Nemzek WR, Brodie HA, Chong BW, Babcock CJ, Hecht ST, Salamat S, Ellis WG, Seibert JA (1996) Imaging findings of the developing temporal bone in fetal specimens. *Am J Neuroradiol*, 17: 1467–1477.
4. Porowski L, Skórzewska A, Radziemski A, Szpakowska-Rzyska I (1999) Development of frontal sinus in human fetuses as seen in computerized tomography. *Folia Morphol*, 58: 61-67.
5. Rzymiski K, Porowski L, Radziemski A, Skórzewska A, Szpakowska-Rzyska I (1999) Application of computed tomography in studies on development of human paranasal sinuses in the early postnatal period. *Folia Morphol*, 58: 43-51.
6. Spector JG, Ge X (1993) Ossification patterns of the tympanic facial canal in the human fetus and neonate. *Laryngoscope*, 103: 1052–1065.
7. Virapongse C, Sarwar M, Bhimani S, Sasaki C, Shapiro R (1985) Computed tomography of temporal bone pneumatization: 1. Normal pattern and morphology. *Am J Radiol*, 145: 473–481.