

# Activity of the thyroid parafollicular (C) cells in simple and hyperactive nodular goitre treated surgically — preliminary investigations

Jacek Dadan<sup>1</sup>, Robert Ł. Zbucki<sup>2</sup>, Bogusław Sawicki<sup>3</sup>, Maria M. Winnicka<sup>2</sup>, Zbigniew Puchalski<sup>1</sup>

<sup>1</sup>1<sup>st</sup> Department of General and Endocrinological Surgery, Medical University, Białystok, Poland

<sup>2</sup>Department of General and Experimental Pathology, Medical University, Białystok, Poland

<sup>3</sup>Department of Histology and Embryology, Medical University, Białystok, Poland

[Received 13 June 2003; Revised 24 July 2003; Accepted 24 July 2003]

*The aim of this study was to evaluate the significance of measuring calcitonin (CT) plasma concentrations in patients with simple and hyperthyroid goitre treated surgically. Eighty four patients who underwent operations during the years 2000–2002 were analysed. Plasma concentrations of CT were determined by commercially available radioimmunoassay on the day of hospitalisation. Elevated concentrations of CT were found in 8 patients: in 5 out of 26 (19.2%) and in 3 out of 33 (9.0%) patients with Graves' disease and with multinodular goitre, respectively. No major differences in concentrations of CT were observed in patients with simple goitre. Postoperative morphological analysis of pathologically changed hyperactive thyroids showed the presence of enlarged C cells distributed either in small groups or even singly with weakening immunohistochemical reaction for CT. These observations may point to the possibility of a relationship between the functional state of the thyroid gland and the activity of C cells.*

**key words:** C cells, calcitonin, hyperthyroidism, nodular goitre

## INTRODUCTION

Parafollicular (C) cells belong to the APUD system. These cells are the source of regulatory peptides [6] and their secretory activity depends on many factors such as age, sex and state of health [1, 4]. The basic indicator of C-cell activity is the 32-aminoacid hormone — calcitonin (CT). The main function of CT is diminution of the concentration of calcium ions by inhibition of the resorption activity of osteoclasts and by the facilitation of calcium ion secretion in the kidneys [4]. Normal plasma concentration of CT ranges from 0 to 10 pg/ml [7]. The measurement of CT concentration is a useful biochemical indicator of thyroid diseases, particu-

larly in the diagnosis of medullary thyroid carcinoma [4]. It has also been reported that in patients with basic or stimulated pentagastrin, a concentration of CT higher than 100 pg/ml increases the risk of C-cell hyperplasia and even transformation of these cells into carcinoma cells [7]. Moreover, the possible coexistence of Graves' disease, C-cell hypertrophy and even medullary thyroid carcinoma, characterised by an increase in basic and stimulated CT plasma concentration, was indicated. [8]. The aim of this study was to compare CT-immunoreactivity in C cells and CT plasma concentrations in patients with simple and hyperthyroid goitre treated surgically.

**Table 1.** Calcitonin (CT) plasma concentrations (pg/ml) in 8 hyperthyroid patients, with CT elevation above the normal value (0–10 pg/ml)

No. of patient	Sex	Age	CT before operation	CT 4 days after operation	CT 30 days after operation
1 HG	M	43	15.3	8.9	23.2
2 HG	F	31	23.8	12.9	10.7
3 HG	F	38	18.4	12.9	8.9
4 GG	F	26	55.2	22.1	37.2
5 GG	F	31	58.6	16.6	12
6 GG	F	42	46.1	12.6	24.6
7 GG	F	27	61.2	11.9	41.5
8 GG	M	33	44.8	22.9	32.4

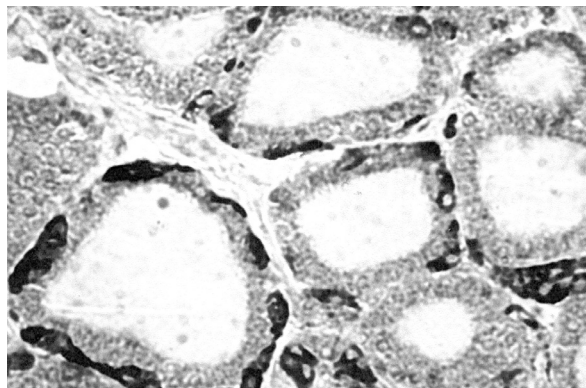
HG — hyperthyroid nodular goitre, GG — Graves' goitre

## MATERIAL AND METHODS

Eighty four patients, with simple and hyperthyroid goitre, operated on in the 1<sup>st</sup> Department of General and Endocrinological Surgery between the years 2000–2002, were analysed. The preoperative diagnosis included evaluation of clinical state and the plasma level of the thyroid hormones. Fine needle biopsy and cytological examinations were performed in all patients to establish the functional state of the gland and to exclude the possibility of cancer. Twenty six patients were operated on due to Graves' disease, 33 due to multinodular hyperactive goitre and the remaining 25 patients due to simple goitre. Before each operation, in an attempt to obtain euthyroidism, patients were given propranolol, at an average dose of  $3 \times 20$  mg over 7 days. Plasma CT concentration was determined by the radioimmunological method on the first day of hospitalisation (Table 1). Most of the patients underwent subtotal thyroidectomy. Total thyroidectomy was performed in 7 patients with Graves' disease. After the operation a histopathological and immunohistochemical examination was performed, as described in detail previously [2, 3], of the removed thyroid gland.

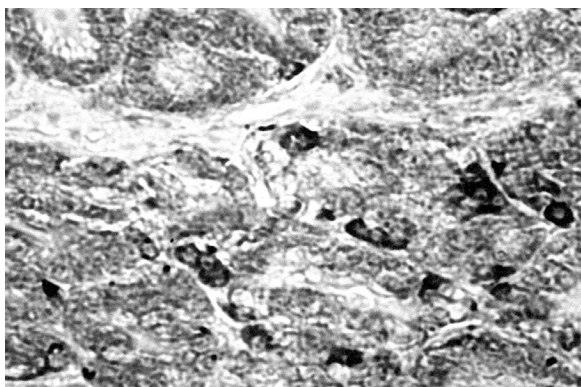
## RESULTS AND DISCUSSION

Elevation of CT plasma concentration before the operation was observed in 8 patients with hyperthyroidism: in 5 out of 26 (19.2%) patients with Graves' disease and in 3 out of 33 (9.0%) patients with hyperactive multinodular goitre. In patients with a simple goitre the concentration of CT was within the normal range (Fig. 1).



**Figure 1.** Light micrograph of the thyroid of a patient operated on due to simple nodular goitre. A positive immunohistochemical reaction is seen for CT in C cells distributed singly or in small groups;  $\times 300$ .

In the postoperative morphological examination of the removed hyperactive thyroid glands signs of hyperplasia of the follicles in the nodules was observed, especially intense in the cases of Graves' disease. Moreover, in the same gland nodules consisting of follicles with high, as well as with a very low epithelium, were present. The immunohistochemical examination of C cells showed the presence of enlarged C cells distributed irregularly in small groups or even singly, in unchanged parts of the glands (Fig. 2). The absence of C cells inside the nodules may reflect their displacement to the parts of the glands which possess normal structure. The immunohistochemical reaction for CT was much weaker in a hyperactive goitre than in a simple one. An elevated CT plasma level was also observed in 7 of the 45 hyperthyroid patients studied by Gozariu et al. [5]. In recently published



**Figure 2.** Light micrograph of the thyroid of a patient operated on due to hyperactive nodular goitre. A weaker immunohistochemical reaction is seen for CT in enlarged C cells with signs of hyperplasia;  $\times 300$ .

data [8], in spite of the high prevalence of thyroid C-cell hyperplasia in patients with Graves' disease, an elevated CT plasma level was observed in only 4 out of 161 patients with manifest hyperthyroidism. However, an elevation of CT plasma concentrations was observed in our study in patients with hyperactive nodular goitre, especially in cases of Graves' disease, together with a weak immunoreactivity for CT within C cells, indicating an increase in their secretion potential which may point to an enhancement of the hormonal activity of C cells during hyperactive nodular goitre. These preliminary observations confirm the hypothesis presented by Zabel et al. [9] concerning the functional relationship between parafollicular and follicular cells within the thyroid gland.

## REFERENCES

1. Azzadin A, Kasacka I, Sawicki B, Dadan J, Malla H, Buczek W (2001) Preliminary evaluation of thyroid C cells in rats with chronic renal failure. *Folia Histochem Cytobiol*, 39: 203–204.
2. Dadan J, Ładny JR, Puchalski Z (1997) Hyperthyroid goitre treated surgically. *Roczniki Akademii Medycznej w Białymstoku*, 42: 81–88.
3. Dadan J, Sawicki B, Chyczewski L, Azzadin A, Malla H, Dziecioł J, Puchalski Z (2001) Preliminary immunohistochemical investigations of human thyroid C cells in the simple and hyperactive nodular goitre. *Folia Histochem Cytobiol*, 39: 189–190.
4. Dadan J, Zbucki R (2003) Komórki C tarczycy i ich rola. *Post Biol Kom*, 30: 187–200.
5. Gozariu L, Duncea I, Florescu O, Popescu E, Dumitru E, Dascalu R (1982) Calcitonin secretion in hyperthyroidism. *Endocrinologie*, 20: 43–48.
6. Sawicki B, Czykier E, Kasacka I, Kasprzak A, Zabel M (2002) Hybridocytochemical detection of mRNA for calcitonin, CGRP, NPY and somatostatin in thyroid parafollicular (C) cells in three rodent species. *Folia Histochem Cytobiol*, 40: 89–90.
7. Scheuba C, Kaserer K, Kotzmann H, Bieglmayer C, Niederle B, Vierhapper H (2000) Prevalence of C-cell hyperplasia in patients with normal basal and pentagastrin-stimulated calcitonin. *Thyroid*, 10: 413–416.
8. Vierhapper H, Nowotny P, Bieglmayer C, Gessi (2002) A prevalence of hypergastrinemia in patients with hyper- and hypothyroidism: Impact for calcitonin? *Horm Res*, 57: 85–89.
9. Zabel M, Dietel M, Gębarowska E, Michael R (1999) Effect of follicular cells on calcitonin gene expression in thyroid parafollicular cells in cell culture. *Histochem J*, 31: 175–180.