VIA MEDICA

ORIGINAL ARTICLE

Folia Morphol.
Vol. 62, No. 4, pp. 323–325

ISSN 0015–5659
www.fm.viamedica.pl

The morphology and morphometry of the so-called "meningo-orbital foramen" in humans

Jan Kwiatkowski[1], Jarosław Wysocki[2], Stanisław Nitek[2]

[1]*Department of Ophthalmology of Specialist Hospital, Radom, Poland*
[2]*Department of Normal Anatomy, Medical University, Warszawa, Poland*

[Received 9 June 2003; Revised 29 July 2003; Accepted 29 July 2003]

The so-called meningo-orbital foramen creates an additional link between the orbit and the cranial cavity. This bony canal, not always present in the human skull, contains a branch from the middle meningeal artery, providing an accessory blood supply to the orbit. This vessel, like the foramen, is characterised by great variability. Although older textbooks of basic anatomy suggested that it was a rare occurrence, some current data indicate a more frequent incidence of this foramen. These discrepancies were verified in our research. 92 orbits were studied on 46 macerated human skulls (25 male and 21 female). Although the incidence of the meningo-orbital foramen in the material as a whole was 28%, the foramen in female skulls was observed to be 40.5%, compared to 18% in male skulls. This difference was statistically significant. A double foramen was encountered in three orbits, and in one orbit there was a triple foramen. This means that in the material as a whole multiple foramina were observed in 4% of cases. Two measurements were taken to determine the localisation of the meningo-orbital foramen. The minimal distance between the supraorbital notch (or foramen) and the meningo-orbital foramen was 35.0 (28–44) mm. The minimal distance from the cross-point of the entrance to the orbit and the fronto-zygomatic suture was (21.3–35.5) mm. This indicates that the meningo-orbital foramen can lie near an operating field in some surgical interventions through the lateral orbital wall.

key words: orbit, anatomy, foramina, dimensions, variability

INTRODUCTION

The so-called meningo-orbital foramen is situated in the greater wing of the sphenoid bone close to the superior orbital fissure [3, 11]. This structure is not invariably present in human skulls, which is why it is not mentioned in "Nomina Anatomica". This foramen links the interior of the orbit with the middle cranial fossa and contains an arterial anastomose between the middle menigeal artery — the meningo-lacrimal branch and the lacrimal artery — the meningeal branch [1–3, 5, 7, 11]. In rare cases, in which some elements of the embryonic stapedial artery survive into adult life, some anatomical anomalies in this area can be observed [11]. One of these variants is the phenomenon of reciprocal replacement of the supply areas of the two aforementioned arteries, the lacrimal and the middle meningeal, through their anastomoses [6, 7, 11]. The first variant is observed where the lacrimal artery is a branch of the middle menigeal artery as the only one (17.14%) or as an accessory lacrimal artery (11.43%), coexisting with the main branch of the ophthalmic

Address for correspondence: Jarosław Wysocki, MD, PhD, DSci, Department of Normal Anatomy, Medical University, ul. Chałubińskiego 5, 02–004 Warszawa, Poland, tel: +48 22 629 52 83, e-mail: j.wysocki@ifps.org.pl

artery. In the second variant, observed in about 1.5% of the population, the ophthalmic artery is a substitute for the middle meningeal artery by means of a branch entering the skull cavity through the meningo-orbital foramen or through the superior ophtalmic fissure [1, 2, 5, 11, 14]. In these cases the spinal foramen of the sphenoid bone is absent [7, 11, 14].

The meningo-orbital foramen or, better, canal, is known in anatomical literature under several names: the lacrimal foramen, the cranio-orbital foramen, Hyrtl's canal and the spheno-frontal foramen [3, 5, 7, 10, 12]. Its occurrence, in the differing opinions of several authors, ranges from 6% to 49% [7, 12, 13, 16]. The meningo-orbital foramen is, in a considerable number of cases (3–15%), double, which is the normal form in primate mammals [4, 7, 13, 16]. Very seldom the meningo-orbital foramen is observed joined to the superior orbital fissure [7]. The localisation of the meningo-orbital foramen and its distance from the superior orbital fissure has clinical importance. Injuries to the arterial branch coming through the foramen during operations on the orbit makes surgical interventions longer and augments the operating risk, especially for the structures of the superior orbital fissure [7]. Analysis of the variability of the meningo-orbital foramen morphology and the distances between its orbital opening and selected topographical points can be of significance for clinical applications and was a main aim of this study.

MATERIAL AND METHODS

92 orbits were investigated on 46 macerated human skulls (25 male and 21 females). All the skulls were obtained from collection of The Institute of Archeology of Warsaw University and represented the Polish population from XII and XIII centuries from Kielce, Poland and its vicinity. Male and female skulls were differentiated on the basis of their main morphological features. After determining the sex of the skull, the meningo-orbital foramina were investigated. Only those foramina which were patent were taken into account and included into the study. Their morphology was studied and the minimal distances then measured. The first was the minimal distance from the meningo-orbital foramen to the supraorbital notch (or foramen). The second parameter was the minimal distance between the meningo-orbital foramen and the reference point, located on the entrance to the orbit and on the fronto-zygomatic suture. The two measurements were made with use of a gauge with a minimal scale of 0.1 mm.

RESULTS

The meningo-orbital foramen was present in 28% of the orbits studied and in 6 skulls was present bilaterally. In female skulls the foramen was observed in 40% (17 orbits, including 5 skulls in which they were observed bilaterally). In male skulls the foramen was encountered in only 20.6% of skulls (in 7 orbits, including 1 skull in which they occurred bilaterally). This difference was statistically significant. A double meningo-orbital foramen was present on 3 orbits, and a triple one in one orbit (Fig. 1, 2). In total this was a 4.3% occurrence of multiple foramina for all the orbits studied. The multiple foramina were observed in female skulls only.

The results of the measurements of the minimal distances between the meningo-orbital foramen and two selected reference points are displayed in the Table 1. These values showed no statistically significant differences in relation either to sex or to the side of the skull measured.

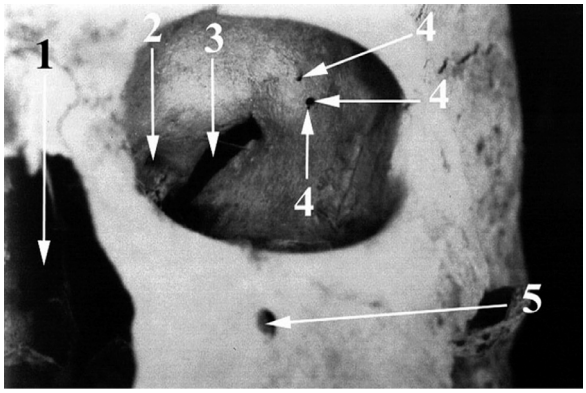

Figure 1. Triple meningo-orbital foramen; 1 — piriform aperture, 2 — optic canal, 3 — superior orbital fissure, 4 — meningo-orbital foramina, 5 — infraorbital foramen.

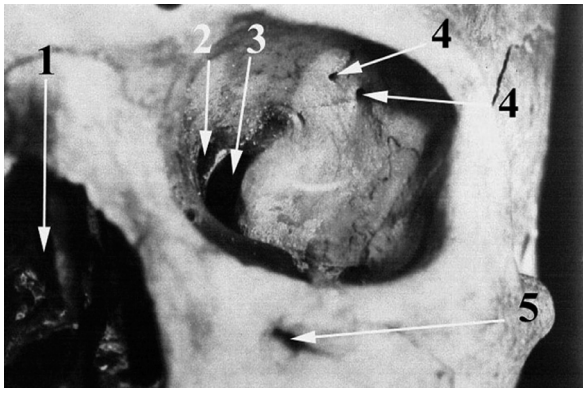

Figure 2. Double meningo-orbital foramen; 1 — piriform aperture, 2 — optic canal, 3 — superior orbital fissure, 4 — meningo-orbital foramina, 5 — infraorbital foramen.

Table 1. Minimal distances between the meningo-orbital foramen and selected reference points. Mean values, range and standard deviations (in parentheses) are displayed in millimetres

Minimal distance from meningo-orbital foramen to	All skulls		Female skulls		Male skulls	
	L	R	L	R	L	R
The supraorbital notch or foramen	35.8 (3.1) 32–44	34.4 (2.82) 28–38	35.1 (2.42) 32–39	34.9 (1.89) 33–38	37.4 (4.16) 34–44	33.5 (4.2) 28–38
A reference point lying at the entrance to the orbit and on the fronto-zygomatic suture	26.87 (3.2) 22–34	25 (3.87) 21.3–35.5	25.85 (3.21) 22–34	24.56 (1.69) 22–26.9	29.1 (1.88) 26–31	25.8 (6.54) 21.3–35.5

DISCUSSION

The results obtained indicate a considerably greater rate of occurrence of the foramen than is recognised in standard anatomy textbooks [3, 11]. The present data are comparable and close to the findings of other authors [7, 12, 13, 16]. The real novelty is the significant difference between male and female specimens regarding the occurrence of the foramen. This should be singled out, particular attention being drawn to the fact that both the occurrence and morphology of the meningo-orbital foramina presented significant sex differences in humans. However, there has been no mention of this in the available literature, most authors not having included sex differences in their investigations. The incidence of double foramina is in accord with Diamond's observations, although this author did not observe any triple foramen [5]. The results of the measurements of the minimal distances between the meningo-orbital foramen and the two selected reference points are comparable with those of other authors [12, 15]. These distances and their ranges do not exceed the values presented by other authors, excluding the value of 12 mm for the distance from the reference point on the entrance to the orbit in Rontal's publication [15]. It is possible that Rontal's material included an infant or a deformed skull. Our data for other parameters indicating the depth of the orbit are also comparable with those obtained by other authors [8, 9].

CONCLUSIONS

1. The meningo-orbital foramen occurs frequently in Polish skulls.
2. In female skulls the occurrence of the meningo-orbital foramen is significantly greater than in male skulls.

REFERENCES

1. Adachi B (1928) Das Arteriensystem der japaner. Vol. 1. Maruzen, Kyoto.
2. Bergman RA, Thompson AK, Afifi AK, Saadeh FA (1988) Compendium of human anatomic variation. Urban&Schwarzenberg, Baltimore.
3. Bochenek A, Reicher M (1993) Anatomia człowieka. Vol. III, PZWL, Warszawa.
4. Diamond MK (1988) Cephalic Vascular Evolution and Development in Primates: The Stapedial Artery and its Companion Venous Sinuses. Ph.D. dissertation, University of Chicago. Ann Arbor: University Microfilms.
5. Diamond MK (1991) Homologies of the meningeal--orbital arteries of humans: a reappraisal. J Anat, 178: 223–241.
6. Ducasse A, Segal A, Delattre JF, Burette A, Flament JB (1985) Participation of the external carotid artery in orbital vascularization. J Fr Ophtalmol, 8: 333–339.
7. Georgiou C, Cassell MD (1992) The foramen meningo-orbitale and its relationship to the development of the ophthalmic artery. J Anat, 180 (Pt 1): 119–125.
8. Hwang K, Baik SH (1999) Surgical anatomy of the orbit of Korean adults. J Craniofac Surg, 10: 129–134.
9. Karakas P, Bozkir MG, Ouz O (2002) Morphometric measurements from various reference points in the orbit of male Caucasians. Surg Radiol Anat, 24: 358–362.
10. Lanz T, Wachsmuth W (1979) Praktische Anatomie. Ein Lehr- und Hilfsbuch der anatomischen Grundlagen Ärztlichen Handelns. Vol. I, Thieme, Berlin.
11. Lasjaunias PL (1981) Craniofacial and upper cervical arteries. Functional, clinical, and angiographic aspects. Williams and Wilkins, Baltimore.
12. McQueen CT, Di Ruggiero DC, Campbell JP, Shockley WW (1995) Orbital osteology: a study of the surgical landmarks. Laryngoscope, 105: 783–788.
13. Mysorekar VR, Nandedkar AN (1967) The groove in the lateral wall of the human orbit. Am J Roentgenol Radium Ther Nucl Med, 101: 814–827.
14. Pretterklieber ML, Krammer EB (1996) Sphenoidal artery, ramus orbitalis persistens and pterygospinosus muscle-a unique cooccurrence of first branchial arch anomalies in man. Acta Anat (Basel), 155: 136–144.
15. Rontal E, Rontal M, Guilford FT (1979) Surgical anatomy of the orbit. Ann Otol Rhinol Laryngol, 88: 382–386.
16. Santo Neto H, Penteado CV, de Carvalho VC (1984) Presence of a groove in the lateral wall of the human orbit. J Anat, 138: 631–633.