

# Proliferation and apoptosis in the guinea pig adrenal cortex during postnatal development

Dariusz Kaczmarczyk<sup>1</sup>, Bogumił L. Kmiec<sup>1</sup>, Małgorzata Daczewska<sup>2</sup>, Krzysztof B. Kmiec<sup>1</sup>

<sup>1</sup>Department of Cytophysiology, Histology and Embryology, Medical University, Łódź, Poland

<sup>2</sup>Zoological Institute, Laboratory of the Evolutionary and Developmental Biology of Vertebrates, University of Wrocław, Poland

[Received 1 September 2003; Revised 14 June 2004; Accepted 14 June 2004]

*The aim of the study was to determine the relation between involution of the FZ and the proliferation and apoptosis of the adrenal cortex cells.*

*The study was carried out with adrenal glands from guinea pigs aged 1, 3, 9, 14, 21, 35 and 90 days. Paraffin slices were stained with Mayer haematoxylin and eosin and with acid fuchsin. For the immunohistochemical reaction the Anti-PCNA Clone PC10 (Dako) was used. Apoptosis evaluation was performed with use of the TUNEL method (Roche).*

*The results support the theory of involution of the FZ cells realised mainly by way of apoptosis. Analysis of the distribution and number of PCNA-positive cells in the adrenal cortex on subsequent days of PD may also back up the migration theory of renewal of the adrenal cortex cells.*

**Key words:** adrenal gland, foetal zone, PCNA

## INTRODUCTION

On Day 1 of postnatal development (PD) the foetal zone (FZ) in humans and animals, including the guinea pig, constitutes the main mass of the adrenal gland [2–4]. Gradual involution of FZ starts even in the prenatal period [7], although the completion of this process extends throughout PD [2–4].

The aim of the study was to determine the relation between involution of FZ and the proliferation and apoptosis of the adrenal cortex cells.

## MATERIAL AND METHODS

The study was carried out with adrenal glands from 28 specimens aged 1, 3, 9, 14, 21, 35 and 90 days. Paraffin slices were stained with Mayer haematoxylin and eosin and with acid fuchsin. For the immunohistochemical reaction the Anti-PCNA Clone PC10 (Dako) was used. Apoptosis evaluation was performed with the use of TUNEL method with the

In Situ Cell Death Detection Kit, POD (Roche). All the stainings and immunohistochemical reactions were performed for serial slices of whole adrenal glands.

## RESULTS

In the adrenal glands of guinea pigs of 1 and 3 days old FZ consisted of 8–12 layers of fuchsinophilous cells (70–80% of all cortical cells) (Fig. 1). On PD9 6–8 layers (30–40%) were recorded, with 3–6 layers (5–10%) on PD14. On PD21 not more than 2 layers were observed (less than 5%). On PD35 single fuchsinophilous cells were found at the boundary of the cortex and medulla (Fig. 2). In 90-day-old, i.e. sexually mature animals no such cells were recorded.

A positive immunohistochemical reaction for apoptosis was observed on PD1 and PD3 in all layers of the cortex. In the medial part of the cortex, corresponding to FZ, the percentages of cells with a positive reaction for apoptosis ranged from 43% to 57%, while

Address for correspondence: Dariusz Kaczmarczyk Department of Cytophysiology, Histology and Embryology, Medical University, ul. Narutowicza 60, 90–136 Łódź, Poland, tel: +48 42 631 98 07, e-mail: kaczmard@csk.am.lodz.pl

The research was funded by the Medical University of Łódź, grant No. 502-11-775.

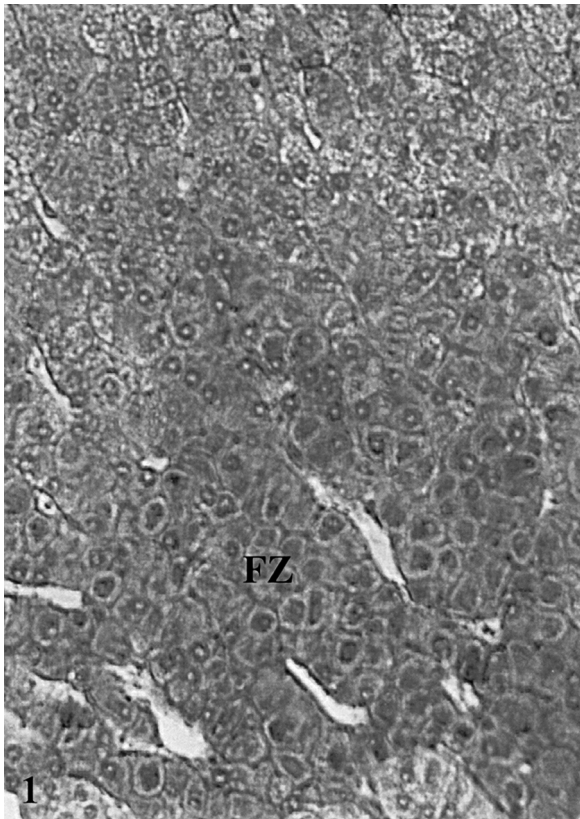


Figure 1. PD3 Foetal zone (FZ). Staining with acid fuchsin. Enl. 220 ×.

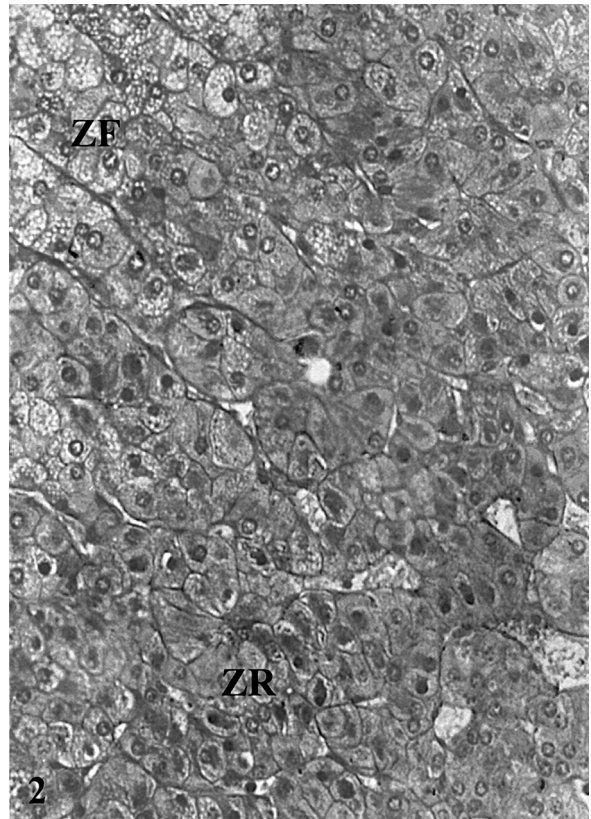


Figure 2. PD35 Zona fasciculata (ZF), zona reticularis (ZR). Staining with acid fuchsin. Enl. 220 ×.

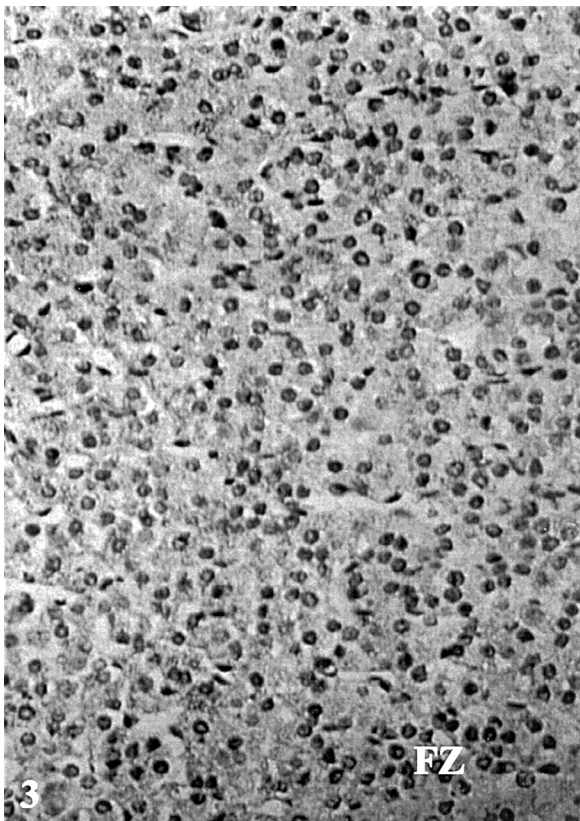


Figure 3. PD9. Foetal zone (FZ). TUNEL method. Enl. 220 ×.

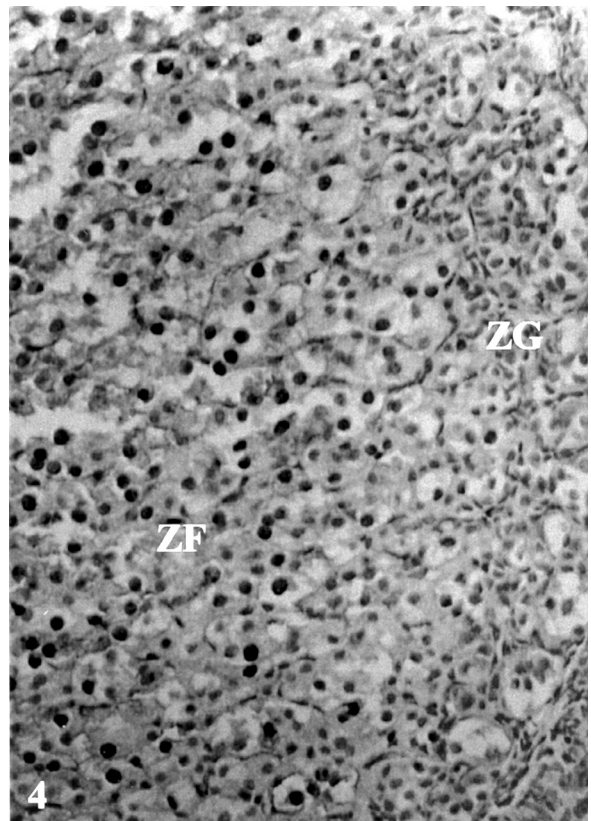


Figure 4. PD9. Zona fasciculata (ZF), zona glomerulosa (ZG). Anti-PCNA Clone PC10 reaction. Enl. 220 ×.

in the subcapsular part they ranged from 24% to 34%. On PD9 these percentages were 27–32% and 22–29%, respectively (Fig. 3). On PD21 the percentages of cells with a positive reaction for apoptosis were 22–25% and 21–25%, respectively, whereas on PD35, as on PD90 — 15–19% and 22–24%, respectively.

A positive immunohistochemical reaction for PCNA in the adrenal glands was observed on PD1 and PD3 in all layers of the cortex and related to 33–46% of cells. On PD9 and PD14 a PCNA-positive reaction was recorded in 35–49% of all cells (Fig. 4). On PD21 the percentage of PCNA-positive cells was 27–41%, and on PD35 and PD90 it stood at 17–33%. The highest proportion of PCNA-positive cells was observed in the zona fasciculata (ZF), especially in the part neighbouring the zona glomerulosa (ZG). However, single PCNA-positive cells were also found in the zona reticularis (ZR) and ZG.

## DISCUSSION

Apoptosis in the adrenal cortex during the postnatal development of the guinea pig is visible in all layers. Immunohistochemical reactions for this in the medial part, corresponding to FZ, in the first days after birth were recorded in a particularly high number of cells. This may support the theory of involution of FZ cells during PD mainly by way of apoptosis, as in other animals and in humans [1, 3, 7]. In view of the absence of the internal capsule, the theory of transformation of FZ cells into connective tissue cells is not supported by this study. The apoptosis recorded in all layers of the adrenal cortex in the guinea pig, both during PD and in sexually mature specimens, backs up the notion of involution of cells mainly by way of programmed death [8].

The analysis of the distribution and number of PCNA-positive cells in the adrenal cortex on subsequent days of PD and in sexually mature animals supports the migration theory, attested in the case of other animals and humans [5, 6]. The balance between proliferation and apoptosis is of crucial significance for an organism, not only during organogenesis, but also for its normal function throughout life, including development.

## REFERENCES

1. Blanco A, Monterde JG, Mendez A, Artacho-Perula E (2001) Stereological study of normal and apoptotic cell populations in the adrenal gland in calves. *Cell Tiss Org*, 169: 73–80.
2. Bocian-Sobkowska J (1999) Morphometric study of the human suprarenal gland in the first postnatal year. *Folia Morphol*, 58: 275–284.
3. Bocian-Sobkowska J, Woźniak W, Malendowicz LK (1998) Postnatal involution of the human adrenal fetal zone: stereologic description and apoptosis. *Endocr Res*, 24: 969–973.
4. Kaczmarczyk D, Kmieć BL (2002) Organogeneza nadnerczy świnki morskiej w okresie postnatalnym. *Ann Acad Med Lodz*, 43: 9–17.
5. Kataoka Y, Ikehara Y, Hattori T (1996) Cell proliferation and renewal of mouse adrenal cortex. *J Anat*, 188: 375–381.
6. Mitani F, Mukai K, Miyamoto H, Suematsu M, Ishimura Y (1999) Development of functional zonation in the rat adrenal cortex. *Endo*, 140: 3342–3353.
7. Spencer SJ, Mesiano S, Lee JY, Jaffe RB (1999) Proliferation and apoptosis in the human adrenal cortex during the fetal and perinatal periods: implications for growth and remodeling. *J Clin End Metabol*, 84: 1110–1115.
8. Wolkersdörfer GW, Ehrhart-Bornstein M, Brauer S, Marx C, Scherbaum WA, Bornstein SR (1996) Differential regulation of apoptosis in the normal human adrenal gland. *J Clin End Metabol*, 81: 4129–4136.