

# A note on the morphology of the metopic suture in the human skull

Janusz Skrzat, Jerzy Walocha, Jarosław Zawiliński

Department of Anatomy, Collegium Medicum, Jagiellonian University, Kraków, Poland

[Received 28 May 2004; Revised 22 July 2004; Accepted 22 July 2004]

*The metopic suture of 24 adult skulls investigated showed recognisably varied morphological patterns. The metopic suture resembled wavy lines and was sometimes highly convoluted, especially in the superior part of the frontal bone. The mean suture length was computed as 123.1 mm (SD = 5.307) and the mean fractal dimension was 1.17 (SD = 0.076). Visual inspection of the morphological character of the metopic sutures revealed complex variation in their course between the nasion and the bregma. Comparison of the fractal dimensions indicated a two-fold increase in complexity between the anterior half of the suture terminating in the nasion (FD = 1.10) and the second half of the suture beginning in the bregma (FD = 1.21). The Mann-Whitney test confirmed the statistical significance of the differences in the fractal dimensions calculated. The variety and complexity of the interdigitations in the anterior and posterior part of the suture point to possible alterations to local strains, which occur during the growth of the braincase.*

**Key words:** cranial sutures, frontal suture, frontal bone

## INTRODUCTION

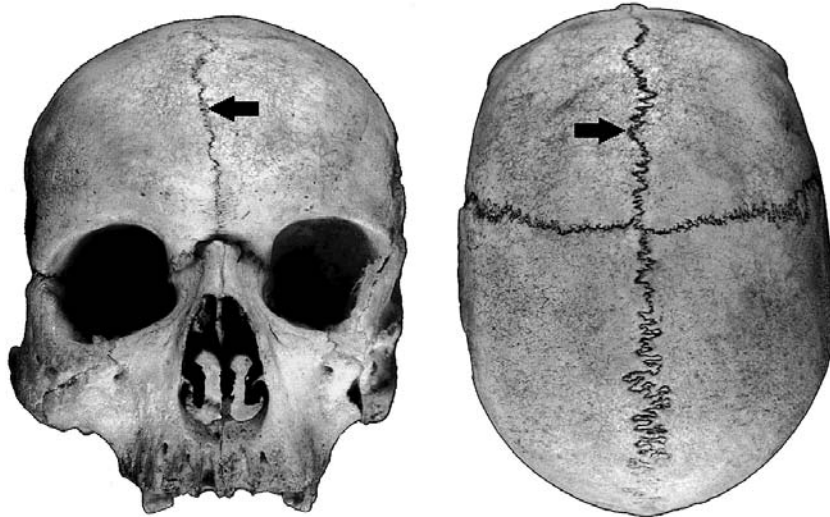The metopic suture runs between the frontal bones from the anterior aspect of the anterior fontanelle to the nasion. In the skulls of adults it is found anterior to the coronal suture along the superior mid-sagittal crest of the frontal bone. The metopic suture is considered to be an anterior extension of the sagittal suture (Fig. 1).

The fusion of the metopic suture commences at the nasion, proceeds superiorly in progressive fashion, and terminates at the anterior fontanelle [12]. This suture normally closes between the 1<sup>st</sup> and 2<sup>nd</sup> year of life and is usually completely fused by the 3<sup>rd</sup> year, but it can remain patent to the 7<sup>th</sup> year. In rare cases the metopic suture may persist throughout life and can be spotted even in old people [6, 9]. The persistence of the metopic suture has been reported in frequencies ranging from 1% to 12% of skulls. According to Berry and Berry [4], the appearance of this suture in adults varies from 0% to 7%, depend-

ing on ethnicity. In the Lebanese population complete and incomplete metopism is present in 0.82% and 0.93% of cases, respectively, leading to an overall incidence of 1.75%. The incidence of the metopic suture is slightly higher in males (1.84%) than in females (1.62%). Moreover, according to Baaten et al. [3], people who live in rural areas have a higher incidence of complete and incomplete metopism compared to people living in urban areas, with ratios of 4:1 and 4:2, respectively.

Ajmani et al. [2] carried out a study on 206 adult Nigerian skulls for the incidence of the metopic suture. He noted that metopism was present in 3.4% of cases, but a complete and incomplete metopic suture was observed in 34.97% of the skulls.

Metopism was studied in adult Brazilian skulls and it was found out that only 2.75% of the skulls showed this characteristic, although an incomplete metopic suture existed in 28.75% skulls [5]. Metopism was also observed in 2.66% of adult Indian skulls [1].



**Figure 1.** Location of the metopic suture (indicated by arrows) in the human skull.

Although it is rare to find this suture in adults, its presence is not considered pathological. However, premature fusion of the metopic suture results in trigonocephaly and it has been calculated that this craniosynostosis stands at 400 per 1,000,000 births in humans [14].

The aim of this study is to evaluate the detailed morphology of the metopic suture with the application of a fractal dimension, which quantitatively expresses suture complexity. Moreover, we wanted to determine whether or not the complexity of the metopic suture is constant within its course.

## MATERIAL AND METHODS

Analysis was performed on 24 adult dried skulls with persistent metopic suture. The skulls were derived from different populations and are stored in the Department of Anatomy and the Department of Anthropology of the Jagiellonian University.

We measured the length of the metopic suture and fractal dimension, which expresses sutural complexity. Moreover, visual inspection was performed to analyse the sutural pattern and to delineate its morphological character.

Measurements of the linear length of the metopic suture were taken as a direct distance from nasion to bregma along the arch of the frontal bone in the mid-sagittal line.

Complexity was expressed by the fractal dimension for the entire metopic suture and separately for the anterior (lower) and posterior (superior) parts, which are the halves of the suture. The ante-

rior half of the suture terminates in the nasion while the posterior half begins in the bregma.

The fractal dimension of the metopic sutures was calculated on their contours, which were traced with a thin marker on transparent tape, which adhered to the external surface of the skull along the suture analysed. The images obtained of cranial suture silhouettes were scanned with a flat bat scanner and skeletonised to a line of 1 pixel in width [8]. These prepared digital images of the metopic sutures were subjected to HarFa software, which measured fractal dimension using a box-counting algorithm [10].

In this procedure grids with alternated sizes of squares (boxes) are overlaid on the 1-pixel suture contour in the computer, and the number of squares touched by the suture is counted. By definition, there is an inverse relationship between the contour length calculated and the unit of measurement employed, which can be linearised by means of logarithmic transformation.

The fractal dimension is denoted by the formula:

$$D_F = \lim_{\varepsilon \rightarrow 0} \frac{\log N(\varepsilon)}{\log (1/\varepsilon)}$$

where  $D_F$  — fractal dimension,  $\varepsilon$  — edge length of the overlaid squares,  $N(\varepsilon)$  — count of squares covering the analysed image.

A fractal dimension is a non-integer number, which may vary from 1.0 to 2.0. The box-counting fractal dimension measures the ratio of increasing detail with increasing scale. Greater values of a fractal dimension indicate a more complex structure,


while lower values denote a decrease in structural complexity. By considering a cranial suture as a type of fractal, it makes it possible to reflect its subtle morphologic structure and level of complexity by means of the value of a fractal dimension [13].

The Mann-Whitney U test was computed to verify the null hypothesis, which states that the suture complexities expressed by the fractal dimensions of the anterior and posterior parts of the metopic suture are equal. A non-parametric test was applied because of unequal variances of the analysed data.

## RESULTS

Observations of the metopic sutures showed that they change in the appearance of the pattern and in complexity in their course. They usually resemble wavy lines and sometimes highly convoluted structures (Fig. 2). However, the half of the suture from the nasion extending superiorly and posteriorly (the anterior part of the suture) differs significantly from the second half of the suture beginning in the bregma (the posterior part). There was an extremely wide range in the length of the metopic sutures analysed and their complexity as denoted by the fractal dimension (Table 1). It was for this reason that we performed a separate analysis of the anterior and posterior parts of the metopic sutures.

Both visual inspection of the morphological character and comparison of the complexity of the anterior and posterior parts of the metopic sutures expressed by fractal dimension revealed significant differences. Essentially, the anterior parts of the metopic sutures analysed were less complicated than the posterior parts, which are more convoluted. The mean fractal dimensions computed indicate an approximately two-fold increase in complexity in the posterior part of the suture, when comparison is made of the decimal portions (1.10 and 1.21) which denote the level of sutural convolution (Table 2). The higher values of fractal dimension in the posterior part of the metopic suture suggest that this segment has more irregular and rough projections than the anterior segment, which usually resembles a convoluted line with minute denticulations.



**Figure 2.** Tracings of the simplest (A) and most complicated (B) metopic suture observed in the analysed skulls.

**Table 1.** Statistical data for the analysed metopic sutures expressed by fractal dimension

Variable	Mean value	Minimum value	Maximum value	Standard deviation
Suture length [mm]	123.1	112	135	5.307
Fractal dimension	1.17	1.05	1.34	0.076

**Table 2.** Comparison of sutural complexity in the anterior and posterior parts of the metopic sutures expressed by fractal dimension (FD)

Complexity	Mean value	Minimum value	Maximum value	Standard deviation	Variance
FD-anterior	1.10	1.02	1.20	0.046	0.002
FD-posterior	1.21	1.06	1.45	0.093	0.009

A possible interpretation for this difference is that the posterior part of the metopic suture might be subjected to greater functional stress in the braincase than the anterior part. The posterior suture segments probably have to resist stronger strains and thus respond by increasing interdigitation. The lower fractal dimension in the anterior part of the suture suggests a decrease in sutural complexity and therefore higher sutural stability. This presumably facilitates the establishment of a closer union between the two halves of the frontal bone towards the nasion.

The result of the computed Mann-Whitney test allowed the null hypothesis to be rejected, which assumed that suture complexity in the anterior and posterior segments of the metopic suture are equal. On the basis of statistically significant differences between the sum ranks of fractal dimensions (Table 3) and visual inspection of the sutures, we conclude that the sutural segments analysed are morphologically distinct.

## DISCUSSION

According to different investigators, the most commonly observed shape of the metopic suture is the linear type and only in isolated cases have other forms of the suture been found. These suture patterns have been described as radiating or having a wide side to side excursion [2]. For instance, the linear forms of the metopic sutures were observed as dominant in Brazilian skulls [5], whereas the Indian skulls presented various shapes in 35% of cases [1].

In our study we did not observe such diversity in the forms of the metopic suture and the major-

**Table 3.** Result of Mann-Whitney test

Rank sum FD anterior	Rank sum FD posterior	U	Z	p-level	Z	p-level	Valid N FD ant	Valid N FD post
374.50	801.50	74.50	-4.40*	0.000011*	-4.41*	0.000010*	24	24

\*Statistical significance

ity of the skulls had a convoluted pattern of the suture and not a linear. We found no information concerning the complexity of the metopic suture and its role in the adult skull. The relatively low frequency of the metopic suture in human populations naturally adds to the difficulty of studying the relationship between metopic suture morphology and craniofacial morphology in adults [4]. The findings of Jit and Banga [7] may indicate that the persistence of the metopic suture does not affect cranial shape. They established that the incidence of dolichocephalic heads was almost the same as that seen in the non-metopic population. Moreover there was no significant difference in the forehead breadths between the metopic and non-metopic subjects. The question as to whether the shape of metopic skulls differs from the shape of non-metopic skulls remains a difficult one to answer because of a lack of suitable data. Reliable results could be obtained only from a comparative analysis of craniofacial morphology performed on metopic and non-metopic skulls of adults derived from the same population. Otherwise, any morphological similarities and dissimilarities observed might result from intra-population variation and not a different pattern of craniofacial development [11]. We would expect an analysis of the relationship between metopic suture and cranial morphology to be helpful in explaining the role of this suture in the craniofacial complex of adults.

To sum up, the fractal concept gave a new insight into metopic suture morphology and the application of fractal geometry may help to reveal whether metopic suture influences cranial shape.

## REFERENCES

1. Agarwal SK, Malhotra VK, Tewari SP (1979) Incidence of the metopic suture in adult Indian crania. *Acta Anat (Basel)*, 105: 469–474.
2. Ajmani ML, Mittal RK, Jain SP (1983) Incidence of the metopic suture in adult Nigerian skulls. *J Anat*, 137: 177–183.
3. Baaten PJ, Haddad M, Abi-Nader K, Abi-Ghosn A, Al-Kutoubi A, Jurjus AR (2003) Incidence of metopism in the Lebanese population. *Clin Anat*, 6: 148–151.
4. Berry CA, Berry RJ (1967) Epigenetic variation in the human cranium. *J Anat*, 101: 361–379.
5. del Sol M, Binvignat O, Bolini PD, Prates JC (1989) Metopism in Brazilians. *Rev Paul Med*, 107: 105–107.
6. Ide Y, Inukai Y, Yoshida S, Sato I (2003) The internal structure of bony tissue of a human metopic suture by Soft X-ray. *Okajimas Folia Anat Jpn*, 79: 169–173.
7. Jit I, Banga N (1988) Metopism in north-west population of India. *J Anatomical Society of India*, 37: 45–60.
8. Long CA, Long JE (1992) Fractal dimensions of cranial sutures and waveforms. *Acta Anat*, 145: 201–206.
9. Nakatani T, Tanaka S, Mizukami S (1998) A metopic suture observed in a 91-year-old Japanese male. *Kaihogaku Zasshi*, 73: 265–267.
10. Nezdal M, Zmeskal O (2001) Harfa, Harmonic and Fractal Image Analyser (webpage: [www.fch.vutbr.cz/lectures/imagesci](http://www.fch.vutbr.cz/lectures/imagesci)).
11. Torgersen J (1951) The developmental genetics and evolutionary meaning of the metopic suture. *Am J Phys Anthropol*, 9: 193–210.
12. Weinzweig J, Kirschner RE, Farley A, Reiss P, Hunter J, Whitaker LA, Bartlett SP (2003) Metopic synostosis: Defining the temporal sequence of normal suture fusion and differentiating it from synostosis on the basis of computed tomography images. *Plast Reconstr Surg*, 112: 1211–1218.
13. Yu JC, Wright RL, Williamson MA, Braselton JP, Abell M (2003) A fractal analysis of human cranial sutures. *Cleft Palate Craniofac J*, 40: 409–415.
14. Zumpano PM, Carson BS, Marsh JL, Vanderkolk CA, Richtsmeier JT (1999) Three-dimensional morphological analysis of isolated metopic synostosis. *Anat Rec*, 256: 177–188.